

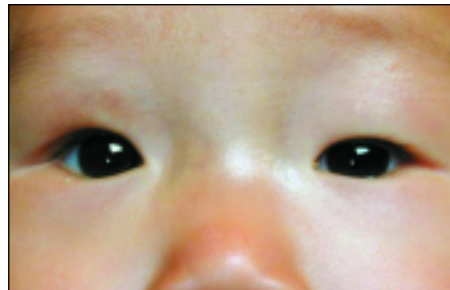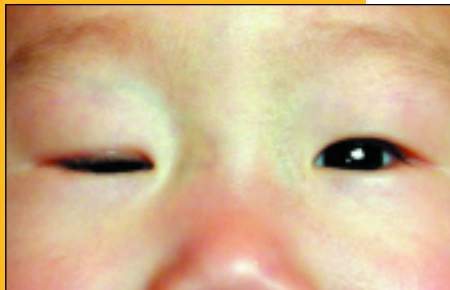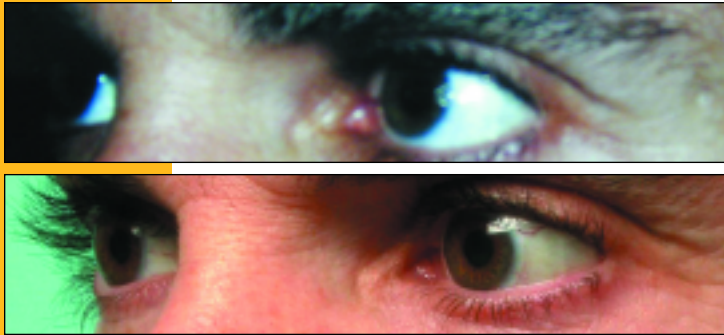
# Clinical Update

May 2004

Volume 13, Number 2

## Less is More: Minimal-incision Cosmetic and Reconstructive Trend

**Figure 1.** Patient before and after non-incisional midface lift, using layered vector cable technique combined with fat transfer by injection.



**Figure 2.** Improvement in ptosis is accomplished with minimal manipulation of the tissues and with no cutaneous scars.

“Nanosurgery” may sound—and still be—futuristic, but innovations for minimally invasive approaches have dramatically expanded the possibilities for both cosmetic and reconstructive ophthalmic procedures, says Robert Alan Goldberg, M.D., Professor in the UCLA Department of Ophthalmology, Chief of the Orbital and Ophthalmic Plastic Surgery Division, and Director of the Orbital Disease Center at the Jules Stein Eye Institute. “Non-incisional lifting methods, along with newer filler materials and nonablative lasers, are creating never-before-possible options for problems ranging from aging skin to childhood ptosis,” he says. “Surgery can still be pretty barbaric in some ways, and the trend is toward less invasive surgery.”

### Paradigm Shift

Traditional open surgeries unavoidably damage normal tissue while accessing

targeted tissue. Today’s less invasive approaches increase precision, thereby decreasing complications and allowing quicker recovery.

Dr. Goldberg says new technology and techniques have changed his attitude about surgical outcomes. “Years ago, I focused on whatever lasted longest; but that stance is outmoded. Today’s non-incisional facial lifting procedures, for instance, give patients nearly as good an improvement in appearance that lasts quite awhile—up to 60 percent as long as older open methods—but without the risks, pain, inconvenience and complications,” he notes. Compared to traditional operations, minimal-incision surgeries generally are simpler, spare tissue, are more comfortable for patients, can often be done in the office, and can be repeated whenever the effect diminishes. Even secondary non-incisional surgery is “much like a virgin surgery, with much less risk or damage to underlying tissues. Patients intuitively understand and respond to this new paradigm,” Dr. Goldberg says.

### Expanding Resources

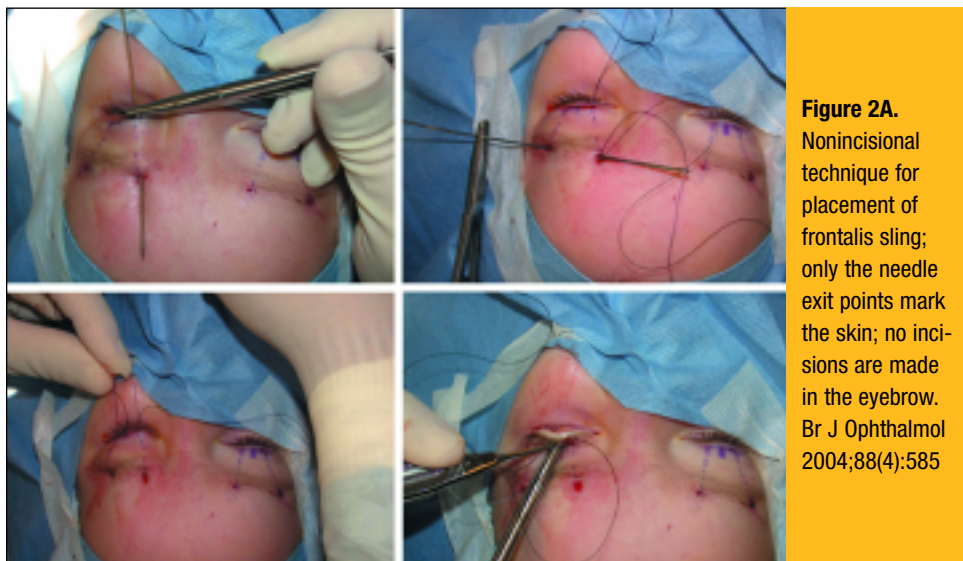New fillers and lasers augment non- or minimal-incision lifting approaches. The latest generation of fillers, Dr. Goldberg says, can truly address underlying loss of volume around facial ligaments—a critical and previously problematic feature of facial aging. Newer hyaluronic acid fillers such as Restylane® are more pliable than collagen, last as long as nine months, and have a near-zero rate of allergy or reaction. Advances with fat transfers also hold promise. “Fillers can

*(continued on page 2)*

Our web site address is  
<http://www.jsei.org>

Physician’s Direct  
Referral Line:

(310) 794-9770

**MINIMAL-INCISION COSMETIC AND RECONSTRUCTIVE TREND***(continued from page 1)*

**Figure 2A.** Nonincisional technique for placement of frontalis sling; only the needle exit points mark the skin; no incisions are made in the eyebrow. *Br J Ophthalmol* 2004;88(4):585

be combined very easily with minimal- or non-incisional lifts to accomplish a nice improvement and a natural look without major invasive surgery,” he notes.

Dr. Goldberg also combines minimal-incision lifting with skin rejuvenation, utilizing newer non-ablative lasers and radiofrequency devices that treat directly collagen and tissues in the deeper layers. In addition to reduced pain, faster healing, and less risk of scarring or pigment change, this method is less socially disruptive for the patient compared with epithelial removal using CO<sub>2</sub> laser or deep chemical peel. He says that though current nonablative resurfacing methods are not yet quite as powerful as those older methods, “patients happily accept a series of smaller procedures to get moderate improvement without the morbidity and downside of aggressive open treatment.”

### Less Growing Pain

The revision potential of noninvasive procedures especially benefits children with ptosis. “Children can show scars quite a bit and have more years to live with the results. When we can eliminate

scar tissue, it’s a much better operation,” Dr. Goldberg notes. He admits that in children the paradigm is complicated because of anesthesia risk if and when further surgery is needed, but notes that even traditional open surgery has a predictable rate of diminished effectiveness. Citing a legendary story in which Dr. Henry Baylis, the Division’s founding chief, announced a reoperation rate of 100 percent, Dr. Goldberg says, “His point was that most children with ptosis need some additional surgery anyway. Depending on how sophisticated the parents are and whether they want the maximum symmetrical result, we really do reoperate on a vast majority of children with ptosis. I tell parents it’s a staged, lifetime operation.”

Given this outlook, he says most minimal-incision procedures require reduced anesthesia, and anesthesia risk today is negligible. Furthermore, non-incisional techniques may even last a child until it’s possible for the next stage of correction to be performed under local anesthesia in the office, and revision is much easier to perform when there is less scarring and tissue damage.

### Repairs

Restorative surgery also fits the minimalist paradigm. For devastating facial palsy, for example, traditional face and eyebrow lifts offered only temporary improvement. Non- or minimal-incision procedures last nearly as long as traditional methods and may accomplish the same amount of lifting—even a more precise lift because the lifting cables and vectors can be customized beforehand. “When the inevitable revision is needed in a couple years, there is no scar tissue, so at revision we can reassess the patient’s current needs, perhaps design new vectors, and enhance previous improvement,” Dr. Goldberg says.

He has also had tremendous success with reoperation for patients who have had multiple cosmetic surgeries or complications. “Many of these patients have such scarring and adhesions, such functional and cosmetic problems, that additional dissection offers negligible and risky returns,” he notes. “The minimal-incision lift methods offer us a way to safely make some improvement for that patient without dissecting tissues that are already severely damaged.”

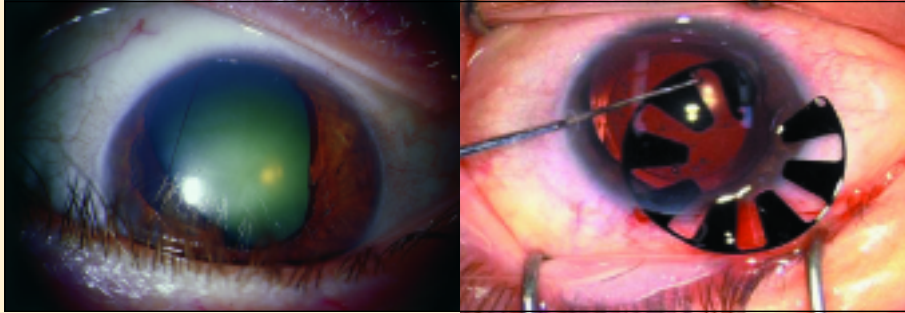
### Exciting Trend

Though Dr. Goldberg points out that there will still always be some role for classic open procedures, he says the minimalist trend makes sense philosophically to surgeons as well as patients. “It is very exciting for Institute surgeons to be contributing to this whole paradigm shift,” he says. “The evolution of technology and techniques empowers us to remedy so many more problems with so much less tissue trauma. The ability to be incredibly precise—that’s where surgery is going.”



## Aniridia Implants: Two Case Reports

The following two case reports were submitted by Kevin M. Miller, M.D., Professor of Clinical Ophthalmology, and Michael D. Olson, O.D., Ph.D., researcher in the Comprehensive Ophthalmology Division of the Jules Stein Eye Institute. They highlight a few of the surgical options available to patients with partial or complete congenital or acquired aniridia.



**Figure 1**

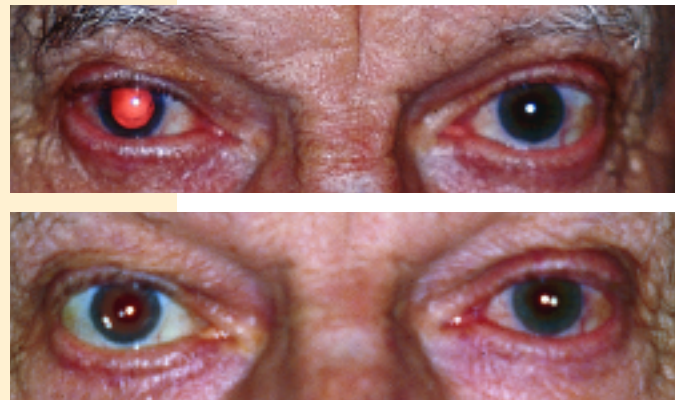
### Case 1

The first patient was 58 years old at the time of cataract surgery in his left eye. His ocular history was notable for bilateral moderate hyperopia and refractive amblyopia in the left eye. Both eyes had congenital partial aniridia with irregularly enlarged pupils. The pupil in the left eye was the larger of the two (Figure 1, left). He underwent uneventful cataract extraction with intraocular lens implantation in his right eye and achieved 20/15 visual acuity uncorrected. Because the greatest dimension of the left pupil was larger than any available lens implant, he was advised to have surgery with the implantation of two Morcher 50D aniridia ring segments (Figure 1, right). His postoperative uncorrected visual acuity of 20/70-1 matched his preoperative best-corrected visual potential before cataract development. He had a 4.5 mm artificial pupil after surgery and no complaints of glare or light sensitivity.

### Case 2

The second patient was 70 years old at the time of presentation. He underwent cataract surgery with posterior chamber intraocular lens implantation elsewhere that was initially uncomplicated. Two days after surgery he developed malignant glaucoma and extremely high intraocular pressure in the operated eye. He underwent an unsuccessful neodymium: YAG laser disruption of the anterior vitreous gel, followed immediately thereafter by a pars plana vitrectomy with intraocular lens removal. He developed an atonic pupil from the pressure spike and was surgically aphakic at the time of presentation here (Figure 2, top).

Because of the large pupil, he was advised to undergo secondary implantation of an Ophtec model 311 aniridia lens. Surgery was performed uneventfully, and the lens implant was suture fixated in the sulcus using two 10-0 prolene sutures. His visual acuity was correctable to 20/25- on the most recent office visit. He had no complaints of glare or photophobia. Although his artificial right pupil is slightly larger than his left pupil, he is pleased with the cosmetic result (Figure 2, bottom). The lens requires a 9.5 mm incision for implantation (Figure 3).



**Figure 2**

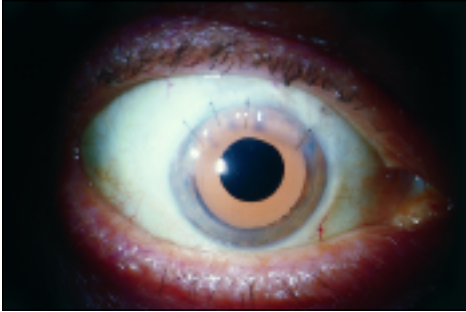
### Discussion

The Institute is participating in two clinical trials involving aniridia devices.

One study is an FDA-approved compassionate use clinical trial of various Morcher aniridia ring segments. Some are designed for implantation in the capsular bag while others are suitable for sulcus implantation. The Morcher devices being investigated at the Institute do not have attached lenses. If a lens is needed, a separate implant is placed.

The other study is an industry-sponsored FDA phase I/II clinical trial of the Ophtec model 311 aniridia lens implant. The device has a 4 mm pupil and is available in three colors: blue, green, and brown. It can be ordered in any power needed, and can even be


implanted without a lens, utilizing just the occluder portion. Two fixation holes are available on the haptics for suturing into the ciliary sulcus if necessary. The Ophtec model 311 is a good option for patients who need a lens and artificial iris at the same time.

**CASE REPORT: ANIRIDIA IMPLANTS** *(continued from page 3)***Figure 3**

The advantage of Morcher implants over the Ophtec aniridia lens is a much smaller incision size. The disadvantage of the Morcher

devices is that multiple implants often have to be implanted to achieve the final result.

**Referrals**

Patients who might benefit from these devices may be referred to Drs. Miller and Olson for evaluation. Additional information about these and other cataract clinical trials can be found on the Jules Stein Eye Institute website at <http://www.jsei.org> under Research, then Clinical Trials. 

**RECENT PUBLICATIONS**

Olson MD, Miller KM. Morcher iris diaphragm for treatment of light and glare sensitivity in partial or complete aniridia. *In Abstracts: Symposium on Cataract, IOL, and Refractive Surgery, 2004.*

Olson MD, Miller KM. Ophtec model 311 iris reconstruction lens for the treatment of visual disturbances resulting from partial or complete aniridia. *In Abstracts: Symposium on Cataract, IOL, and Refractive Surgery, 2004.*

**JSEI Continuing Education Programs & Grand Rounds Schedule****2004****Save the Date:**

The annual JSEI Research and Alumni Day, Post ARVO Seminar, and Postgraduate Seminar and Jules Stein Lecture are now combined. The newly organized event, called the Jules Stein Eye Institute Clinical and Research Seminar will be held at the Jules Stein Eye Institute on **May 21–22, 2004**. This year marks the first seminar, featuring the Thirty-fifth Jules Stein Lecture, the Second Thomas H. Pettit Lecture, and the Second Bradley R. Straatsma Lecture.

**Jules Stein Lecturer**

Robert N. Weinreb, MD, Shiley Eye Center at the University of California, San Diego

**Thomas H. Pettit Lecturer**

James P. Dunn, Jr., MD, Wilmer Eye Institute at The Johns Hopkins School of Medicine

**Bradley R. Straatsma Lecturer**

Paul S. Bernstein, MD, PhD, Moran Eye Center at the University of Utah

**For more information or to add your name to our distribution list, contact the Office of Academic Programs at (310) 825-4617, [continuingeducation@jsei.ucla.edu](mailto:continuingeducation@jsei.ucla.edu), or visit our website at <http://www.jsei.org>**

**Jules Stein Eye Institute UCLA**

100 Stein Plaza  
Box 957000  
Los Angeles, CA 90095-7000  
U.S.A.

First Class Mail  
U.S. Postage  
**PAID**  
UCLA