

# A Scheduled Protocol for the Treatment of Juvenile Recurrent Respiratory Papillomatosis With Intralesional Cidofovir

Dinesh K. Chhetri, MD; Nina L. Shapiro, MD

**Objective:** To assess the efficacy of treating juvenile recurrent respiratory papillomas with intralesional cidofovir using a scheduled treatment protocol.

**Design:** Prospective case series.

**Setting:** Tertiary care academic medical center.

**Patients:** Of 5 pediatric patients with recurrent respiratory papillomas, 2 had severe recurrent papillomatosis requiring long-term therapy of laser ablations every 2 weeks prior to cidofovir treatments. The 3 other patients were newly diagnosed or had milder disease.

**Intervention:** Intralesional cidofovir (1 mg/kg) was administered during each scheduled visit. The first 4 treatments were at 2-week intervals (week 0, 2, 4, and 6). Subsequent treatment intervals were each increased by 1 week (treatments took place at week 9, 13, 18, 24, etc). Concomitant laser ablation was used only for bulky lesions.

**Main Outcome Measures:** Papilloma stage and need for laser ablation at each scheduled visit.

**Results:** The mean follow-up time was 66 weeks. The mean (SD) papilloma stage decreased from 9.2 (5.5) at initial presentation to 3.4 (2.6) within 2 weeks of the first injection ( $P < .05$ ), and continued to decrease for the remaining of the follow-up period. Papilloma stage 0 was achieved in 4 of the 5 patients. The need for laser ablation of papillomas also decreased within 4 weeks of treatment initiation ( $P < .05$ ). At 9 weeks, no patient required laser therapy. One patient was removed from the protocol after 58 weeks.

**Conclusion:** An intralesional treatment protocol with cidofovir and increasing intervals between scheduled treatment was successful the long-term management of juvenile respiratory papillomatosis.

*Arch Otolaryngol Head Neck Surg.* 2003;129:1081-1085

**R**ESPIRATORY PAPILLOMATOSIS is the most common neoplasm of the larynx in children.<sup>1</sup> Although benign, it has a potential for significant morbidity and mortality. Involvement of the larynx and the vocal cords leads to hoarseness and, if left untreated, can result in death from airway obstruction. Microsuspension direct laryngoscopy and carbon dioxide laser ablation of papillomatous lesions is the current standard treatment for this disease. The disease is characterized by its recurrent nature and is therefore more commonly referred to as recurrent respiratory papillomatosis (RRP). In some children with aggressive RRP, treatment is required as frequently as every 2 weeks for an extended time. Laser ablation requires general anesthesia and complications of laser therapy include permanent injury to the lamina propria of the vocal fold, leading to vocal

fold scarring, laser-induced fire, and development of glottic webs. These considerations have driven the search for novel therapeutic modalities for the treatment of RRP.

The antiviral drug cidofovir (Gilead Sciences, Foster City, Calif) has recently been introduced into the armamentarium for treatment of RRP in several tertiary care centers.<sup>2-7</sup> Cidofovir is a cytosine nucleotide analogue that was approved for treatment of cytomegalovirus retinitis in patients infected with human immunodeficiency virus. After entry into a cell the drug undergoes phosphorylation and its active metabolite, cidofovir diphosphate, selectively inhibits cytomegalovirus DNA polymerases. Incorporation of cidofovir into the growing DNA chain results in selective inhibition of viral DNA synthesis. The long intracellular half-life of cidofovir and its metabolites allows for infrequent dosing.<sup>8</sup> Cidofovir has also been shown to be effective

From the Division of Head and Neck Surgery, UCLA School of Medicine, Los Angeles, Calif. The authors have no relevant financial interest in this article.

For each site, score as: 0 = none, 1 = surface lesion, 2 = raised lesion, 3 = bulky lesion	
<b>Larynx</b>	
Epiglottis:	Lingual surface _____ Laryngeal surface _____
Aryepiglottic folds:	Right _____ Left _____
False vocal folds:	Right _____ Left _____
True vocal folds:	Right _____ Left _____
Arytenoids:	Right _____ Left _____
Anterior commissure	_____
Posterior commissure	_____
Subglottis	_____
<b>Trachea</b>	
Upper one third	_____
Middle one third	_____
Lower one third	_____
Bronchi:	Right _____ Left _____
Tracheotomy stoma	_____
<b>Other</b>	
Nose	_____
Palate	_____
Pharynx	_____
Esophagus	_____
Lungs	_____
Other	_____
Total Score All Sites:	_____

Figure 1. Staging assessment for recurrent laryngeal papillomatosis.<sup>9</sup>

tive against a broad range of DNA viruses, including human papillomavirus (HPV).<sup>2,8</sup> Therefore, this drug has found an off-label use in the treatment of RRP.<sup>2-7</sup>

Pransky et al<sup>5</sup> first reported the successful use of cidofovir for juvenile RRP. They treated 5 children who had aggressive RRP with intralesional injections of cidofovir in conjunction with laser ablation and noted a dramatic reduction of papillomas, airway improvement, and an increase in operative intervals. Complete response was achieved in 3 patients. In an update with 5 more children treated in a similar fashion, they reported continued improvement of the airway and maintenance of the disease at mild levels in 9 of 10 patients.<sup>6</sup> For the patient, the greatest benefit from concomitant intralesional cidofovir injections was the increase in intervals between operative interventions. We found similar results in a case series of adults with RRP treated with intralesional cidofovir.<sup>7</sup>

While the clinical efficacy of intralesional cidofovir therapy for RRP has clearly been suggested by multiple reports, many questions remain unanswered. The optimal dose, the frequency and duration of treatment, and the proper candidates for intralesional cidofovir treatment have not been determined. In addition, the toxic long-term effect of this form of therapy is unknown. The major toxic effects of intravenous cidofovir include renal failure and neutropenia. In addition, a concern for the potential development of carcinoma has been raised, although no definite case of laryngeal carcinoma as a result of intralesional administration of cidofovir for RRP has been reported.

We developed a scheduled protocol for intralesional cidofovir treatment of RRP. The protocol starts with short treatment intervals, and the intervals are incrementally lengthened. Laser ablation is performed concomitantly as needed. The goal was complete eradication of disease or control of disease to a point where laser ablations would not be necessary. We first offered this treatment to a child

with poorly controlled papillomatosis who required laser ablation every 2 weeks. The dramatic control of his papillomas achieved from intralesional cidofovir therapy encouraged us to offer this protocol to other patients. In this article we report our experience with 5 children.

## METHODS

A scheduled treatment protocol was devised. The first 4 treatments were scheduled every 2 weeks (week 0, 2, 4, and 6). Each subsequent treatment took place at intervals increased by 1 week (at week 9, 13, 18, 24, etc). Informed consent was obtained from a parent or guardian at each treatment. The experimental nature of the drug, its indication and injection method, and the possibility of renal failure and neutropenia were specifically discussed. Blood was drawn prior to each injection and serum urea nitrogen and creatinine values measured by the clinical laboratory. If these renal parameters were within normal limits and not significantly changed from previous values, we proceeded with cidofovir therapy. A complete blood cell count was not routinely performed.

Microsuspension direct laryngoscopy and bronchoscopy were carried out under spontaneous ventilation general anesthesia to assess for papillomas. A 0° 4.0-mm endoscope attached to a video camera (Model 7210AA; Karl Storz, Culver City, Calif) was used for photodocumentation of the larynx. Four views of the upper airway were obtained: supraglottic, glottic, subglottic, and tracheal. Treatment of papillomas proceeded after photographs were obtained. If papillomatous lesions were absent or flat, a cidofovir injection alone was given. Raised or bulky lesions were first removed with cup forceps, then by laser ablation of the base, prior to cidofovir injection.

Cidofovir was diluted to a concentration of 5 mg/mL in an isotonic sodium chloride solution and administered using a 22-gauge 5½-inch spinal needle on a 5-mL syringe. The interarytenoid area was injected first, followed by the false vocal folds and the true vocal folds. These areas were injected regardless of the presence of papillomas. We did not routinely inject other areas of the larynx unless papillomas were present. A total dose of 1 mg/kg of cidofovir was given at each treatment. Injection into each true vocal fold was limited to 0.5 mL (2.5 mg) to prevent overdistention of the glottic epithelium and airway compromise. The glottic epithelium was invariably swollen after the subepithelial injection, and was gently but repeatedly pressed flat with laryngeal spatulas prior to releasing the laryngeal suspension.

The papilloma staging system described by Derkay et al<sup>9</sup> was used to score the anatomic severity of RRP at each treatment (Figure 1). This staging system divides the larynx and upper aerodigestive tract into anatomic subsites and assigns a score to papillomatous lesions in those areas based on whether papillomas are absent (score 0), flat (score 1), raised (score 2), or bulky (score 3). All subsite scores are added and a cumulative score is obtained for each patient at each treatment. The photodocumentation obtained at each treatment was used to score papillomas. The operative reports were also used for guidance. The main outcome measures were papilloma stage and use or nonuse of laser at each treatment. The level of significance was kept at  $P < .05$ . The *t* test and the Fisher exact test were respectively used to compare papilloma score and use of laser at each treatment.

## RESULTS

Five children, 3 boys and 2 girls between the ages of 22 months and 11 years at initial presentation, received intralesional treatment with cidofovir. In all patients, initial papilloma biopsy samples were positive for HPV 6/11

**Table 1. Papilloma Score and Laser Use at Each Scheduled Treatment Visit**

Treatment Week*	Patient No., Score (Laser Use)					Average Score
	1	2	3	4	5	
0	14 (Yes)	7	6 (Yes)	16 (Yes)	3 (Yes)	9.2
2	3 (Yes)	2	2	8 (Yes)	2	3.4
4	3	2	0	6 (Yes)	1	3.0
6	3	0	†	3 (Yes)	1	1.8
9	3	0	0	1	0	0.8
13	2	0	0	5	0	1.4
18	2	0	0	3	0	1.0
24	4	0	†	2	†	2.0
31	3	0	0	3 (Yes)	0	1.2
39	5	0	1	2 (Yes)		2.0
48	2 (Yes)	0	†	3 (Yes)		1.7
58	1	0	2			1.0
(63)	3					
69	2 (Yes)	0				
(74)	3 (Yes)					
81	3 (Yes)					
(86)	5 (Yes)					
94	0					
(100)	2					
108	2 (Yes)					
(115)	2 (Yes)					
123	3 (Yes)					

\*Weeks in parentheses are additional treatment weeks.

†Treatments were not given at these weeks because patients 3 and 5 were unavailable.

**Table 2. Renal Parameters at the Start and End of Study of Intralesional Treatment With Cidofovir (1 mg/kg) for RRP**

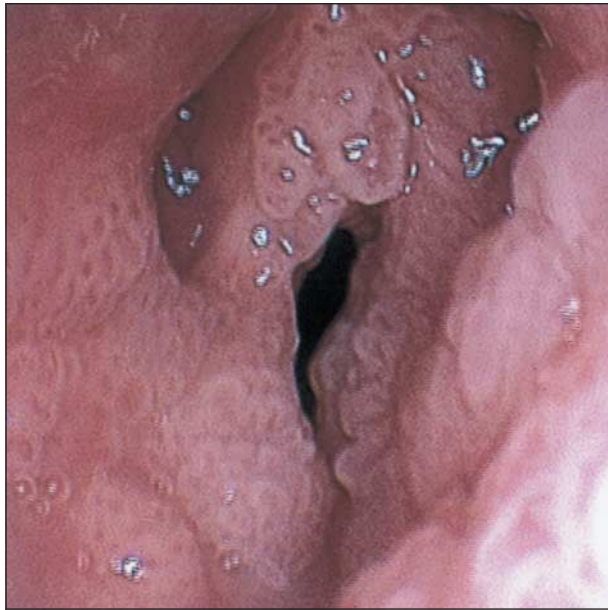
Patient No.	Treatment Weeks, No.	Injections, No.	SUN, mg/dL (mmol/L)		Creatinine, mg/dL (μmol/L)	
			Start	End	Start	End
5	31	8	11 (4)	10 (4)	0.4 (35)	0.3 (27)
4	48	11	9 (3)	8 (3)	0.5 (44)	0.5 (44)
3	58	9	5 (2)	5 (2)	0.4 (35)	0.4 (44)
2	69	13	8 (3)	10 (4)	0.3 (27)	0.3 (27)
1	123	22	9 (3)	9 (3)	0.4 (35)	0.4 (35)

Abbreviations: SUN, serum urea nitrogen; RRP, recurrent respiratory papillomas.

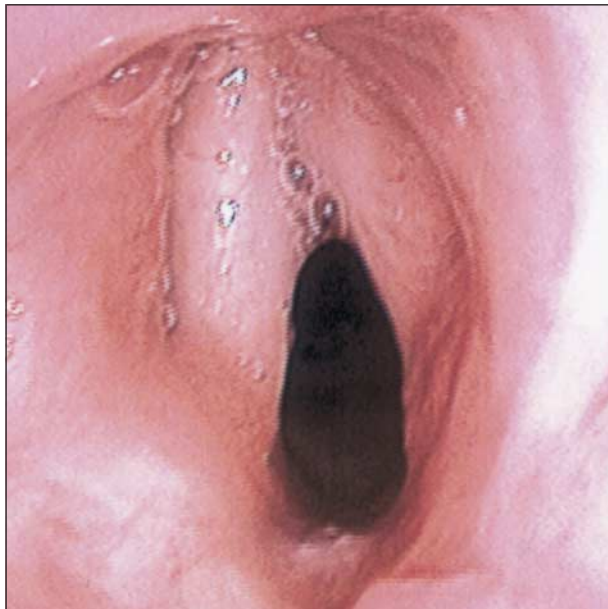but negative for HPV 16/18 and HPV 31/33/35. The average papilloma score, which was 9.2 at the first treatment, had decreased to 3.4 by the second treatment ( $P = .01$ ) and continued to decrease thereafter (**Table 1**). Laser use was halted after 1 treatment in 1 patient, 2 treatments in 2 patients, and 4 treatments in 1 patient. One patient (patient 2) was not treated with laser therapy in this study because her larynx was scarred from previous laser therapies. The number of treatments with cidofovir ranged between 8 and 22, and the average follow-up time was 66 weeks (range, 31-123 weeks). Renal function was stable throughout the treatment period for all children (**Table 2**). Four of the 5 children achieved complete resolution of papillomas (severity score, 0) during the course of their treatment. At the latest follow-up visit, 2 had no disease but 3 had mild residual disease (Table 1). The clinical course is described in detail for the first patient and a brief summary is provided for the remaining patients.

A 4-year-old boy (patient 1) presented with respiratory distress and a large pedunculated papillomatous

lesion. After the obstructing lesion was removed urgently in the operating room, diffuse involvement of the larynx was seen (score 10). The disease was managed with repeated laser ablations. Despite 13 laser ablations in the following 34 weeks, his papilloma score remained between 10 and 20 (**Figure 2**). Intralesional cidofovir therapy was offered to him because of the severity of his papillomatosis. At the first scheduled treatment papillomas involved the true and false vocal cords bilaterally, plus the anterior commissure, left arytenoid, left posterior subglottis, and laryngeal surface of the epiglottis (score 14). The response to combined cidofovir and laser treatment was dramatic and in stark contrast to the previous course of the disease. By the third scheduled treatment the papilloma score was 3 and concomitant laser therapy was not needed. During the course of the scheduled treatments the child continued to have minimal residual papillomatosis but laser ablation was not performed until the scheduled week 48 treatment; then, it was used to remove a raised lesion at the right true vocal fold. Because



**Figure 2.** Patient 1. Typical endoscopic laryngeal photograph during treatment with laser therapy alone.



**Figure 3.** Endoscopic laryngeal photograph of patient 1 at the latest follow-up treatment, 123 weeks after initiation of scheduled treatments with cidofovir.

he continued to have persistent residual papillomas, and the intervals between treatments were becoming long, he was taken off the scheduled protocol at 58 weeks and placed on a 5- to 8-week treatment schedule to avoid disease resurgence. After receiving combined laser and cidofovir treatments at weeks 69, 74, 81, and 86, his larynx was found clear of papillomas for the first time at week 94. At his latest treatment (week 123) his papilloma score was 3, with flat lesions at the posterior true vocal folds bilaterally and in the anterior commissure (**Figure 3**). Although we were not able to maintain him on the scheduled protocol, his quality of life has im-

proved markedly because the papillomatosis is controlled.

The clinical course of the other 4 patients is summarized in Table 1. A 4-year-old girl (patient 2) was diagnosed with laryngeal papillomas at the age of 7 months and treated with laser ablations at an outside facility. Her larynx was scarred and a thick posterior glottic web was present. Given the significant scarring of the larynx we decided to manage her disease with cidofovir injections alone. She remained disease free at the latest scheduled treatment, at 69 weeks. A 22-month-old boy recently diagnosed with laryngeal papillomas (patient 3) responded dramatically well to treatment. At his latest scheduled treatment, at 58 weeks, he had small areas of flat papillomas at the posterior false vocal folds bilaterally (score 2). An 11-year-old boy with severe papillomatosis (patient 4) had received frequent laser ablations for RRP at an outside facility. At the fifth scheduled treatment (week 9) his papillomas were limited to the anterior commissure (score 1) and laser use was halted. Mild recurrent disease, limited to the posterior true vocal folds and anterior commissure, was seen at subsequent scheduled treatment visits. At his latest scheduled treatment, at 48 weeks, he continued to have flat lesions at those sites (score 3). And patient 5, a 5-year-old girl, presented with a 4-month history of hoarseness and cough. Examination in the operating room revealed a large bulky papilloma emanating from the right false vocal cord (score 3) and obliterating the airway when collapsed. The lesion was urgently removed with cup forceps and the base ablated with the laser. Cidofovir treatment was then given. Her larynx remained clear of papillomas at her latest scheduled treatment, at 31 weeks (score 0).

#### COMMENT

Previous clinical reports on the efficacy of intralesional injections of cidofovir for papillomatosis indicated recurrence of disease when treatment was stopped,<sup>5,6</sup> and even the possibility of disease recurrence with continued treatment. The treatment dose in those studies was approximately 1 mg/kg of cidofovir and the treatment interval was 2 to 3 weeks. While better control of RRP with the addition of cidofovir was demonstrated, how long the duration of treatment and how frequent the individual treatments should be remained unclear. Given the potential toxic effects of cidofovir, it is important for clinicians to have further guidelines on the use of this drug. Therefore, we designed the scheduled protocol for treatment of RRP with increasing treatment intervals. The dose was kept at 1 mg/kg but after 4 treatments at 2-week intervals, each subsequent treatment interval was increased by 1 week. An ideal result under this protocol is a well-managed and well-controlled disease, without need for unscheduled treatments or laser use. The patient would be managed indefinitely under this protocol, until the treatment intervals became so infrequent that a decision to terminate treatment could be made.

Our results demonstrate that intralesional treatments with cidofovir, combined with laser ablations as needed for bulky lesions, control juvenile RRP at levels of mild severity. Two of our patients (1 and 4) had se-

vere, poorly controlled RRP despite laser ablations almost every 2 weeks. Their disease became controlled only after addition of intralesional cidofovir treatments. One patient (1) was removed from the scheduled protocol after 58 weeks and the other (4) continues on the scheduled protocol with excellent control of his papillomas. The other 3 patients have had excellent responses, with no need for laser ablations except at the onset of treatment. At the latest follow-up, 2 of them had no evidence of papillomas and the third one has recently developed mild recurrence after a prolonged disease-free period. The last 3 patients had excellent response, but milder disease at the initiation of cidofovir therapy.

The better control of laryngeal papillomas achieved with the addition of intralesional injections of cidofovir to laser treatment resulted in decreased patient morbidity. We encountered no need for intubations before or after treatment, and there were no postoperative admissions, no readmissions, no unscheduled visits, and no administration of steroids. All 5 patients have a normal voice and all participate fully in their daily activities. Regarding the lesions of the 3 patients with persistent or recurrent disease, they are located at the anterior commissure and the posterior true vocal cords in 2 (1 and 4), in close proximity to the arytenoid cartilage. In the third patient (3), lesions are present at the posterior false vocal cords adjacent to the arytenoids. Persistence of disease in these locations may be related to inadequate drug delivery. We limit the amount of volume injected into the vocal folds to prevent overdistention of the lamina propria. In addition, the mucosal layer in the region of the anterior wall of the arytenoids and the anterior commissure abuts cartilage and is very thin, which limits the volume of medication that can be injected in these areas. Finally, we limit laser use to the anterior commissure and, therefore, rely solely on cidofovir to eradicate disease from this area. In our case series of adult patients, we also noted the persistence of papillomas at the anterior commissure despite cidofovir therapy.<sup>7</sup>

The role of cidofovir in the treatment of RRP remains to be fully established. We currently use it as adjunctive therapy to laser treatment for severe papillomatosis. Prospective randomized dose determination studies are needed to assess the true efficacy of this modality of treatment.

## CONCLUSIONS

A scheduled protocol for the treatment of juvenile RRP with cidofovir, with increasing intervals between treatments, is effective in controlling this disease. Children with milder disease appear to respond better to this therapy. Further prospective studies are needed to establish the role of cidofovir in the treatment of RRP.

Submitted for publication March 21, 2002; accepted January 24, 2003.

This study was presented at the annual meeting of the American Society of Pediatric Otolaryngology (ASPO); May 13, 2002; Boca Raton, Fla.

Corresponding author: Dinesh K. Chhetri, MD, 62-132 CHS, Head and Neck Surgery, Mail Code 162418, UCLA School of Medicine, Los Angeles, CA 90095 (e-mail: dchhetri@ucla.edu).

Reprints: Nina L. Shapiro, MD, 62-158A CHS, Head and Neck Surgery, Mail Code 162418, UCLA School of Medicine, Los Angeles, CA 90095.

## REFERENCES

1. Derkay CS. Recurrent respiratory papillomatosis. *Laryngoscope*. 2001;111:57-69.
2. Van Cutsem E, Snoeck R, Van Ranst M, et al. Successful treatment of a squamous papilloma of the hypopharynx-esophagus by local injections of (S)-1-(3-hydroxy-2-phosphonylmethoxypropyl)cytosine. *J Med Virol*. 1995;45:230-235.
3. Snoeck R, Wellens W, Desloovere C, et al. Treatment of severe laryngeal papillomatosis with intralesional injections of cidofovir [(S)-1-(3-hydroxy-2-phosphonylmethoxypropyl)cytosine]. *J Med Virol*. 1998;54:219-225.
4. Wilson WR, Hashemiyoan R, Hawrych A. Intralesional cidofovir for recurrent laryngeal papillomas: preliminary report. *Ear Nose Throat J*. 2000;79:236-238.
5. Pransky SM, Magit AE, Kearns DB, Kang DR, Duncan NO. Intralesional cidofovir for recurrent respiratory papillomatosis in children. *Arch Otolaryngol Head Neck Surg*. 1999;125:1143-1148.
6. Pransky SM, Brewster DF, Magit AE, Kearns DB. Clinical update on 10 children treated with intralesional cidofovir injections for severe recurrent respiratory papillomatosis. *Arch Otolaryngol Head Neck Surg*. 2000;126:1239-1243.
7. Chhetri DK, Blumin JH, Shapiro NL, Berke GS. Office-based treatment of laryngeal papillomatosis with percutaneous injection of cidofovir. *Otolaryngol Head Neck Surg*. 2002;126:642-648.
8. Safrin S, Cherrington J, Jaffe HS. Clinical uses of cidofovir. *Rev Med Virol*. 1997;7:145-156.
9. Derkay CS, Malis DJ, Zalzal G, Wiatrak BJ, Kashima HK, Coltrera MD. A staging system for assessing severity of disease and response to therapy in recurrent respiratory papillomatosis. *Laryngoscope*. 1998;108:935-937.