

# Physicians' Update

UCLA Healthcare

## Inside:

- ❖ **New Treatments for Venous Diseases Improve Outcomes and Reduce Scarring**
- ❖ **Aneurysms Repaired with Less Invasive Procedures**

Plus  
**Publications  
for Physicians**

a tear-off guide to the most complete, up-to-date clinical and research information from UCLA Healthcare

## Integrated Treatments Help Salvage Endangered Limbs

In the past 30 years, limb salvage and wound care has changed so dramatically that even the most advanced foot and leg ulcerations rarely lead to amputation. The blood circulation so critical to saving limbs and healing wounds can be improved with a variety of techniques including balloon angioplasty, stents and bypasses, which allow skin grafts and a host of new wound care products to heal the newly perfused wound.

Still, the earlier treatment begins, the better the outcome. "It's critical for doctors on the front line to either assess their patients' circulation and wound healing capabilities or refer them to a specialized center like UCLA's where we 'bring the team to the patient' to diagnose and treat circulatory issues," notes Peter Lawrence, M.D., director of UCLA's Gonda (Goldschmied) Vascular Center.

Patients with vascular conditions requiring assessment may have

symptoms ranging from leg pain when walking or forefoot pain at rest to sores or ulcers that won't heal. Gangrene is rarely the first sign of poor circulation.

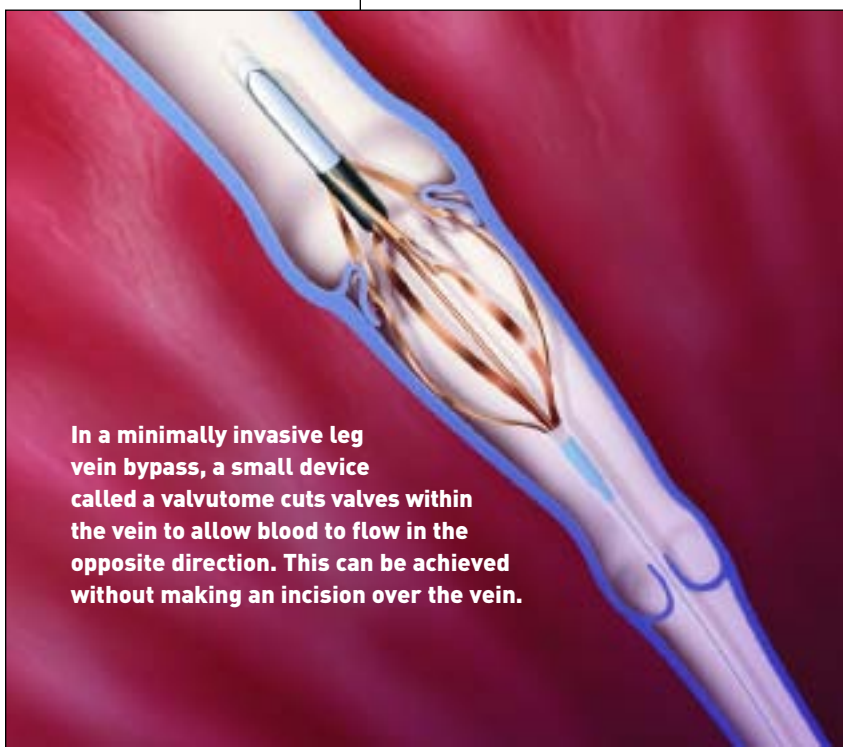
### Diagnostic Tools

A variety of diagnostic tools can help precisely pinpoint narrowing or blockage in blood vessels that may be causing leg pain or hindering wound healing:

- ❖ Physiologic tests, such as sophisticated blood pressure devices designed for the legs, can assess blood flow
- ❖ Specialized ultrasound can determine the location of the blockage
- ❖ Magnetic resonance imaging (MRI) can determine wound depth
- ❖ Magnetic resonance angiography (MRA) creates a picture of the arteries and the site of the blockage
- ❖ Contrast computed tomography (CTA) can determine whether plaque exists in the wall of a blood vessel or aneurysm

"In many ways, our diagnostic abilities have improved 99 percent with all these tools, but there is no substitute for a careful physical examination. Vascular disease is one of the few remaining areas in medicine where, after a careful physical exam and blood flow studies, the patient can leave their first office visit with an accurate determination of the problem and all of the potential treatments," Dr. Lawrence notes, "However, we know that these imaging studies in many people without symptoms can reveal blockages that are not associated with the problem the patient is having and therefore do not need to be treated. So the careful exam is critical to determining whether

CONTINUED ON PAGE 2



In a minimally invasive leg vein bypass, a small device called a valvotome cuts valves within the vein to allow blood to flow in the opposite direction. This can be achieved without making an incision over the vein.

CONTINUED FROM PAGE 1 treatment of the blood vessels is necessary.”

Developing a treatment plan for these patients requires input from a variety of specialists: vascular surgeons, podiatrists, interventional radiologists, plastic surgeons, and wound care and risk factor specialists. Dr. Lawrence is convinced that this collaboration improves a patient’s chance of saving his or her limb.

## Podiatry Techniques

Experts predict that 20 percent of all diabetic patients will develop a serious foot infection, some requiring lower extremity amputation, notes Robert K. Lee, D.P.M., UCLA podiatrist.

A diabetic foot wound may form due to poor biomechanics, poor blood flow, poor sensation, or more commonly, from a combination of these factors. When a diabetic patient develops neuropathy and gradually loses sensation in the foot, irritated areas can progress to wounds, ulceration and serious infection without the patient feeling any pain or discomfort, Dr. Lee explains. Often times, chronic diabetic foot wounds are healed by simple modification to shoes, insoles, or with special shoes or casts, in conjunction with good local wound care.

In some cases, surgical intervention is required to address biomechanical abnormalities and/or deformity in the foot. One method frequently used in diabetics is lengthening the Achilles’ tendon. “Chronically elevated sugar levels can decrease collagen elasticity. As a result, the Achilles’ tendon contracts, causing the person to walk more on the balls of the feet,” says Dr. Lee. “By lengthening the Achilles’ tendon through a minimally invasive percutaneous technique, we can better distribute the weight-bearing forces across the foot.”

Fixed bony deformities such as bunions, hammertoes, or Charcot osteoarthropathy often induce the formation of pressure wounds and require surgical reconstruction. New techniques such as external fixation, bone stimulators, and orthobiologics (e.g. autologous platelet concentrates)

---

“Vascular disease is one of the few remaining areas in medicine where, after a careful physical exam and blood flow studies, the patient can leave the first office visit with an accurate determination of the problem and all of the potential treatments.”

—DR. PETER LAWRENCE, *director, UCLA’s Gonda (Goldschmied) Vascular Center*

---

have helped to significantly advance foot reconstruction and limb salvage in diabetics. Even in the presence of osteomyelitis, more and more limbs are being preserved with selective bone resections, partial foot amputations, vacuum assisted closure devices, and aggressive antibiotic therapy. Coupled with appropriate custom braces/ankle-foot-orthoses, partial foot prostheses, and diabetic shoes, many of these patients return to fairly normal levels of ambulation.

## Endovascular Therapy

Endovascular techniques work from inside the blood vessel to improve circulation, explains Thomas McNamara, M.D., UCLA interventional radiologist. In the past, a patient with an occluded artery in the lower abdomen affecting wound healing in one leg would receive a surgical bypass. Today, modified balloons and stents provide tools to open up vessels with minimal trauma. Some tools being used and studied at UCLA include:

- ❖ Cutting balloons use blades the thickness of a hair to dilate vessels
- ❖ Atherectomy cuts and removes plaque from blood vessels
- ❖ Cryoballoons use liquid nitrogen to dilate vessels
- ❖ Drug-eluting stents impede re-narrowing
- ❖ Cold laser excimers open blocked blood vessels
- ❖ Stent grafts incorporate a stent into a bypass graft

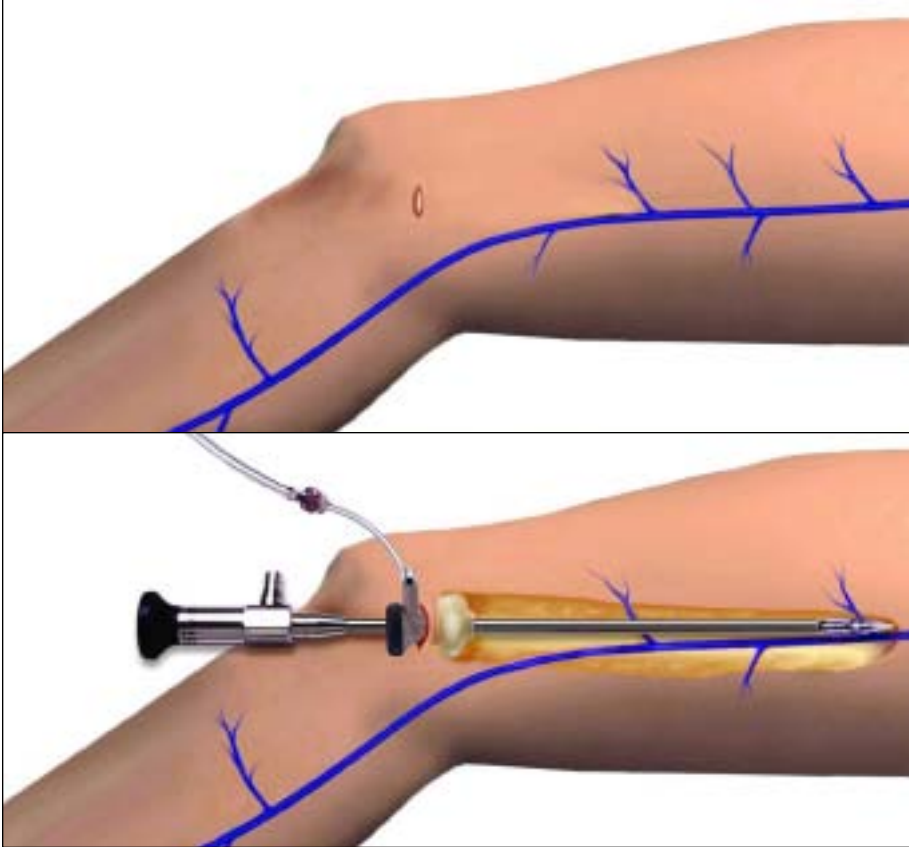
Dr. McNamara says, “Amputation is not an answer; it’s an area of ignorance. We can improve blood flow in 85 to 90 percent of patients and, if necessary, repeat treatment to give an ulcer time to heal.”

## Vascular Surgery

“We also have the expertise to bypass veins to or near the foot to help heal wounds,” Dr. Lawrence says. “We can now make a one-inch incision below the knee and harvest the vein from the groin to the ankle. And that can be done in less than half an hour, significantly improving post-operative recovery. We can also bypass to small arteries in the foot, which are the size of a pencil lead, using a special microscope.” These techniques are the same as are used for coronary artery bypass grafts.

One out of five patients who have bypass or a balloon angiogram require a revision of his or her graft. Therefore, surgeons tunnel grafts right below the skin so they are easily accessible, Dr. Lawrence says. Unlike the heart, which is hard to monitor for re-narrowing because it is constantly beating, vascular disease elsewhere in the body can be closely watched using ultrasound so that when grafts begin to narrow, interventions can be effectively employed.

In addition to ultrasound surveillance, patients need to control risk factors. “In most patients, peripheral arterial occlusive disease is a manifestation of atherosclerosis. If disease exists in the leg, chances are the carotid and coronary arteries are also affected,” says Deborah Kass, the nurse practitioner who runs the risk modification program for the UCLA Gonda (Goldschmied) Vascular Center. She works with patients on their diet and exercise and, when indicated, starts medications, such as statins, beta blockers and blood thinners, to help control peripheral arterial occlusive disease.



## Wound Care

Once circulation is improved, wound care begins in earnest. “If you put patients in a wheelchair after a bypass for three months to heal a wound, the odds of them walking are much lower than if you can get the wound healed and get them in a special orthotic shoe so they can walk right away. If we can cut down the length of time it takes to heal by at least 50 percent, patients will be back to normal so much quicker and their survival will be higher,” Dr. Lawrence explains.

Patients with a wound that fails to show improvement after three to four weeks of treatment, or that is showing any signs of gangrene, should see a wound specialist. Debbie Caswell, the nurse practitioner who runs the Wound Center at UCLA’s Gonda (Goldschmied) Vascular Center, considers all causes that may be impeding wound healing—from poor circulation and venous insufficiency to medications that a patient may be taking.

“The wound heals from the inside out. We work on nutrition (the body needs protein to heal), and I put them on vitamin supplements, check nutritional status and use short-term anabolic steroids when necessary to beef up the ability to heal,” she says.

**An endovascular vein harvest avoids a long incision in the leg. A rigid scope enters through a one-inch incision to pass through and cut all branches of the vein being harvested.**

In addition, she discusses lifestyle and family support with each patient.

Patients with chronic wounds—especially those who have had several courses of antibiotics—often harbor resistant organisms that impede wound healing. Oral antibiotics and antimicrobial topical solutions (including the currently popular silver) can help eliminate the bioburden, Caswell observes.

“When wounds heal, even at their strongest, the scar is still only 80 percent as strong as normal tissue. Therefore, a lot of the focus in our clinic is on taking care of the wound and preventing recurrence,” Caswell notes. “Venous ulcers—most often around the ankles—are particularly tenacious. From day one we educate these patients about how to prevent recurrence and the surgeons do their part to repair faulty circulation that is causing the wound.”

A proliferation of new wound-care products exists, and knowing the pros and cons of each product becomes more critical, both for healing benefits and the expense of some of these

treatments. Research currently focuses on biophysical and cellular aspects of wound healing. “We’ve found that chronic wounds are very different than acute wounds. The fluid in a chronic wound contains very few growth factors but many inflammatory cytokines. There are now dressings that control those inflammatory factors, which actually block the effects on the growth factors. There are also biologic dressings that act as skin substitutes,” Caswell says.

Hyperbaric oxygen provides another option for wound healing for appropriate patients who can use a boost in oxygen to aid in healing, to improve skin grafts, and to treat chronic osteomyelitis.

## Surgical Wound Care

The first line of therapy for limb salvage is wound care and then we add to that simpler surgeries such as skin grafts, VAC therapy and flaps,” says James Watson, M.D., UCLA plastic surgeon. “Vacuum assisted closure (VAC) therapy provides negative pressure wound care with a sponge, plastic occlusive covering, and suction tubing that connects to a low-pressure suction system.” VAC therapy is used to immobilize skin grafts, and is a procedure patients can do themselves at home.

In some cases, flap procedures transfer tissue from another part of the body to the wound to cover exposed bone, close blood vessels, and help heal large wounds.

“Success rates for flaps at UCLA run about 96 percent, compared to 70 percent around the country. Our success is due to our team approach, patient selection, working with vascular surgeons, and getting patients in optimal condition before attempting surgery,” says Dr. Watson, who notes that he is starting to use arterial grafts from the forearm and armpit for small bypass grafts in the foot. ❖

## Recommended Reading

Lawrence PF, Caswell DR. The Wound Care Center and Limb Salvage. *Vascular and Endovascular Surgery*. Moore W. Saunders, 2005.

# New Treatments for Venous Diseases Improve Outcomes and Reduce Scarring

**F**rom sclerotherapy injection to radiofrequency ablation and stab phlebectomy, minimally invasive procedures are dramatically changing the management of venous disease. “The days of having large scars on the leg are gone,” says Peter Lawrence, M.D., director of UCLA’s Gonda (Goldschmied) Vascular Center. “We now have many different ways of treating venous disease in an outpatient setting that don’t require the large incisions we previously made. In addition to less scarring, this has led to less pain, shorter recovery times and better cosmetic results.”

Venous disease tends to fall into three categories. Spider veins—the unsightly clusters of red, blue or purple veins that most commonly appear on the thighs, ankles and feet—occur predominantly in women and are usually hormonally based. Varicose veins, in which inadequately functioning valves in the veins cause blood to pool and the veins to enlarge, often occur in women after pregnancy and in men from activities that exact high pressure in the veins, including bouts with constipation and certain athletic maneuvers; in other cases, the cause is congenital or unknown. Unlike

spider veins, which tend to be no more than a cosmetic problem, varicose veins are often associated with symptoms that include heaviness and fatigue in the leg after prolonged standing. In more severe cases, venous insufficiency—in which the veins fail to adequately return blood from the lower limbs back to the heart—can lead to venous ulcers, which require immediate attention.

“The standard treatment for a lot of venous disease was always removal of the vein through stripping, which usually meant an overnight hospital stay followed by a week of disability,” says Hugh Gelabert, M.D., vascular surgeon at the Gonda (Goldschmied) Vascular Center “Now we’re doing outpatient procedures in which the patient has two to three days of tenderness rather than five to six days, and can go back to work much sooner.”

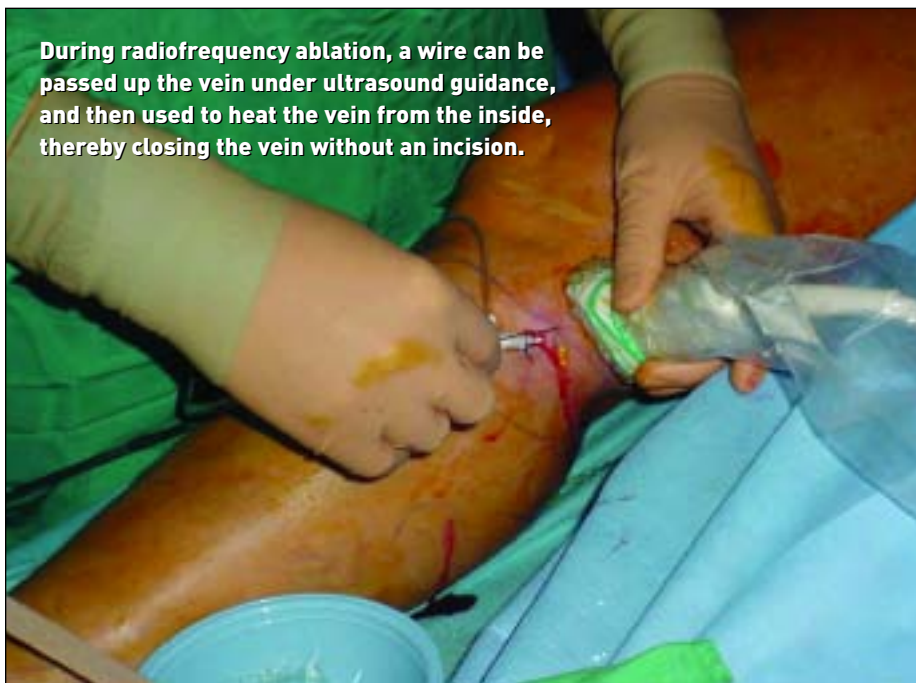
The majority of the population, especially women, will develop some degree of venous insufficiency, notes Deborah Caswell, a nurse practitioner at the center. “Many people come to us because they’ve seen others who have been amputated and they have a sore on their leg or these big, ugly veins and they’re afraid that they are headed the same way,” she says. Caswell assures these patients that they need not be

fearful, and provides education to ensure that the complications of end-stage venous insufficiency will be avoided.

## First-line Therapies

**C**onservative management of mild venous insufficiency starts with having the patient avoid excessive standing and wearing elastic support hose—graded compression stockings designed to keep the blood from pooling at the bottom of the leg—when standing is required. For patients whose jobs require constant standing, Caswell counsels toe-raising exercises that help pump blood through the calf muscle. “Venous insufficiency is a disease of gravity, meaning that if your legs are in the dependent position the fluid tends to collect at the bottom and increases the venous pressure, causing aching, swelling and heaviness that is common in these patients,” she explains. “Since very few people can keep their legs elevated 24 hours a day, we rely on some type of compression stockings.” Horse chestnut seed extract is the only medication that has been shown, in small studies, to be equal to compression stockings in controlling the swelling and aching in patients with venous insufficiency, Caswell adds. She also urges patients to exercise and lose weight when appropriate.

If discomfort persists after conservative management, or if patients are concerned about cosmetic appearance, one of several minimally invasive procedures may be recommended. Sclerotherapy or laser treatment are often used to improve appearance. Sclerotherapy involves injection of a solution into the vessel to irritate the inside lining of the veins. A magnifying glass facilitates injections into the smallest veins with solutions least likely to cause significant pigmentation or risk of ulceration. Compression pads push the vein walls together and the compression stockings are worn as the veins heal shut. Says Caswell: “It’s important for me to be very



**During radiofrequency ablation, a wire can be passed up the vein under ultrasound guidance, and then used to heat the vein from the inside, thereby closing the vein without an incision.**

---

“Treatment for a lot of venous disease usually meant an overnight hospital stay followed by a week of disability. Now we’re doing outpatient procedures in which the patient has two to three days of tenderness, and can go back to work much sooner.”

—DR. HUGH GELABERT, *UCLA vascular surgeon*

---

familiar with the anatomy of the venous system. Frequently, patients will come to us after having had numerous sessions of sclerotherapy, and the spider veins keep coming back. We might take one look at them and realize they have an incompetent perforating vein that, if successfully treated with a small procedure by a surgeon, will prevent the spider veins from returning.”

### Radiofrequency Ablation

**R**adiofrequency ablation effectively shuts down the vein by delivering heat to its inner wall through a catheter, using ultrasound guidance. For patients with varicose veins and those with venous ulcers—in which veins deeper in the leg are affected—endovenous therapy using radiofrequency ablation enables vascular surgeons to close off the veins without making incisions. “This is a big change in our practice in the last few years,” says David Rigberg, M.D., a vascular surgeon at the Gonda center. “The classic stripping of the greater saphenous vein—in which we would make a small incision in the groin and just below the knee or at the ankle and run a plastic tube through the vein from one end out the other before essentially ripping the vein out—has been replaced. Instead of a procedure that caused a lot of swelling and bruising, and potentially a great deal of discomfort, we now have one in which we destroy the vein in its original place, using this relatively quick outpatient procedure with minimal postoperative discomfort. It has revolutionized the treatment of venous disease.”

For patients with medium-sized surface varicose veins, vascular surgeons are performing stab phlebectomies, in which the veins are removed through incisions that are so small—

approximately one millimeter—they don’t require closing. “These provide a much better cosmetic result, because you can’t see the access site where we went in to remove the vein,” says Dr. Lawrence.

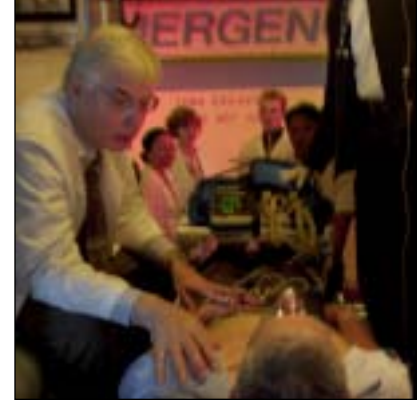The worst cases of venous insufficiency can lead to ulceration of the skin or more serious problems of the deep venous system. “Chronic venous insufficiency can be very disabling if the patient gets a large ulcer that won’t heal,” says Dr. Gelabert. Venous ulcers are treated with surgery that either bypasses an obstructed vein or reconstructs the valves. Although these are open surgeries, they are performed in ways that are less invasive than in the past. “We now have techniques that improve the healing process and reduce the likelihood of recurrence,” says Dr. Lawrence. He notes that venous ulcers are preventable—among other things, after an episode of phlebitis, patients should be counseled to wear support hose.

Proper diagnosis of venous disease is critical to the success of treatment, Dr. Lawrence notes. In addition to the physical examination, imaging and physiologic studies are important. This includes specialized ultrasound and the magnetic resonance venogram—which has taken the place of the more invasive traditional venogram—to look at the flow of blood in three dimensions.

With a wider array of effective treatments now being offered, Dr. Lawrence suggests patients be referred to centers that have the full arsenal. ❖

### Recommended Reading

Lawrence PF, Gazak CE. Epidemiology of Chronic Venous Insufficiency. *Chronic Venous Insufficiency: Diagnosis and Treatment*. Ballard JL, Bergan JJ, Springer, 2000.



## Clinical Trial Evaluates New Stroke Treatment

UCLA is participating in a national clinical trial designed to compare carotid endarterectomy (CEA) to carotid artery stenting (CAS) in the prevention of stroke in patients with carotid bifurcation atherosclerosis. The study is known as the Carotid Revascularization Endarterectomy vs. Stent Trial (CREST).

“With the advent of safe and effective endovascular procedures, stenting devices have been used successfully in the heart, kidney and legs in the treatment of atherosclerotic disease,” notes Wesley Moore, M.D., UCLA vascular surgeon and principal investigator of the CREST study at UCLA. “The potential for a less invasive procedure that requires less anesthesia is appealing for our senior population.”

The study is comparing CEA with daily anti-platelet treatment to CAS with daily anti-platelet treatment. The trial originally focused on patients with territorial hemispheric or ocular symptoms within six months of randomization; now, however, the NIH and FDA have expanded the trial to include patients with asymptomatic, hemodynamically significant carotid bifurcation disease.

Carotid artery disease with the inherent risk of brain attack (TIA and stroke) threatens thousands of adults each year.

For more information, or to refer a patient for evaluation, call 310-206-1115.

# Aneurysms Repaired with Less Invasive Procedures

**T**he detection and repair of often silent, symptom-free bulges in blood vessels continues to improve as new techniques emerge at UCLA to treat abdominal aortic, popliteal artery and descending thoracic aorta aneurysms.

Abdominal aortic aneurysm—the 11th leading cause of death in the United States—generally is discovered by accident when a patient undergoes imaging for another reason. Worst case, the aneurysm is found only after it has burst and the patient is in severe crisis, says Wesley S. Moore, M.D., a UCLA vascular surgeon and a pioneer in the repair of aortic aneurysms.

Patients who do experience symptoms often complain of back pain, particularly in the lumbar area, as well as abdominal pain. Physicians often believe the patient is suffering from gall bladder or back problems and may order scans that will subsequently reveal the problem.

Early detection and strict patient monitoring are critical to prevent aneurysm ruptures, which are fatal about 90 percent of the time.

Simple and accurate methods of detection already exist to diagnose abdominal aortic aneurysm, an abnormal widening in the aorta usually occurring just below the renal artery. Physicians can perform physical examinations on the abdomens of high-risk populations or order an ultrasound, says William J. Quinones-Baldrich, M.D., UCLA surgeon.

Abdominal aortic aneurysms most often occur in people aged 65 and older. Males over 65 with hypertension are most at risk, Dr. Quinones-Baldrich says, and about a quarter of patients that develop these aneurysms have a family history of them. Other factors, such as smoking and chronic obstructive pulmonary disease, also increase risk.

Detecting the aneurysm early also is

vital, says Todd Reil, M.D., UCLA vascular surgeon, because even those who survive a rupture repair often will suffer from serious related health problems.

“This is a preventable cause of death,” says David A. Rigberg, M.D., UCLA vascular surgeon who, along with his colleagues, advocates routine testing in those most at risk. An initial screening test would indicate whether the aorta is enlarged, and therefore most at risk to rupture.

“Patients with smaller aneurysms would require follow-up imaging every six to 12 months,” Dr. Rigberg says. “Some patients, depending upon their age, might never need surgical repair.”

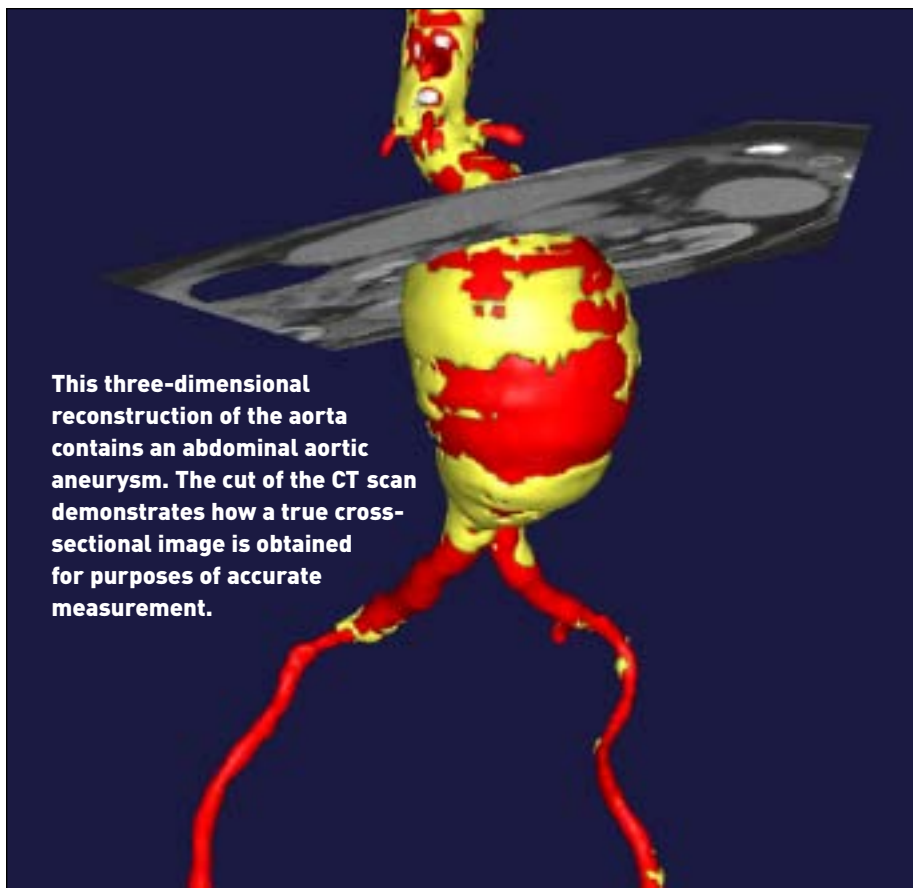
Aneurysms can be repaired using various surgical techniques.

Surgeons can open the abdominal cavity and clamp the aorta above and below the aneurysm and sew in a piece of plastic tubing to take the place of the weakened part of the aorta, Dr. Reil says. It’s a major procedure that requires blood transfusion and leaves the patient hospitalized for a week to 10 days and facing six to eight weeks of recovery time. Mortality rates with this conventional method of aneurysm repair are about 2 percent to 3 percent.

A newer technique, pioneered and tested at UCLA by Dr. Moore, is less invasive. “Patients are getting the same durable repair that an open operation would provide, but with a smaller, minimally invasive incision,” Dr. Reil explains. Called an endovascular approach, this imaging-guided technique uses the arteries in the groin to access the aneurysm and remotely deploy a stent graft to substitute for the weakened section of aorta. This technique basically inserts a new lining into the damaged aortic section and keeps the blood flow from the vulnerable area.

This type of repair is associated with lower mortality and morbidity, leaves the patient in less pain and facing a much quicker recovery. Patients typically spend one night in the hospital and feel better within a week.

UCLA surgeons have been performing such endovascular repairs since 1993. The procedure—first performed on the West Coast by Drs. Moore and Quinones-Baldrich—



**This three-dimensional reconstruction of the aorta contains an abdominal aortic aneurysm. The cut of the CT scan demonstrates how a true cross-sectional image is obtained for purposes of accurate measurement.**

cannot be done on all patients, however, depending upon their anatomy and the location of the aneurysm, so both techniques remain the gold standard of care.

Another technique, the retroperitoneal approach, calls for a relatively short incision on the patient's side. The repair of the damaged section of aorta is carried out without entering the abdominal cavity, so it is less invasive and patients experience a quicker recovery.

Laparoscopic aortic surgery is another viable alternative. Carlos Gracia, M.D., one of the pioneers of the procedure and director of UCLA's Minimally Invasive Surgery Program, along with Drs. Reil and Quinones-Baldrich, are developing a laparoscopic aortic program at UCLA and have performed procedures on 11 carefully selected patients. The laparoscopic surgery is in some cases done with the use of a robotic instrument, which can add precision to the repair and assist in training new surgeons in the minimally invasive method, Dr. Gracia explains.

### Popliteal Artery

**A**neurysms located in other parts of the body—behind the knee and in the wall of the aorta within the chest, specifically—are being repaired at UCLA using less invasive procedures.

Popliteal artery aneurysms, located behind the knee, rarely rupture, but can form blood clots that block circulation to the leg, leading in some cases to limb loss. If a physical examination and ultrasound study reveal a popliteal artery aneurysm larger than two centimeters and a blood clot against the aneurysm wall, then it needs to be repaired, notes Dr. Moore.

The traditional approach has been to take out the saphenous vein by making a long incision in the thigh, then tying off the artery above and below the popliteal aneurysm, followed by a vein graft bypass. "At UCLA, we use a more direct and simple approach," Dr. Moore explains. "Instead of the patient lying on their back during the procedure, we have him or her lie face down. We can then

make a short incision behind the knee, directly over the aneurysm, and use a short graft to repair the aneurysm." A review of UCLA's long-term results using this operation shows that the outcomes are superior to those of the ligation and vein bypass procedure, Dr. Moore says.

For patients at high risk of complications from general anesthesia, another option is an endovascular approach. In this procedure that uses local anesthesia, a stent graft is delivered through a sheath inserted into a normal artery in the thigh, which is then used to bridge and externally exclude the popliteal aneurysm. This approach may not be as durable, since bending of the knee could crush or dislodge the support structure of the graft, notes Peter Lawrence, M.D., director of UCLA's Gonda (Goldschmied) Vascular Center.

### Descending Thoracic Aorta

**R**epair of aneurysms of the descending thoracic aorta has also changed dramatically. In the past, the procedure required a large chest incision through which the aorta would be clamped above and below the aneurysm. While new tubing was sewn in during the surgery, some patients were put on a left heart bypass machine. "This procedure is associated with a higher mortality rate and a 10 percent risk of paraplegia," Dr. Moore says.

The new procedure used at UCLA uses a stent graft that is deployed through a sheath placed in the femoral artery in the groin. The graft bridges the normal aorta above and below the aneurysm. "This procedure is very well tolerated," Dr. Moore observes. "The risk of paraplegia is one-third that of the traditional procedure and the hospital stay is usually one to two nights." ❖

### Recommended Reading

Moore W, Matsumura JS, Makaroun MS, Katzen BT, Deaton DH, Decker M, Walker G, and EVT/Guidant Investigators. Five-year interim comparison of the Guidant bifurcated endograft with open repair of abdominal aortic aneurysm. *J Vasc Surg* 2003; 38: 46-55.

## Minimally Invasive Surgery Expands for Vascular Conditions

Minimally invasive surgery has quickly gone from a novelty to the dominant approach for many vascular procedures at UCLA.

Endovascular techniques are used to repair aneurysms, (including aortic, splenic artery, hepatic, celiac artery and mesenteric artery), aortoiliac occlusive diseases, and to harvest veins for bypass, for venous disease, and for carotid artery disease.

"Endovascular surgery has taken a predominant role in the treatment of vascular disorders," says Samuel Ahn M.D., UCLA vascular surgeon and co-author of the first textbook on endovascular surgery in the late 1980s. "We have fewer complications, and the complications that occur are less serious," he says. "The patient goes home and recovers much more quickly."

The shift toward minimally invasive approaches to vascular procedures has been accelerated by technological advances as well as refinements in the surgical techniques, Dr. Ahn notes. "The balloons, catheters and stents have gotten better, and as that has happened, we have gotten better," he says.

Although there are many unresolved issues in the relatively new field of minimally invasive vascular surgery, Dr. Ahn says, "The important thing to understand is that a lot of vascular diseases can now be treated with these methods, or in combination with open surgery to limit the trauma to the patient."

# UCLA Publications for Physicians

Please check the box next to each item you would like to receive.

## Clinical Updates

### Cardiology

- WE-01 Cardiac resynchronization therapy uses a specialized pacemaker to control heart contractions in patients with congestive heart failure due to dilated cardiomyopathy.

### Child and Adolescent Psychiatry

- WE-02 UCLA's Child OCD, Anxiety and Tic Disorders Program offers evaluation and cognitive, behavioral and psychopharmacological treatments.
- WE-03 A new outpatient program provides short-term therapy and instruction for children ages 3 to 12 years old with a wide range of psychiatric disorders.
- WE-04 UCLA's Teen Depression Clinic provides diagnostic evaluation, group therapy, family education and treatment, and other interventions for teens with mild to severe depression.

### Clinical Nutrition

- WE-05 For more than 25 years, UCLA's Risk Factor Obesity Weight Management program has offered a medically supervised, multidisciplinary program to help people lose weight and maintain weight loss.

### Pediatric Endocrinology

- WE-06 A UCLA study shows significant growth improvement in children treated with growth hormone using a new dosing model.

### Plastic and Reconstructive Surgery

- WE-07 Plastic surgeons work with the Revlon UCLA Breast Center team to provide consultation on breast reconstruction alternatives for patients with breast cancer and other breast-related problems.

### Neurology

- WE-08 UCLA's Alzheimer's Disease Research Center and Memory Disorders Clinic conduct clinical research and provide

consultative services for patients with age-related degenerative brain disorders that result in dementia.

### Radiology

- WE-09 Research shows digital mammography to be more effective for many women than standard film mammography.
- WE-10 UCLA becomes the first medical center in the western U.S. to offer 64-slice computed tomography (CT).

- WE-11 Virtual colonoscopy offered to patients who require a colon study but have contraindications for the optical colonoscopy.

### Urology

- WE-12 Robotically assisted prostatectomy allows surgeons greater flexibility in treating prostate cancer in a minimally invasive procedure.

## Newsletters and Reprints

### Newsletters

- WS-13 Clark Urological Center Newsletter Volume 17, Number 2 Summer 2005
- SS-16 Jules Stein Eye Institute Clinical Update, Volume 15, Number 1 January 2006
- SS-17 UCLA Pediatric Update Volume 12, Number 2 Summer 2005

### Journal Reprints from Proceedings of UCLA Healthcare

- SS-19 Infectious Mononucleosis-Like Syndrome (IMLS) Farid Farid, M.D.
- SS-20 Treatment of Duodenal Carcinoid with Argon Plasma Coagulation Harry L. Green, M.D.
- SS-21 Chills and Fever in an 18-Year-Old Female Nam C. Lim, M.D.
- SS-22 ASCUS and Cervical Cancer Joel I. Sarachek, M.D.

## Patient Learning Series

You can access the complete selection of the UCLA Healthcare Patient Learning Series at [www.healthcare.ucla.edu](http://www.healthcare.ucla.edu) Click on <Health Information> then <Patient Learning Series>

## Continuing Medical Education Opportunities

4th Annual UCLA Pulmonary and Critical Care Update  
February 17-18, 2006  
Casa Del Mar Hotel by the Sea  
Santa Monica, California

3rd Annual UCLA Gastroenterology Symposium—Gastrointestinal Cancer: A Multidisciplinary Approach  
February 18-19, 2006  
Beverly Hilton Hotel  
Beverly Hills, California

UCLA State-of-the-Art Urology  
March 9-12, 2006  
Coronado Island Marriott Resort  
Coronado, California

Primary Care Update Las Vegas  
March 24-26, 2006  
Palms Casino Resort  
Las Vegas, Nevada

24th Carl M. Pearson Memorial Symposium—Frontiers of Rheumatology  
April 28-30, 2006  
Hilton Waterfront Beach Resort  
Huntington Beach, California

Case Managers Update 2006  
May 11, 2006  
Riviera Country Club  
Pacific Palisades, California

For additional CME opportunities, visit our website at [www.healthcare.ucla.edu](http://www.healthcare.ucla.edu). Click on <Healthcare Professionals> then <CME>

## Need Copies?

**Download** Clinical Updates at [www.healthcare.ucla.edu](http://www.healthcare.ucla.edu). Click on <For Healthcare Professionals>.

Or check the items you'd like to receive and:

**Fax** this page to us at **310 794-8696**.

**Mail** this page to us. Fold it to display the "Business Reply Mail" section on the outside and tape closed.

NAME (Please Print) \_\_\_\_\_ SPECIALTY \_\_\_\_\_

ADDRESS \_\_\_\_\_

CITY \_\_\_\_\_ STATE \_\_\_\_\_ ZIP \_\_\_\_\_



Look inside for  
 UCLA Publications for  
 Physicians

and access the latest

- Clinical updates
- Newsletters
- Reprints
- Patient learning series
- Continuing medical education programs

Visit our award-winning website  
[www.healthcare.ucla.edu](http://www.healthcare.ucla.edu)  
 to download printable  
 PDF files

UCLA HEALTH SCIENCES research & education

UCLA Healthcare

FOR HEALTHCARE PROFESSIONALS

**UCLA Clinical Updates**


Clinical Updates are brief reports provided to keep the community referring physician informed about news from UCLA that may be of benefit to his or her practice of Medicine. Updates address research or treatment advances and new technological applications, important clinical trials, and inpatient or outpatient programs available at UCLA Medical Center.

Type	Description	Date
Transplant Surgery	Non-Standard donor lungs increase transplant options for older, high-risk patients.	Feb-05
Urologic Oncology	Cryosurgery for Renal Cell Carcinoma	Feb-05
Urology	UCLA Urologists Develop a modified and variation on their prostate cryosurgery beneficial to the treatment of prostate cancer.	Feb-05
Psychiatry	UCLA Autism Evaluation Clinic	Jan-05
Transplant	UCLA Transplant Program	12-04
Urologic Oncology	Ovarian Cancer Facts Detection Clinical Trial	11-04

[www.healthcare.ucla.edu](http://www.healthcare.ucla.edu)



NO POSTAGE  
 NECESSARY  
 IF MAILED  
 IN THE  
 UNITED STATES



**BUSINESS REPLY MAIL**  
 FIRST-CLASS MAIL PERMIT NO. 16046 LOS ANGELES, CA 90024

POSTAGE WILL BE PAID BY ADDRESSEE

**UCLA HEALTHCARE  
 MARKETING COMMUNICATIONS HA 68  
 10920 WILSHIRE BOULEVARD SUITE 1010  
 10833 LE CONTE AVE  
 LOS ANGELES CA 90099-4973**



## UCLA Gonda (Goldschmied) Vascular Center

### **Dedicated to the evaluation, diagnosis and management of vascular diseases**



A state-of-the-art facility offering in one setting high-quality care to patients with varicose veins, non-healing wounds, venous insufficiency, lymphedema, and thoracic outlet syndrome, and to dialysis patients requiring shunts and graft



A world-renowned center for the treatment of all types of aneurysms



Expert management of atherosclerosis using balloons, stents, lasers and minimally invasive surgical bypasses



For more information, call 310-825-7922 or 800-UCLA-MD1

## UCLA PHYSICIANS' UPDATE

*Director of Marketing*  
Pattie Cuen

*Editor*  
Judi Goodfriend

*Contributors*  
Dan Gordon  
Kim Irwin

*Design*  
The Doyle/Logan Company

*Editorial Board*  
Dr. Peter Lawrence  
Dr. Todd Reil  
Dr. David Rigberg  
Dr. Joe Hines  
Dr. Tom Sibert

Copyright © 2006 UCLA Healthcare.  
All rights reserved.

Inquiries about *UCLA Physicians' Update* should be directed to  
UCLA Medical Center  
Marketing Communications  
10920 Wilshire Blvd., Suite 1010  
Los Angeles, California 90095-6923  
[www.healthcare.ucla.edu](http://www.healthcare.ucla.edu)

UCLA Healthcare

UCLA Healthcare  
Marketing Communications HA68  
10920 Wilshire Blvd. Suite 1010  
Los Angeles, CA 90024-6502



NON-PROFIT  
ORGANIZATION  
U.S. POSTAGE  
PAID  
UCLA