

Frozen Section Protocol for skin specimens from Dr. Bernard Markowitz:

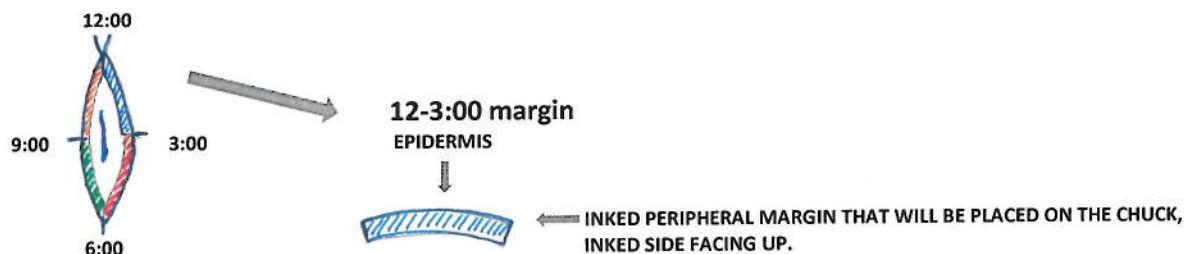
These cases already have a biopsy diagnosis before the surgical excision is performed and Dr. Markowitz is **ONLY** interested in obtaining clear surgical margins. The usual specimen is a skin ellipse that will be oriented with a suture. The margins are submitted "en face," similar to the technique used in Mohs micrographic surgery. The process is outlined below:

The specimen should be divided into 4 quadrants and differentially inked using five colors:

NOTE:

If the specimen is thin, four colors can be used.

The inked peripheral margins are shaved off and each quartile (e.g. 12-3:00, 3-6:00, 6-9:00, 9-12:00) is submitted separately (one per chuck) "en face" with the inked-side facing up. Please make sure the specimen is oriented correctly on the chuck to ensure that a complete epidermal surface will be visualized on the frozen section slide.



SUBMIT THE REMAINING MARGINS (3-6:00, 6-9:00, AND 9-12:00) USING THE SAME PROCESS.

When preparing the frozen section, the technician should cut an initial superficial section and one deeper section (to ensure proper visualization of the entire margin). Since these tissue fragments are typically quite thin, be sure not to cut too deep initially or you may lose the tissue fragment.

Typically, Dr. Markowitz is only interested in the peripheral margins. However, on occasion he may request a deep margin as well. If so, then the remaining tissue (now with the peripheral margins removed) may be placed ink-side up on a final (5th) chuck and a final deep "en face" margin can be cut. If no deep margin is requested, this remaining tissue fragment should be submitted for permanent sectioning as per the usual protocol.