

GASTROINTESTINAL PATHOLOGY GROSSING GUIDELINES

Specimen Type: LAR (LOW ANTERIOR RESECTION)

Procedure:

1. Measure length and range of diameter or circumference. Measure the bowel and anus separately.
2. Describe external surface, noting color, granularity, adhesions, fistula, discontinuous tumor deposits, areas of retraction/puckering, induration, stricture, or perforation.
3. Note any enlarged lymph nodes and thrombosed vessels or other vascular abnormalities.
4. Open the bowel longitudinally along the anterior surface, while trying to avoid cutting through the tumor.
5. Measure any areas of luminal narrowing or dilation (location, length, diameter or circumference, wall thickness), noting relation to tumor.
6. Describe tumor, noting size, shape, color, consistency, appearance of cut surface, % of circumference of the bowel wall involved by the tumor, depth of invasion through bowel wall, and distance from margins of resection (radial/circumferential margin, mesenteric margin, closest proximal or distal margin).
 - a. If resection includes mesorectum, gross evaluation of the intactness of mesorectum must be included. For rectum, the location of the tumor must also be oriented: anterior, posterior, right lateral, left lateral.
 - b. If a rectal tumor is close to distal margin, the distance of tumor to the distal margin should be measured when specimen is stretched. This is usually done during intraoperative gross consultation when specimen is fresh.
 - c. If the tumor is in a retroperitoneal portion of the bowel (e.g. rectum), radial/retroperitoneal margin must be inked and one or more sections must be obtained (a shave margin, if tumor is far from the radial margin; and perpendicular sections showing the relationship of the tumor to the inked radial margin, if tumor is close to the radial margin).
 - d. If the tumor is in a peritonealized portion of the bowel (e.g. sigmoid colon), then the serosal surface over the tumor needs to be inked. If tumor grossly puckers the serosa, one or more perpendicular sections must be taken to show the relationship of the tumor to the inked serosal surface).
 - e. Mesenteric margin is evaluated grossly for tumor involvement for segments with mesentery (transverse and sigmoid colon). The distance of tumor to the mesenteric margin should be described.
7. Describe the appearance of uninvolved mucosa.
8. Describe the size, appearance and location of any additional lesions such as polyps.
9. Dissect mesenteric and pericorectal adipose tissue for lymph nodes. Note range of size and appearance of cut surface of lymph nodes.

Gross Template:

Labeled with the patient's name (***), medical record number (***), designated ***, and received [*fresh/in formalin*] is a low anterior resection. [*Indicate orientation if provided*]. The colon measures *** cm in length and ranges from *** to *** cm in open circumference. Attached fibroadipose tissue extends up to *** cm from the bowel wall.

GASTROINTESTINAL PATHOLOGY GROSSING GUIDELINES

The serosal surface is remarkable for [*describe, if applicable*]. The mucosa of the [*describe location-sigmoid, rectosigmoid junction, rectum*] is remarkable for a [*describe lesion: size (___ x ___ x ___ cm), shape (e.g. polypoid, ulcerated, fungating), color, consistency (e.g. soft, firm, friable)*]. The lesion involves ***% of the circumference of the bowel [*describe obstruction or strictures caused by lesion*]. The lesion is located *** cm [*proximal/distal*] to the rectosigmoid junction. Sectioning reveals the [*lesion/mass*] has a [*describe color, consistency*] cut surface. The [*lesion/mass*] [*is grossly superficial, extends into the bowel wall, extends through the bowel wall into the fibroadipose tissue (for GISTs or serosa-based lesions indicate layers of bowel wall involved and any associated mucosal ulceration)*]. The lesion measures *** cm from the proximal margin, *** cm from the distal margin, *** cm from the [*radial/mesenteric*] margin [*please ask for margin determination if needed*], and *** cm from the serosal surface [*if located above the level of peritoneal reflection*].

The remainder of the bowel serosa is [*tan, smooth, glistening, and unremarkable or describe any additional lesions*]. The remainder of the bowel mucosa is [*tan, glistening, folded, and unremarkable or describe any additional lesions*]. The bowel wall thickness ranges from *** to *** cm. The unremarkable bowel wall measures *** cm in thickness [*can describe varying thickness of wall, provide location where wall is thicker*]. *** of lymph nodes are identified, ranging from *** to *** cm in greatest dimension.

All identified lymph nodes are entirely submitted. [*The lesion/mass is entirely submitted (if applicable, otherwise skip to next sentence)*] Representative sections of the remaining specimen are submitted.

Ink key:

Black – mesenteric/radial margin overlying lesion

Blue – serosa overlying lesion

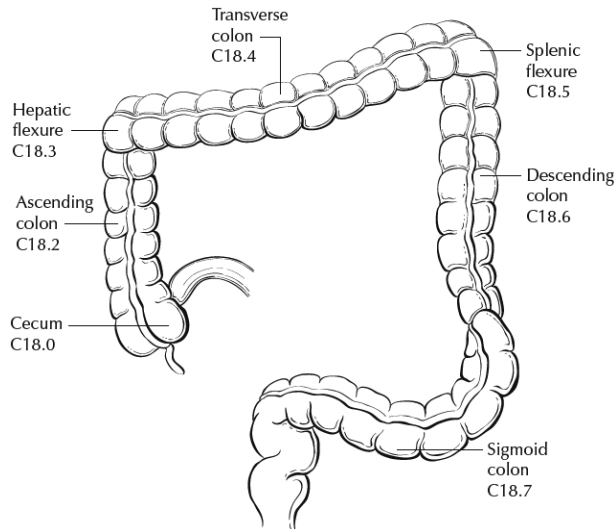
[*Additional inking description if proximal/distal margins taken perpendicularly*]

Cassette Submission: 15-20 cassettes

- Proximal resection margin, shave (perpendicular if close to tumor)
- Distal resection margin, shave (perpendicular if close to tumor)
- Mesenteric/radial resection margin (perpendicular section with nearest approach to tumor), or a shave if tumor is far away
- One cassette per 1 cm of tumor (OR at least 5 sections of tumor OR if small enough, entirely submit)
 - o Show maximum depth of invasion
 - o Show nearest approach to serosal surface
 - o Show relationship to unremarkable mucosa
 - o Show relationship to any contiguous or adherent organs
- If the resection is for a large adenomatous polyp with no gross invasion - entirely submit
- Sampling any additional pathology in the gross description (ulcers, polyps, etc.)
- Representative sections of unremarkable colon/rectum in one cassette

GASTROINTESTINAL PATHOLOGY GROSSING GUIDELINES

- Submit all lymph nodes identified (at least 12 lymph nodes are suggested for colorectal carcinoma)
- **Note:** If no tumor is grossly identified and instead an area of ulceration or scar is present (which is often the case for rectal carcinomas status post neoadjuvant therapy), then the entire ulcer or scar area needs to be submitted.



Anatomic Subsites of the Colon and Rectum

Site	Relationship to Peritoneum	Dimensions (approximate)
Cecum	Entirely covered by peritoneum	6 x 9 cm
Ascending colon	Retroperitoneal; posterior surface lacks peritoneal covering; lateral and anterior surfaces covered by visceral peritoneum (serosa)	15-20 cm long
Transverse colon	Intraperitoneal; has mesentery	Variable
Descending colon	Retroperitoneal; posterior surface lacks peritoneal covering; lateral and anterior surfaces covered by visceral peritoneum (serosa)	10-15 cm long
Sigmoid colon	Intraperitoneal; has mesentery	Variable
Rectum	Upper third covered by peritoneum on anterior and lateral surfaces; middle third covered by peritoneum only on anterior surface; lower third has no peritoneal covering	12 cm long