

Genitourinary Grossing Guidelines

Specimen Type: NEPHROURETERECTOMY (resection)

Procedure:

1. Weigh and measure overall dimensions of specimen. Ink the surface of kidney/Gerota's fascia or perinephric fat. Describe external surface of ureter and palpate for tumor in ureter, ink ureter differentially following the ink codes below.
2. Inspect perinephric fat for adrenal (usually absent). Locate renal arteries and vein. Remove vascular margins and place in one cassette, en face.
3. Measure the length and diameter (range in diameter) of the ureter and bladder cuff if present.
4. If a bladder cuff is present, amputate it, radially section centering the ureteral orifice, and submitted entirely in 2-3 cassettes.
5. If bladder cuff is not present and mass is not close to distal ureteral margin, shave the distal ureter margin. If mass is close to distal ureter margin, a perpendicular section should be taken.
6. Open ureter along its length. Examine ureteral mucosa.
7. At renal hilum, push one probe through renal pelvicalyceal system and push through renal parenchyma of superior pole.
8. Place second probe in renal pelvicalyceal system and push through renal parenchyma of inferior pole.
9. Using 2 probes as guides, divide kidney in two complete halves, cutting longitudinally through the renal pelvis. Completely open pelvis and calyces.
10. Measure kidney. Examine pelvicalyceal mucosa
11. Describe mucosal tumors, including the number, size, shape, location, distance from the pelvi-calyceal junction and distal margin
12. Pin the ureter, photograph the entire ureter and half of the kidney. If tumor is friable, fix overnight.
13. Take transverse sections of the tumor and ureter / take sections of tumor and pelvis. Describe extent of invasion and measure depth of invasion and distance to circumferential/deep margin.
14. Document if the ureter mass causes strictures or dilatation.
15. If tumor is small enough, submit entire tumor proximal to distal sequentially. If tumor is big, submit representative sections to include the greatest depth of invasion and the closest circumferential/deep margin.
16. Describe uninvolved mucosa of ureter and renal pelvis and measure ureter wall.

Gross Template:

Labeled with the patient's name (**), medical record number (**), designated "****", and received [*fresh/in formalin*] is a [*right,left*] **g, ** x ** x ** cm nephroureterectomy. The kidney alone measures ** x ** x ** cm . [*Describe adrenal gland if present-measure*]. The ureter measures ** cm in length and ranges from ** to ** cm in diameter. A bladder cuff margin is not *identified/present, measuring ** cm in diameter and ** in length*. The external surface of the kidney and ureter is inked differentially as coded below.

Genitourinary Grossing Guidelines

The bladder cuff/distal ureter margin is removed and the ureter is open along its entire length. The kidney is then longitudinally bivalved along the pelvicalyceal system. The pelvicalyceal system and proximal ureter [*is/ is not*] dilated. [*Describe calculi if present*] [*describe obstruction and dilation of calyces if present*].

There is a [*describe mass- size, focality, circumscription, encapsulation, color, consistency, necrosis, hemorrhage*] located in the [*upper, mid, lower pole*] of renal pelvis / calyces [*upper, mid, distal*] ureter. The mass measures *** cm from pelvicalyceal junction / distal ureter margin / bladder cuff margin. On sectioning, the mass invades [*into the muscularis, hilar fat/ periureteric fat, into the renal parenchyma*]. The mass has a *** cut sections, measures *** cm in deepest invasion and *** cm from the circumferential margin. The remaining pelvic and ureter mucosa is [*pink-tan, unremarkable*] / is [*smooth, roughened, granular, thickened, other.*] [*Describe additional mucosal lesions or erythematous patches*]. The uninvolved ureter wall is tan-white and has a *** cm average thickness.

The renal parenchyma is [*unremarkable, or describe additional pathology*]. The corticomedullary junction is [*distinct/ poorly defined*]. *** hilar lymph nodes are identified ranging from *** to *** cm in greatest dimension. Gross photographs are taken. Representative sections are submitted [*describe cassette submission*].

Ink key:

Blue – kidney and proximal third ureter

Black - mid portion of ureter

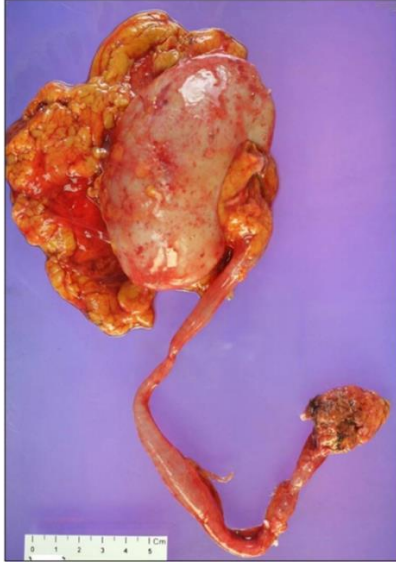
Green - distal third ureter

Red - bladder cuff margin

Cassette Submission:

- Renal vascular margin, en face
- Distal ureter margin, en face / bladder cuff margin, radially sectioned
- One section per 1 cm of tumor, up to 5 cassettes
 - To include renal pelvic tumor with invasion into muscularis, renal parenchyma, or hilar fat
 - To include ureter tumor with the deepest invasion into the ureteral wall, periureteric fat, closest circumferential margin.
- Submit additional mucosal lesions
- Grossly uninvolved renal pelvis, proximal and distal ureter.
- Renal parenchyma, representative
- Submit all lymph nodes

Genitourinary Grossing Guidelines



Bladder cuff margin, where
the ureter inserts into bladder