

Gynecologic Pathology Grossing Guidelines

PLACENTA

COMMENT: PLEASE TAKE GROSS PHOTOS OF INTACT PLACENTAS WITH SIGNIFICANT GROSS FINDINGS; IF UNSURE, TAKE A PHOTO!

TWIN

1. Indicate whether the placentas are separate or fused.
 - a. If separate, examine each placenta as described for singletons.
 - b. Dictate as **non-fused diamniotic dichorionic twin placenta**.
 - c. Weigh and measure, dictate **combined weight as well as individual weights**.
2. If fused, note the presence of a dividing membrane and its appearance. Indicate if no dividing membrane is present (i.e. monoamniotic)
3. If two amniotic cavities are found, indicate if they are of equal or unequal size. Estimate the relative proportion of the fused chorionic plate supplied by the vascular distribution of each twin.
4. Describe any surface vessel anastomoses between twins [*artery-artery, vein-vein, artery-vein*], or segments perfused by an artery from one twin and venous return to the other (deep anastomoses).
5. Make a roll of the dividing membrane and free membranes from each placenta.
6. Examine each half of the placenta(s) as described under "single placenta".
7. Submit sections as follows:
 - a) Two cross sections of both umbilical cords, as above.
 - b) Sections of both free membrane rolls to include origin of membranes, if possible.
 - c) Cross section of the roll of the dividing membrane and "T-zone" of the septal insertion.
 - d) Placental tissue as described under single placenta.

Gross Template:

Labeled with the patient's name (***), medical record number (***), designated "****", and received [*fresh/in formalin*] is a fused [*diamniotic, dichorionic; diamniotic, monochorionic; monoamniotic, monochorionic*] twin placenta[s]. The chorionic disk[s] together weigh *** gm (devoid of cord and membranes) and measure *** x *** x *** cm. The dividing membranes are [*pink-tan, thin and translucent, green, thickened, opaque*]. There [are/ are no] anastomosing vessels (*if present, describe what vessels are anastomosed*). The cotyledons are [*all present and intact or disrupted or incomplete*]. There [*is no/is- if present give size and location*] retroplacental hemorrhage. No twin sequence has been indicated. The umbilical cords and respective portions of the chorionic disc are designated for descriptive purposes by [cord clamps, cord length, insertion]. [*If orientation is provided indicate. Orientation is often designated by the number of clamps on the umbilical cord*].

Umbilical cord A [*provide clamp designation or the number of clamps or other description if undesignated*], is trivascular, and measures *** cm in length x *** cm in diameter and [*eccentrically, centrally, peripherally, velamentously*] inserts *** cm from

Gynecologic Pathology Grossing Guidelines

the margin. There [are/are no] cord knots, thromboses, or focal lesions present. There are [#] [right, left] handed coils per 10 cm. The vascular distribution covers approximately ***% of the fused chorionic disk. The fetal surface is [pink-purple and smooth]. There is [scant, moderate, extensive-quantify if extensive] subchorionic fibrin present. There [is/is no] squamous metaplasia, amnion nodosum, or gross meconium. Surface vessels are [normal/congested/focally thrombosed]. The [pink-tan, thin and translucent, green, thickened, opaque] membranes insert [peripherally, circummarginate, circumvallate over #% of the disc circumference]. The nearest point of rupture measures *** cm from the margin. There [is/is no] accessory lobe present. The chorionic disk weighs *** gm and measures *** x *** x *** cm [include this if disks are separated]. Sectioning the chorionic plate of twin A reveals [a red-brown cut surface, describe lesions-intervillous hematomas and infarcts (color, consistency, location)-provide % of placental disc involved]. The remaining parenchyma is [dark red-purple or light pink-red] and soft with [normal, increased] calcifications. No additional lesions or masses are grossly identified.

Umbilical cord B [provide clamp designation or the number of clamps or other description if undesignated], is trivascular, and measures *** cm in length x *** cm in diameter and [eccentrically, centrally, peripherally, velamentously] inserts *** cm from the margin. There [are/are no] cord knots, thromboses, or focal lesions present. There are [#] [right, left] handed coils per 10 cm. The vascular distribution covers approximately ***% of the fused chorionic disk. The fetal surface is [pink-purple and smooth]. There is [scant, moderate, extensive-quantify if extensive] subchorionic fibrin present. There [is/is no] squamous metaplasia, amnion nodosum, or gross meconium. Surface vessels are [normal/congested/focally thrombosed]. The [pink-tan, thin and translucent, green, thickened, opaque] membranes insert [peripherally, circummarginate, circumvallate over #% of the disc circumference]. The nearest point of rupture measures *** cm from the margin. There [is/is no] accessory lobe present. The chorionic disk weighs *** gm and measures *** x *** x *** cm [include this if disks are separated]. Sectioning the chorionic plate of twin B reveals [a red-brown cut surface, describe lesions-intervillous hematomas and infarcts (color, consistency, location)-provide % of placental disc involved]. The remaining parenchyma is [dark red-purple or light pink-red] and soft with [normal, increased] calcifications. No additional lesions or masses are grossly identified.

Representative sections are submitted.

SAMPLE Cassette Submission:


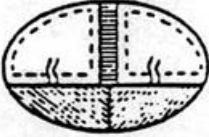
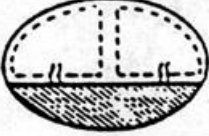

A1	Placenta A - umbilical cord (fetal end) and membranes
A2	Placenta A - umbilical cord (maternal end) and central placenta
A3, A4	Placenta A - central placenta (bisected)
A5	Placenta B - umbilical cord (fetal end) and membranes
A6	Placenta B - umbilical cord (maternal end) and central placenta
A7, A8	Placenta B - unremarkable central placenta (bisected)
A9	Placenta B - peripheral placenta with possible retroplacental hemorrhage
A10	Dividing membranes

PLACENTA—TWIN cont'd

Dividing membrane in twin placentas

Features	Dichorionic-diamniotic (fused)	Monochorionic-diamniotic
Appearance	Thick and opaque	Thin and transparent
Separation of membranes by stripping	Difficult	Easy
Point of attachment to fetal surface	Ridge or tearing of chorion	Smooth and continuous, without ridge
Vascular anastomoses	Very rare	Numerous

Types of twin placentas

Type	Incidence	Gross	Twin type
Dichorionic-diamniotic (separate)	35%		Monozygotic or dizygotic
Dichorionic-diamniotic (fused)	34%		Monozygotic or dizygotic
Monochorionic-diamniotic	30%		Monozygotic
Monochorionic-monoamniotic	1%		Monozygotic

Gynecologic Pathology Grossing Guidelines

Week post conception	Week post last menstruation	Crown-rump (mm)	Fetal weight (gm)	Placental diameter (mm)	Placental weight (gm)	Placental thickness (mm)	Umbilical cord length (mm)
	1						
	2						
1	3						
2	4						
3	5	2.5					
4	6	5					5
5	7	9					
6	8	14	1.1		6		
7	9	20	2				
8	10	26	5		14		
9	11	33	11				
10	12	40	17		26		
11	13	48	23	50 - 75			160 - 180
12	14	56	30		42	10	
13	15	65	40				
14	16	75	60	75 - 100	65	12	220 - 300
15	17	88	90				
16	18	99	130		90		
17	19	112	180				
18	20	125	250	100 - 125	115	15	330 - 350
19	21	137	320				
20	22	150	400		150		
21	23	163	480				
22	24	176	560	125 - 150	185	18	370 - 400
23	25	188	650				
24	26	200	750		210		
25	27	213	870				
26	28	226	1000	150 - 170	250	20	420 - 450
27	29	236	1130				
28	30	250	1260		285		
29	31	263	1400				
30	32	276	1550	170 - 200	315	22	460 - 490
31	33	289	1700				
32	34	302	1900		355		
33	35	315	2100				
34	36	328	2300	200 - 220	390	24	500 - 520
35	37	341	2500				
36	38	354	2750		425		
37	39	367	3000				
38	40	380	3400		470	25	

Data taken from table in "Pathology of the Human Placenta", 2nd ed., Benirschke, Kurt, 1990, pg 343. [Data compiled from Boyd & Hamilton (1970), O'Rahilly (1973), Johannigmann *et al.* (1972), and Winchel (1893)]