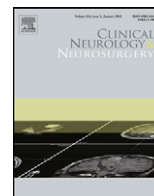




Contents lists available at [SciVerse ScienceDirect](http://www.sciencedirect.com)

## Clinical Neurology and Neurosurgery

journal homepage: [www.elsevier.com/locate/clineuro](http://www.elsevier.com/locate/clineuro)



# Diaphragm paralysis caused by transverse cervical artery compression of the phrenic nerve: The Red Cross syndrome

Matthew R. Kaufman<sup>a,\*</sup>, Lourens J. Willekes<sup>b</sup>, Andrew I. Elkwood<sup>a</sup>, Michael I. Rose<sup>a</sup>, Tushar R. Patel<sup>a</sup>, Russell L. Ashinoff<sup>a</sup>, Alan R. Colicchio<sup>c</sup>

<sup>a</sup> The Institute for Advanced Reconstruction – 535 Sycamore Avenue, Shrewsbury, NJ 07702, United States

<sup>b</sup> Eastern Thoracic Surgery, 65 Mechanic Street, Red Bank, NJ 07701, United States

<sup>c</sup> Department of Neurology, Jersey Shore University Medical Center – 1944 State Route 33, Neptune, NJ 07753, United States

### ARTICLE INFO

#### Article history:

Received 16 December 2011  
Received in revised form 17 January 2012  
Accepted 28 January 2012  
Available online xxx

#### Keywords:

Phrenic nerve  
Compression neuropathy  
Diaphragm paralysis  
Peripheral nerve injury  
Nerve decompression

### ABSTRACT

**Background:** The etiology of diaphragm paralysis is often elusive unless an iatrogenic or traumatic injury to the phrenic nerve can be clearly implicated. Until recently, there has been little interest in the pathophysiology of diaphragm paralysis since few treatment options existed.

**Methods:** We present three cases of symptomatic diaphragm paralysis in which a clear clinico-pathologic diagnosis could be identified, specifically a vascular compression of the phrenic nerve in the neck caused by a tortuous or adherent transverse cervical artery.

**Results:** In two patients the vascular compression followed a preceding traction injury, whereas in one patient an inter-scalene nerve block had been performed. Following vascular decompression, all three patients regained diaphragmatic motion on fluoroscopic chest radiographs, and experienced a resolution of respiratory symptoms.

**Conclusion:** We suggest that vascular compression of the phrenic nerve in the neck may occur following traumatic or iatrogenic injuries, and result in symptomatic diaphragm paralysis.

© 2012 Published by Elsevier B.V.

## 1. Introduction

Although diaphragm paralysis is a rather uncommon problem, the respiratory disturbances that it causes can be debilitating for those unfortunate patients in whom it occurs. Traditionally, clinicians have suggested to affected patients they learn to live with the condition, anticipating spontaneous improvement and acknowledging limited treatment options. Common presenting symptoms in patients with diaphragm paralysis include: shortness of breath with exertion and/or when supine, increased fatigue, loss of energy, gastrointestinal reflux and bloating (left-sided paralysis), and sleep disturbances.

There are several etiologies that have been described, most relating to surgical, anesthetic, or chiropractic complications in the neck and/or chest [1–8]. Traumatic events that cause a traction-type injury – when the neck is jolted in an opposite direction from the shoulder and arm – has been implicated as a cause of diaphragm paralysis, although is more commonly associated with injury to the brachial plexus [9]. There are generalized neuromuscular disorders, such as amyotrophic lateral sclerosis, Pompe disease, and

diabetic peripheral neuropathy, which may present with, or include diaphragm paralysis as part of their sequelae [10–12]. Often, however no clear etiology exists, and patients will be labeled as having a variant of Parsonage-Turner syndrome, or classified with an idiopathic diaphragm paralysis [13,14].

Until recently, there has been no way to reverse the paralysis. Instead, some patients are offered a diaphragm plication to increase lung volumes by flattening the diaphragm in its inspiratory position. Whereas this may be an effective method for reducing respiratory deficits, restoration of spontaneous diaphragmatic activity remains the ultimate goal. Phrenic nerve surgery has recently been demonstrated as an effective way to reverse diaphragm paralysis, and in some cases, has also provided insight into the underlying pathophysiology of the paralysis condition [15].

We present three cases of symptomatic diaphragm paralysis that were determined to be from vascular compression of the phrenic nerve following traumatic or iatrogenic injuries.

## 2. Methods

We retrospectively reviewed three patients who presented with chronic, symptomatic unilateral diaphragm paralysis that failed to improve with conservative management over a minimum six month period. They were selected from a larger cohort of patients

\* Corresponding author. Tel.: +1 732 741 0970; fax: +1 732 747 2606.  
E-mail address: [matthewrkmd@gmail.com](mailto:matthewrkmd@gmail.com) (M.R. Kaufman).

with diaphragm paralysis, based upon positive findings of a vascular compression of the phrenic nerve. Two of the patients had experienced a preceding traction injury, one from a fall on an outstretched arm and the other from a sleep-related positional injury. The third patient had undergone an inter-scalene nerve block for shoulder surgery. The Institutional Review Board at our hospital approved the study and informed consent was obtained in accordance with study approval.

In all patients diaphragm paralysis was confirmed on fluoroscopic chest radiographs (SNIFF), revealing either absence of diaphragmatic activity on the involved side, or paradoxical motion. Lung spirometry (PFT) was performed to document a restrictive pulmonary deficit consistent with diaphragm paralysis. All patients underwent nerve conduction testing (NCS) of the phrenic nerve and electromyography (EMG) of the diaphragm to confirm the existence of a compression neuropathy of the phrenic nerve with preservation of the motor end-plates. Additional radiographic imaging studies were obtained (MRI, CT) to rule out the possibility of degenerative cervical disc disease, or a mass in the neck, mediastinum, or chest cavity.

Surgery was offered after a minimum of six months from the onset of symptoms when no spontaneous improvement was noted clinically or radiographically. All patients underwent exploration and decompression of the phrenic nerve, and nerve testing was performed intra-operatively both before, and after decompression to assist in predicting clinical improvement. Vascular compression of the phrenic nerve was treated by ligation of the transverse cervical artery (TCA). The adherence between the artery and the nerve was released and a microscopic neurolysis was performed to remove the fibrous tissue from the compressed portion of the phrenic nerve. An anti-inflammatory agent (triamcinolone 40 mg/mL) was then infiltrated into the wound cavity to prevent post-operative scar tissue and fibrosis.

All three patients were discharged from the hospital on post-operative day one. A program of pulmonary rehabilitation was initiated at three weeks, and continued for up to four months post-operatively to maximize early improvements. Follow-up evaluation included SNIFF testing and lung spirometry at three months, and subjective reports of improvements in respiratory function.

### 3. Results

There were two males and one female, with an average age of 49 (range 40–54yrs) [see Table 1]. In two patients the diaphragm paralysis was left-sided, whereas a right-sided diaphragm paralysis was present in one patient. In two patients the diaphragm paralysis had been present for greater than one year without improvement, whereas the diagnosis had been made eight months prior in one patient.

All three patients described shortness of breath symptoms exacerbated with exertion. In one patient sudden, severe dyspnea occurred when turning her head to the affected side. Sleep disturbances were reported by all patients, two of whom required nocturnal CPAP for significant sleep-disordered breathing. In the patients with left-sided diaphragm paralysis, symptoms of bloating

**Table 1**  
Demographics and outcomes of patients with vascular compression of the phrenic nerve.

Patient	Age	Sex	Side	NCS (ms)	EMG (mV)	FEV1	FVC	Recovery
1	40	M	L	16.8	0.02	74%	76%	+
2	52	F	R	7.7/ND <sup>a</sup>	0.4/ND <sup>a</sup>	60%	52%	+
3	54	M	L	16.09	0.2	62%	73%	+

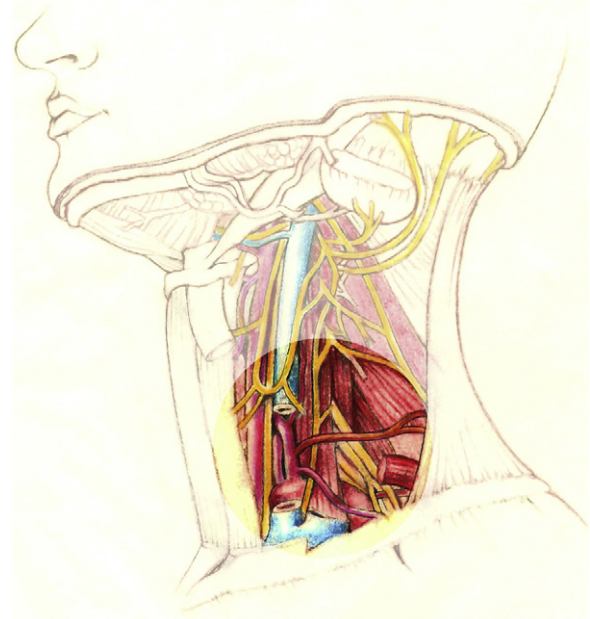
<sup>a</sup> ND – patient 2 had no detectable NCS/EMG response with her head turned to the right.

and GERD were reported. One patient was on full medical disability due to the respiratory symptoms of diaphragm paralysis and a second patient was on restricted duty, unable to perform manual labor. The third patient was an executive who could perform daily work responsibilities.

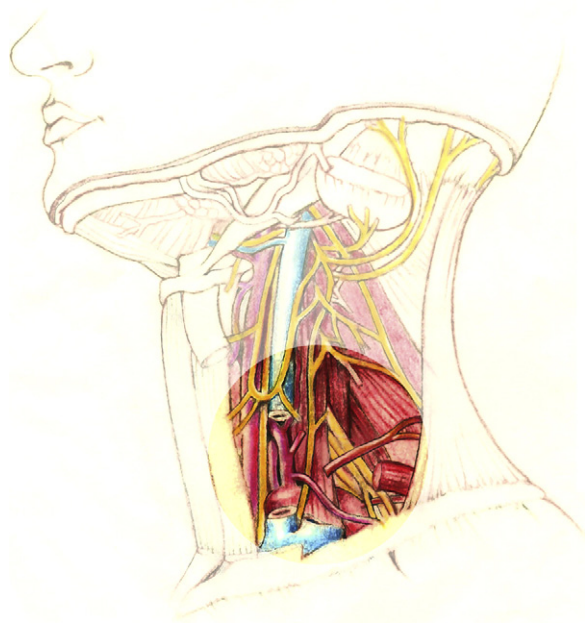
All patients had SNIFF tests demonstrating an unequivocal unilateral diaphragm paralysis and spirometry results consistent with a mild-to-moderate restrictive ventilatory deficit. The results of NCS/EMG testing revealed the following conduction velocities (mean 13.53 ms, range 7.7–16.8 ms; [ref.  $8.0 \pm 1.5$  ms]) and motor unit potential amplitudes (mean 0.21 mV, range 0.02–0.4 mV; [ref.  $\geq 0.33$  mV]) [see Table 1]. PFT testing results in all patients revealed a restrictive ventilatory deficit in the mild-to-severe range (mean FEV1 66%, range 60–74%; mean FVC 67%, range 52–76%). Of note, the patient whose head turning exacerbated dyspneic symptoms demonstrated a conduction velocity of 7.7 ms and motor amplitude of 0.4 mV with her head in a neutral position (normal values), however no response was detectable in either test with her head turned to the right.

The surgical procedure performed in all three patients uncovered a vascular compression of the phrenic nerve in the neck, specifically at the location where the TCA crosses above it (see Fig. 1). In one patient the TCA appeared tortuous and dilated, whereas in the other two patients there was an obvious dense adherence between the vessel and the nerve, consistent with fibrosis. Intra-operative nerve testing prior to decompression corroborated pre-operative findings. In all three patients attempts to stimulate the phrenic nerve above the site of vascular compression failed to elicit a diaphragmatic response, whereas a response was recorded with stimulation distal to the compression. Following nerve decompression, stimulation of the phrenic nerve all along its course in the neck resulted in a diaphragmatic response at physiologic thresholds (0.5–1.0 mA) (see Fig. 2).

All patients provided subjective reports of improvements in their respiratory function within the first 48 h after surgery. Specifically, they noticed being able to take deeper breaths, and were able



**Fig. 1.** The transverse cervical artery (TCA) is one of the branches arising from the thyrocervical trunk and coursing laterally in the lower neck. The TCA intersects the phrenic nerve at an almost 90° angle, and following trauma or iatrogenic injury there can be adherence between the two structures, resulting in a vascular compression neuropathy.



**Fig. 2.** Ligation of the TCA, along with a more extensive micro-neurolysis of the phrenic nerve, may reverse an ischemic neurapraxia and restore diaphragmatic function in patients with paralysis.

to lie supine without an exacerbation of symptoms. The one patient whose dyspnea manifested with a head turn, was now able to perform that maneuver without such symptoms occurring. At three months SNIFF tests and PFTs were performed, revealing motion of the previously paralyzed diaphragms and a normalization of the restrictive spirometry deficits, respectively. At six months, all patients reported a maintenance or improvement of early results, and they were all able to return to normal work duties. The patients requiring nocturnal CPAP were able to discontinue this therapy in the first three months after surgery. There were no early or late surgical complications.

#### 4. Discussion

Peripheral causes of diaphragm paralysis are most often due to a phrenic nerve injury in the neck, mediastinum, or chest, whereas spinal cord injury, brain tumor, and central hypoventilation syndrome are the likely central nervous system etiologies. Understanding the pathophysiology of phrenic nerve injury has been hypothesized, but rarely confirmed, because most affected patients are managed non-operatively. Alternatively, even in patients who have been treated with diaphragm plication there is usually no exposure or exploration at the site of nerve injury, thus it is rare for the underlying injury to be directly evaluated. There are few reports of immediate phrenic nerve repair in patients undergoing tumor ablation, or following chest trauma, in which documentation of nerve transection has occurred [16,17].

Our recent publication reviewed a small series of patients with diaphragm paralysis treated with nerve surgery techniques; documenting successful diaphragm re-innervation in 89% [15]. Exploration at the site of nerve injury provided an opportunity to better understand the pathophysiology of nerve injury in some of these cases. Peripheral nerve injuries involving the nerves of the upper and lower extremities have been thoroughly investigated and, contrary to phrenic nerve injuries, are better understood. Regardless of the mechanism of injury (i.e. transection, stretching, thermal, crush, compression), the result will be damage to one or more of the supporting nerve structures and/or axons that, if severe

enough, will result in Wallerian degeneration – the atrophy of the nerve structure distal to the site of injury. There are detailed nerve injury classifications by Seddon and Sunderland that help us understand the severity of the nerve injury, and also to prognosticate the chances of spontaneous recovery [18,19].

Post-procedural and post-surgical nerve injuries may be from direct nerve transection or stretching, or may be secondary to the fibrosis and scarring that occurs after such events. Loss of normal tissue planes and adherence between normally separate anatomical structures can lead to compression and nerve dysfunction. In the case of the phrenic nerve, its course in the neck, running in-line with the anterior scalene muscle and just under the prevertebral fascia, may predispose it to compression injuries following neck interventions. We theorize that trauma or manipulation in the neck may result in scalene muscle induration, sometimes in association with an intra-muscular hematoma, causing compression of the phrenic nerve where it is interposed between the muscle and the semi-rigid prevertebral fascia.

The TCA, a branch of the thyrocervical trunk arising from the subclavian artery, crosses the phrenic nerve approximately 3 cm above the clavicle, however is anatomically separate from the nerve by the well-defined prevertebral fascia. Following intervention in the neck, it is very conceivable that a change or disruption in the normal quality of the prevertebral fascia may result in adherence between the two structures. The course and caliber of the TCA may also be altered in a way that causes greater compression of the underlying phrenic nerve. Although a vascular nerve compression may result in either an ischemic or demyelinating neurapraxia, early reversibility of the paralysis following treatment in our three cases supports the former as the underlying pathologic mechanism.

Vascular compression of a central or peripheral nerve has been well described in various locations throughout the body. Examples of such syndromes include: vertebral artery compression of a cervical root, arterial compression of the intra-cranial trigeminal nerve, thoracic outlet syndrome, vascular compression of the vestibulocochlear nerve, radial nerve palsy secondary to the vascular leash of Henry, Ortner's syndrome (vascular compression of the recurrent laryngeal nerve), and vascular compression of the occipital nerve causing migraine headaches [20–25]. In particular, radial nerve palsy secondary to a thickened recurrent radial artery (vascular leash of Henry) may occur in a similar manner to our proposed syndrome in that, preceding trauma or inflammation alters the caliber or course of the blood vessel and/or spatial relationship between it and the involved nerve.

Unfortunately, it is unlikely that even the most astute clinician would be able to definitively determine vascular compression to be the cause of a patient's diaphragm paralysis. Perhaps a high index of suspicion for such a syndrome could be elicited in a patient whose dyspnea symptoms are exacerbated with head turning, however there is no way to corroborate this with radiographic findings. Unlike thoracic outlet syndrome, in which a contrast-enhanced MRI may sometimes visualize vascular compression of the brachial plexus in association with a positive Adson's maneuver, the TCA and phrenic nerve are not well visualized, even with the most sophisticated of imaging studies. "Red Cross syndrome" may accurately depict the visualized course of the TCA over the phrenic nerve at an almost perfect 90° angle; however this diagnosis is one that will almost always be made intra-operatively until there are significant advances in our ability to image small caliber nervous and vascular structures. Transcutaneous stimulation of the phrenic nerve with a nerve conduction probe, in conjunction with chest fluoroscopy, can identify a delay in conduction velocity that supports a diagnosis of compression neuropathy, however the location and source of compression often cannot be precisely determined.

More importantly, clinicians evaluating patients with symptomatic diaphragm paralysis should be aware that there are

reversible conditions such as vascular compression, and patients should be informed that treatments for these conditions do exist. A reversible compression neuropathy of the phrenic nerve is a diagnosis suggested by characteristic findings on phrenic nerve NCS and diaphragm EMG, along with a supportive clinical history. Vascular compression is just one of the mechanisms by which the phrenic nerve can be reversibly, or irreversibly, compressed, yet peripheral nerve surgeons have well-established surgical methods for dealing with whatever condition presents itself as the underlying pathophysiology.

## 5. Conclusion

Little is known about the pathophysiology of phrenic nerve injuries, especially since treatment options have traditionally been limited. Recent advances in surgical therapy have allowed us to begin to identify underlying pathophysiology. We present three patients whose diaphragm paralysis was ultimately caused by a reversible vascular compression from a tortuous or adherent TCA. Increased awareness of conditions, such as Red Cross syndrome, will allow clinicians to better understand the causes of diaphragm paralysis, and hopefully result in greater numbers of patients finding successful treatments for this ailment.

## References

- [1] DeVita MA, Robinson LR, Rehder J, Hattker B, Cohen C. Incidence and natural history of phrenic neuropathy occurring during open heart surgery. *Chest* 1993;103:850–6.
- [2] Canbaz S, Turgut N, Halici U, Balci K, Ege T, Duran E. Electrophysiological evaluation of phrenic nerve injury during cardiac surgery—a prospective, controlled, clinical study. *BMC Surgery* 2004;4:2–7.
- [3] Tripp HF, Bolton JW. Phrenic nerve injury following cardiac surgery: a review. *J Cardiac Surg* 1998;13:218–23.
- [4] Curtis JJ, Nawarawong W, Walls JT, et al. Elevated hemidiaphragm after cardiac operation: incidence, prognosis and relationships to the use of topical ice slush. *Ann Thorac Surg* 1989;48:764–8.
- [5] Lemmer J, Stiller B, Heise G, et al. Postoperative phrenic nerve palsy: early clinical implications and management. *Intens Care Med* 2006;32(8):1227–33.
- [6] Cargiani LH, Rezende LA, Giancoli Neto A. Phrenic nerve block after interscalene brachial plexus block. Case report. *Revista Brasileira de Anestesiologia* 2008;58(2):152–9.
- [7] Kessler J, Schafhalter, Zappoth I, Gray AT. An ultrasound study of the interscalene brachial plexus block. *Region Anesth Pain Med* 2008;33(6):545–50.
- [8] Schram DJ, Vosik W, Cantral D. Diaphragmatic paralysis following cervical chiropractic manipulation. *Chest* 2001;119:638–9.
- [9] Franko OI, Khalpey Z, Gates J. Brachial plexus trauma: the morbidity of hemidiaphragmatic paralysis. *Emerg Med J* 2008;25(9):614–5.
- [10] Gautier G, Verschueren A, Monnier A, Attarian S, Salort-Campana E, Pouget J. ALS with respiratory onset: clinical features and effects of non-invasive ventilation on the prognosis. *Amyotroph Lateral Scler* 2010;11(4):379–82.
- [11] Wokke JH, Escolar DM, Pestronk A, Jaffe KM, Carter GT, van den Berg LH, Florence JM, Mayhew J, Skrinar A, Corzo D, Laforet P. Clinical features of late-onset Pompe disease: a prospective cohort study. *Muscle Nerve* 2008;38(4):1236–45.
- [12] Tang EW, Jardine DL, Rodins K, Evans J. Respiratory failure secondary to diabetic neuropathy affecting the phrenic nerve. *Diabet Med* 2000;20(7):599–601.
- [13] Odell JA, Kennelly K, Stauffer J. Phrenic nerve palsy and Parsonage-Turner syndrome. *Ann Thorac Surg* 2011;92(1):349–51.
- [14] Crausman RS, Summerhill EM, McCool FD. Idiopathic diaphragmatic paralysis: Bell's palsy of the diaphragm? *Lung* 2009;187(3):153–7 [Epub 2009 March 10].
- [15] Kaufman MR, Elkwood AI, Rose MI, Patel T, Ashinoff R, Saad A, et al. Re-innervation of the paralyzed diaphragm: application of nerve surgery techniques following unilateral phrenic nerve injury. *Chest* 2011;140(1):191–7.
- [16] Schoeller T, Ohlbauer M, Wechselberger G, Piza-Katzer H, Margreiter R. Successful immediate phrenic nerve reconstruction during mediastinal tumor resection. *J Thorac Cardiovasc Surg* 2001;122:1235–7.
- [17] Brouillette RT, Hahn YS, Noah LZ, Ilbawi MN, Wessel HU. Successful reinnervation of the diaphragm after phrenic nerve transection. *J Pediatr Surg* 1986;21:63–5.
- [18] Seddon JH. Three types of nerve injury. *Brain* 1943;66:237–88.
- [19] Sunderland S. A classification of peripheral nerve injuries producing loss of function. *Brain* 1951;74(4):491–516.
- [20] Fink JR, Leung JY, Creutzfeldt CJ. Vertebral artery loop formation causing severe cervical nerve root compression. *Neurology* 2010;75(2):192.
- [21] Kopp R, Linn J, Stelter K, Weidenhagen R, Meimarakis G, Berndt J. Hybrid operation for a distal aortic arch aneurysm causing left recurrent nerve palsy – Ortner's syndrome [Article in German]. *Laryngorhinootologie* 2008;87(10):723–7 [Epub 2008 April 17].
- [22] Wuertenberger CJ, Rosahl SK. Vertigo and tinnitus caused by vascular compression of the vestibulocochlear nerve, not intracanalicular vestibular schwannoma: review and case presentation. *Skull Base* 2009;19(6):417–24.
- [23] Johnson RD, Mitchell R, Maartens N. Trigeminal neuralgia due to severe vascular compression of the trigeminal nerve. *Anz J Surg* 2011;81(4):289–90.
- [24] Janis JE, Hatfeg DA, Reece EM, McCluskey PD, Schaub TA, Guyuron B. Neurovascular compression of the greater occipital nerve: implications for migraine headaches. *Plast Reconstr Surg* 2010;126(6):1996–2001.
- [25] Loizides A, Peer S, Ostermann S, Henninger B, Stampfer-Kountchev M, Gruber H. Unusual functional compression of the deep branch of the radial nerve by a vascular branch (leash of Henry): ultrasonographic appearance. *Rofa* 2011;183(2):163–6 [Epub 2010 October 11].