

## DERMATOPATHOLOGY GROSSING GUIDELINES

### RUSH CASES:

**For all RUSH cases, the dermpath fellows AND the skin service resident should be notified via email about the case.**

**Specimen Type:** SKIN SHAVE BIOPSY

### **Gross Template:**

#### **MMODAL COMMAND: "INSERT SHAVE"**

The specimen is received in one formalin filled container, labeled with patient's name ([*last name, first name*\*\*\*]), medical record number ([*insert MRN*\*\*\*]), and designated as "[*Dictate full description listed in Beaker. Ensure that the specimen label matches the Beaker order*\*\*\*]". It consists of a [*measure in three dimensions*\*\*\*] skin shave biopsy. The epidermis is [*describe lesion and give greatest dimension/discoloration/unremarkable*\*\*\*]. The specimen is [*bisected/trisected/serially sectioned*\*\*\*] and entirely submitted, in a mesh bag, in [*describe cassette submission*\*\*\*].

[*Insert grosser's initials and todays date (SM 01/01/2000)*\*\*\*]

#### **MMODAL COMMAND: "INSERT SHAVE TWO"**

The specimen is received in two formalin-filled containers, each labeled with patient's name ([*last name, first name*\*\*\*]), medical record number ([*insert MRN*\*\*\*]), and associated designations.

Part A, is designated as "[*Dictate full description listed in Beaker. Ensure that the specimen label matches the Beaker order*\*\*\*]". It consists of a [*measure in three dimensions*\*\*\*] skin shave biopsy. The epidermis is [*describe lesion and give greatest dimension/discoloration/unremarkable*\*\*\*]. The specimen is [*bisected/trisected/serially sectioned*\*\*\*] and entirely submitted, in a mesh bag, in A1.

Part B, is designated as "[*Dictate full description listed in Beaker. Ensure that the specimen label matches the Beaker order*\*\*\*]". It consists of a [*measure in three dimensions*\*\*\*] skin shave biopsy. The epidermis is [*describe lesion and give greatest dimension/discoloration/unremarkable*\*\*\*]. The specimen is [*bisected/trisected/serially sectioned*\*\*\*] and entirely submitted, in a mesh bag, in B1.

[*Insert grosser's initials and todays date (SM 01/01/2000)*\*\*\*]

#### **MMODAL COMMAND: "INSERT SHAVE THREE"**

The specimen is received in three formalin-filled containers, each labeled with patient's name ([*last name, first name*\*\*\*]), medical record number ([*insert MRN*\*\*\*]), and associated designations.

Part A, is designated as "[*Dictate full description listed in Beaker. Ensure that the specimen label matches the Beaker order*\*\*\*]". It consists of a [*measure in three dimensions*\*\*\*] skin shave biopsy. The epidermis is [*describe lesion and give greatest dimension/discoloration/unremarkable*\*\*\*]. The specimen is [*bisected/trisected/serially sectioned*\*\*\*] and entirely submitted, in a mesh bag, in A1.

Part B, is designated as "[*Dictate full description listed in Beaker. Ensure that the specimen label matches the Beaker order*\*\*\*]". It consists of a [*measure in three dimensions*\*\*\*] skin shave biopsy. The epidermis is [*describe lesion and give greatest dimension/discoloration/unremarkable*\*\*\*]. The specimen is [*bisected/trisected/serially sectioned*\*\*\*] and entirely submitted, in a mesh bag, in B1.

Part C, is designated as "[*Dictate full description listed in Beaker. Ensure that the specimen label matches the Beaker order*\*\*\*]". It consists of a [*measure in three dimensions*\*\*\*] skin shave biopsy. The epidermis

## DERMATOPATHOLOGY GROSSING GUIDELINES

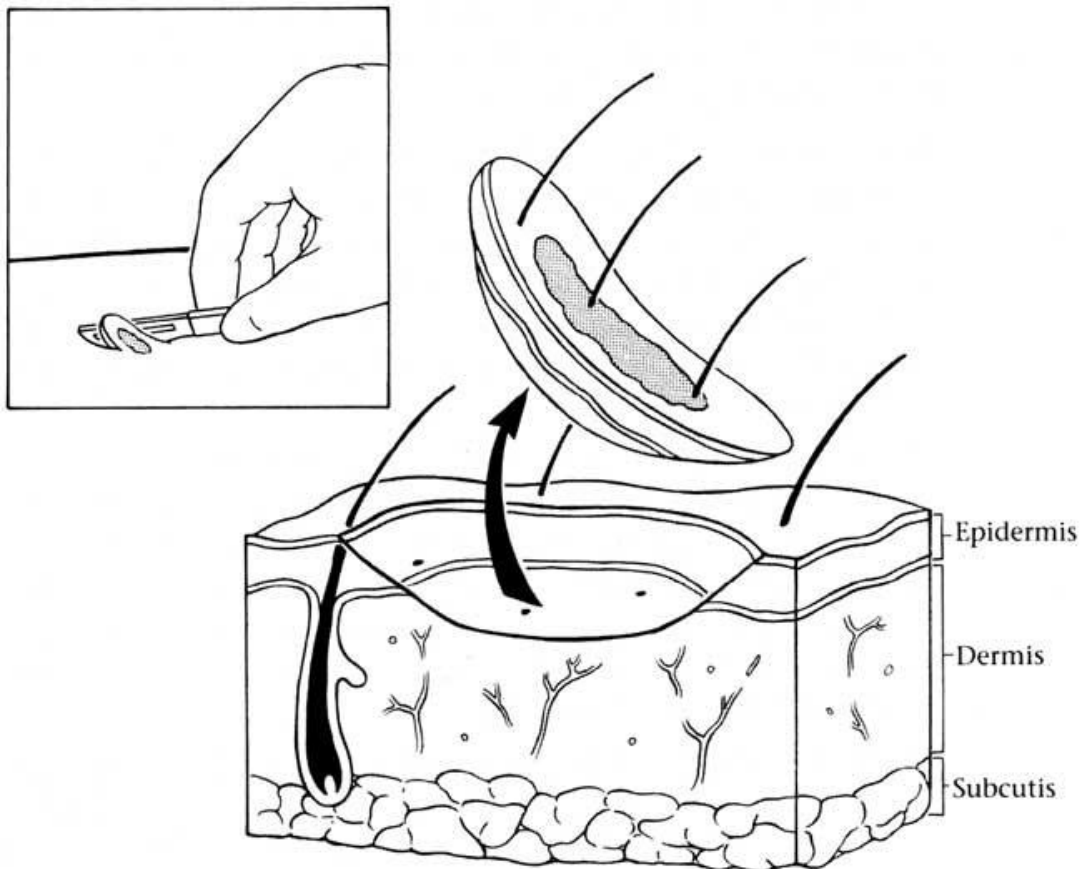
is [describe lesion and give greatest dimension/discoloration/unremarkable\*\*\*]. The specimen is [bisected/trisected/serially sectioned\*\*\*] and entirely submitted, in a mesh bag, in C1.

[Insert grosser's initials and today's date (SM 01/01/2000)\*\*\*]

**Note:** There is often no need to ink the deep surface of skin as shaves are not removed for margin assessment. If you do ink the skin shave, choose **green ink**. Try to avoid black ink as this makes diagnosing melanoma difficult.

**Cassette Submission:** All tissue submitted

- Shave biopsies 3 mm or less are submitted in their entirety
- Shave biopsies  $\geq 4$  mm are bisected/trisected (depending on size)



Wendolyn Hill