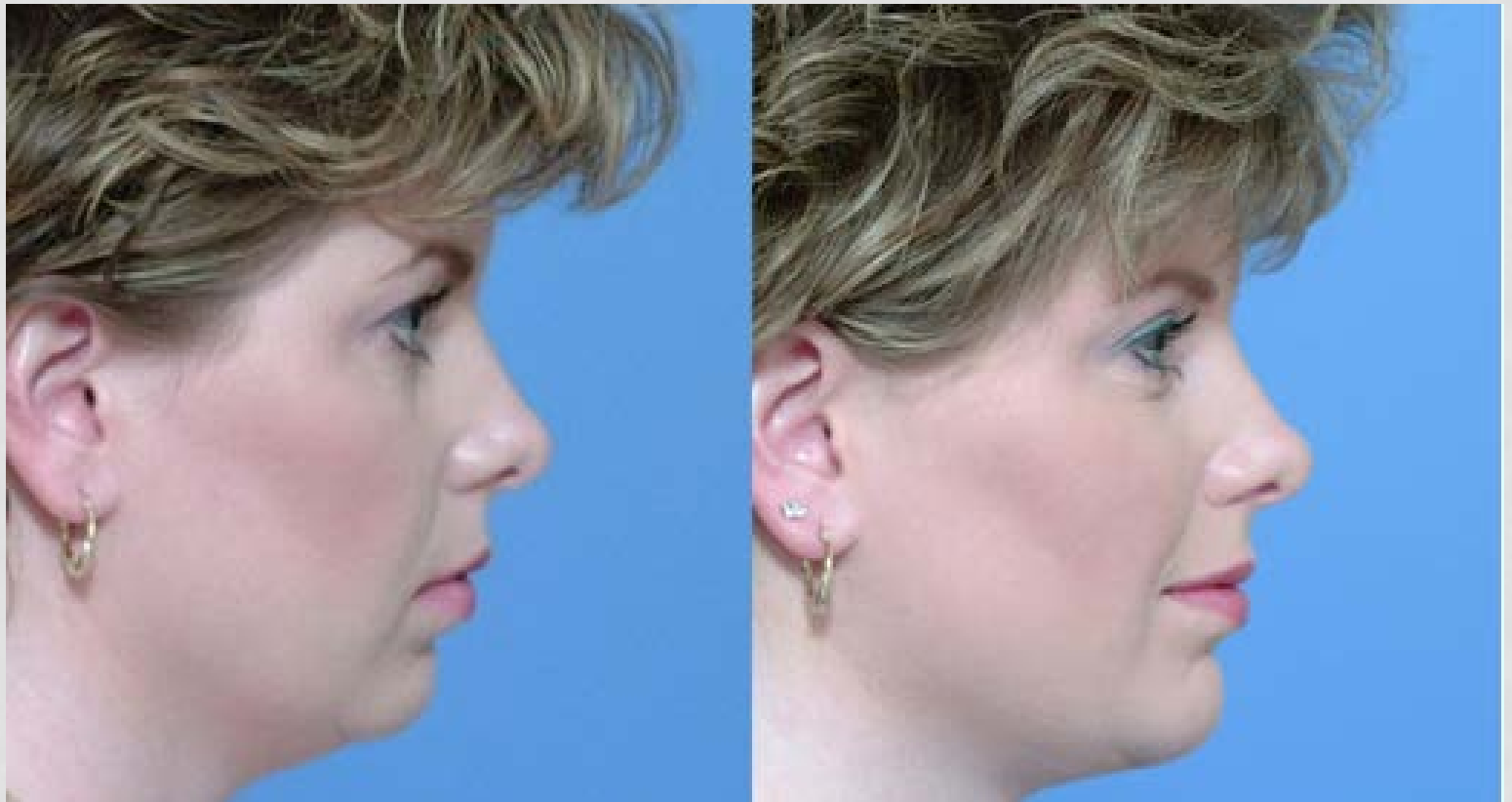

CHIN AND MALAR AUGMENTATION

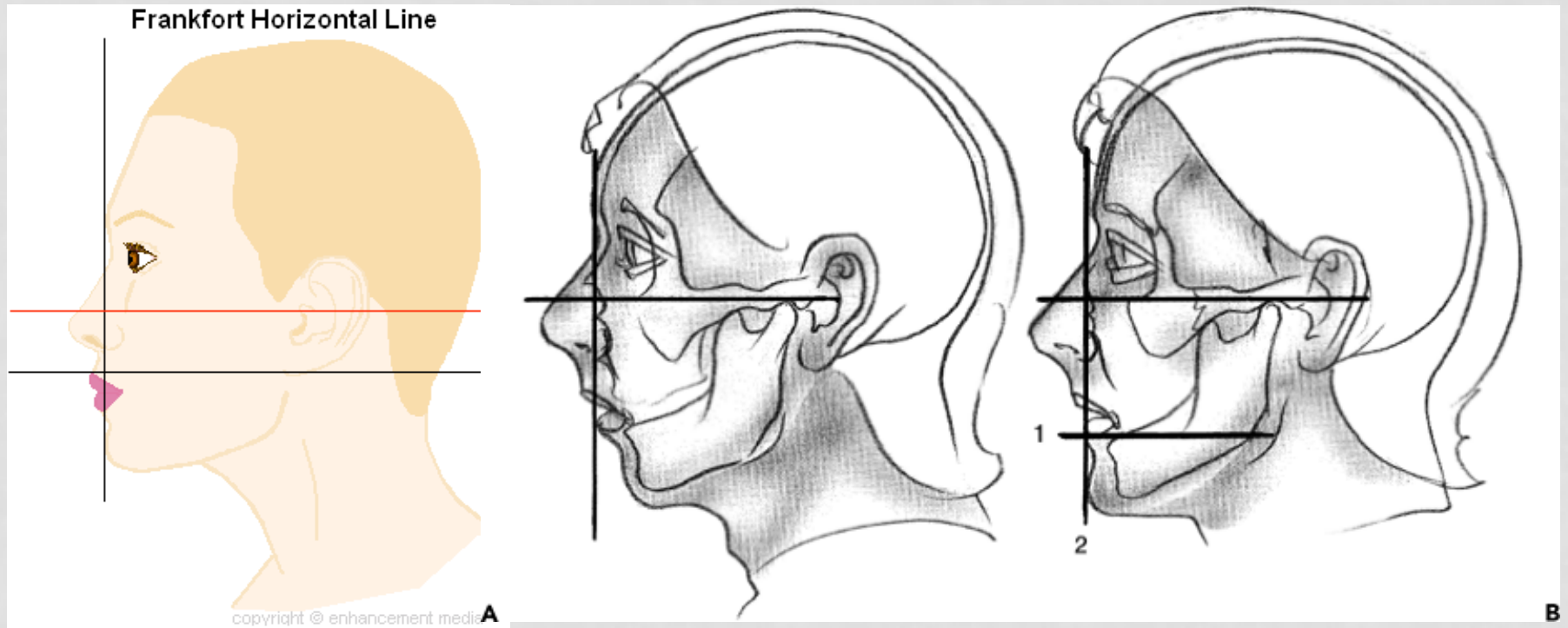
SOROUGH ZAGHI, MD



INTRODUCTION

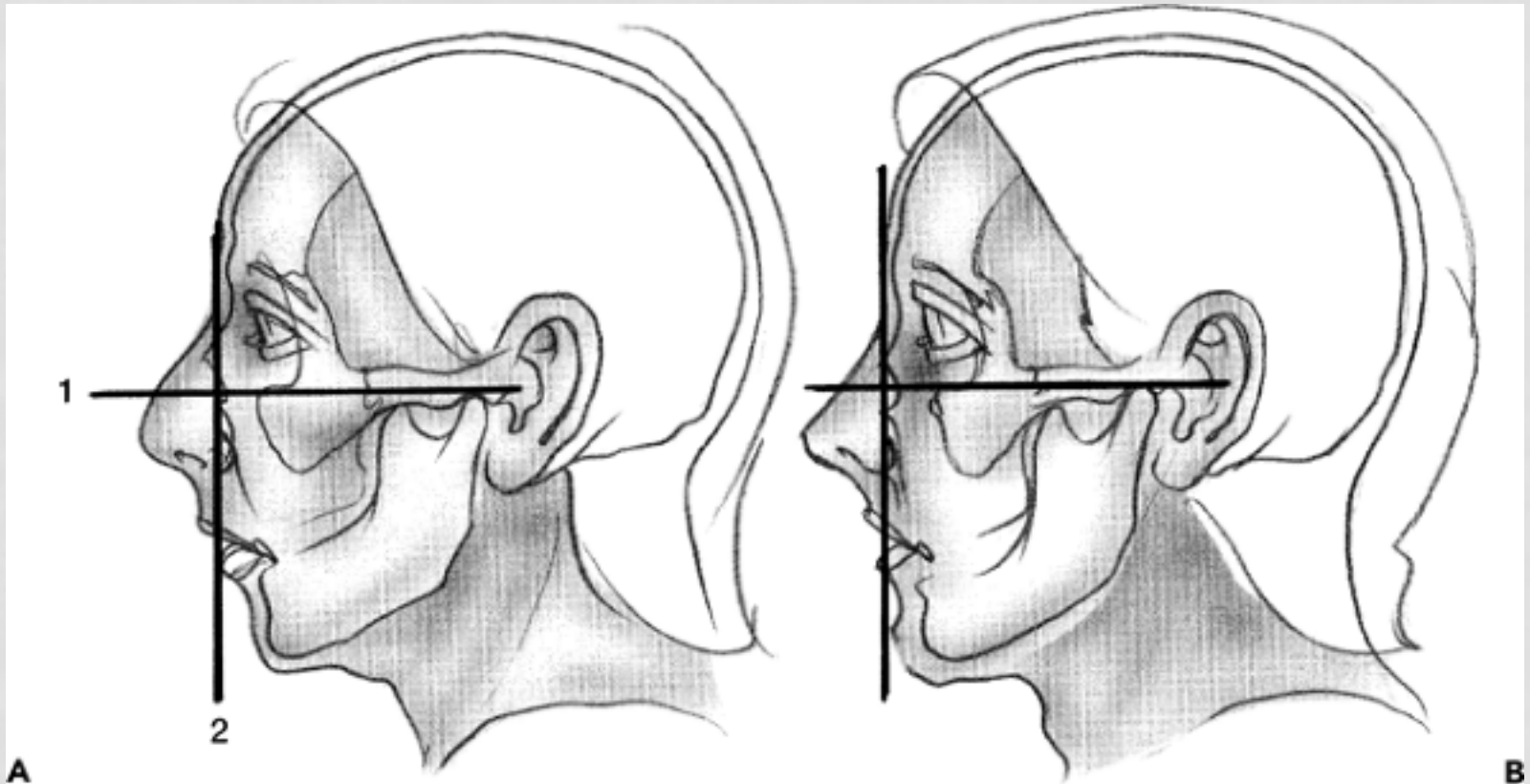


EVALUATION OF CHIN PROJECTION



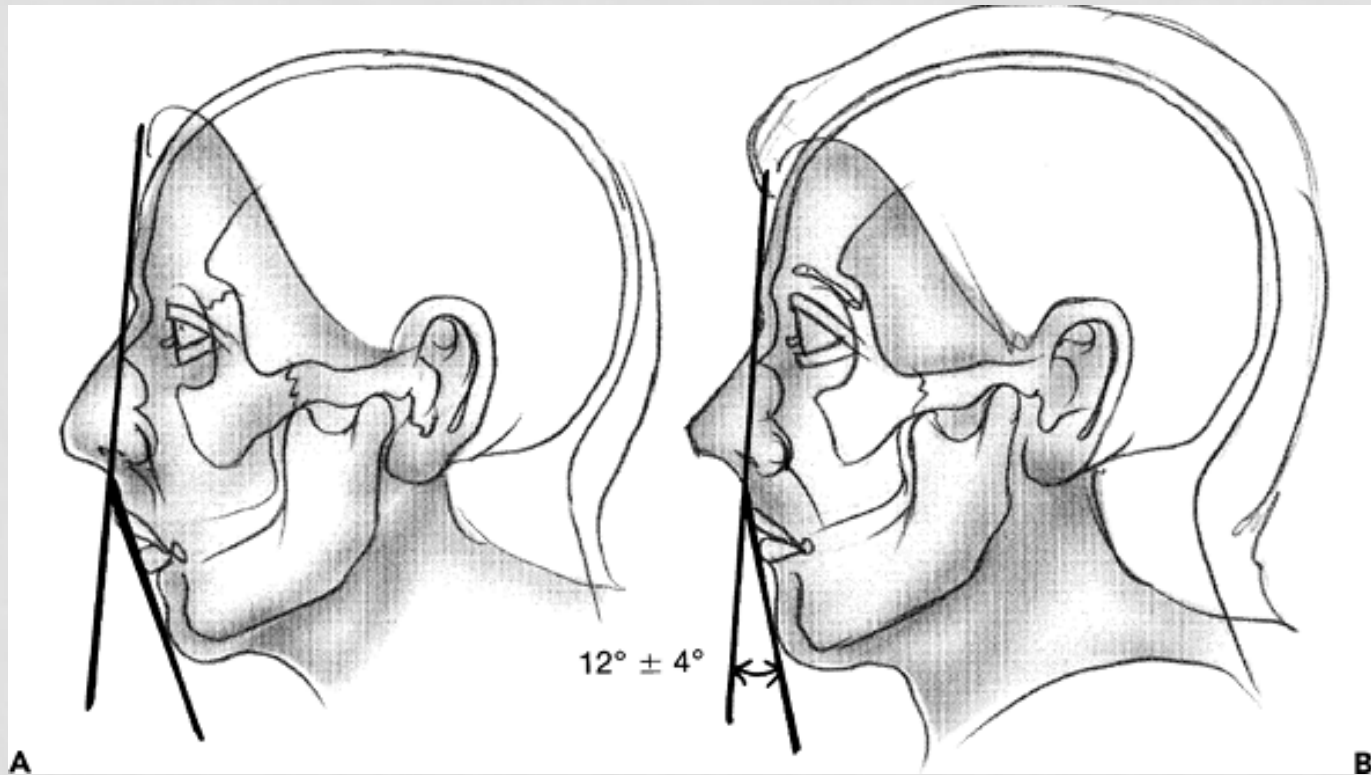
Chin projection should approach a line perpendicular to the Frankfurt horizontal at vermilion border of lower lip.

ZERO MERIDIAN OF GONZALES-ULLOA



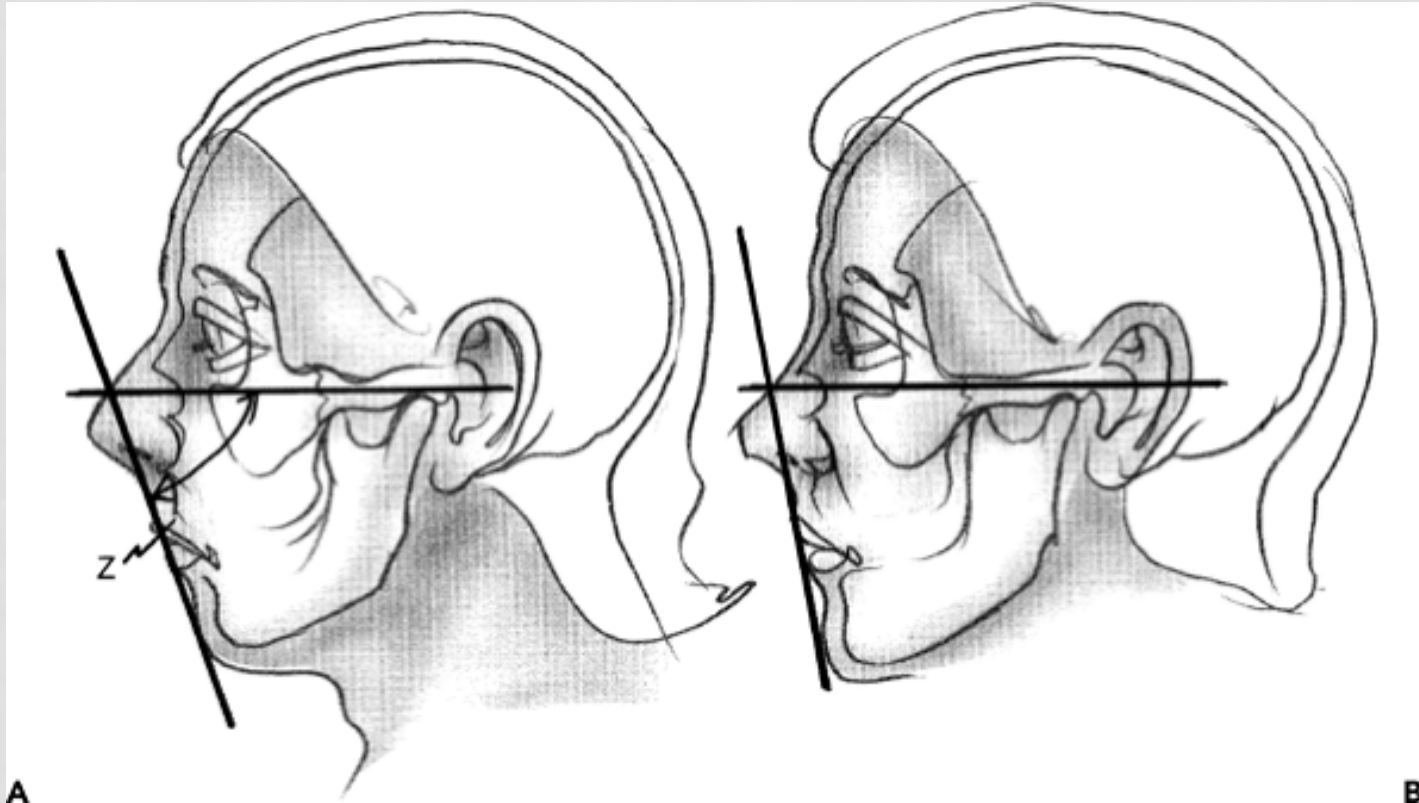
A line perpendicular to the Frankfort horizontal line is projected through the nasion.

Legan's angle



Contained by lines from the glabella to the subnasale and the subnasale to the soft-tissue pogonion. This should be 12 ± 4 degrees for appropriate chin projection.

MERRIFIELD Z ANGLE



Contained by the Frankfort horizontal line and a line connecting the soft-tissue pogonion to the most anterior part of the lip. The Z angle should be 80 ± 5 degrees.

PRE-OPERATIVE CONSIDERATIONS

- Skin texture
- Anatomic proportions
- Prior facial trauma
- Emotional stability
- Aging face: Soft tissue ptosis, jowls, Marionette lines
- Occlusal relationship: Microgenia, Micrognathia, Retrognathia.

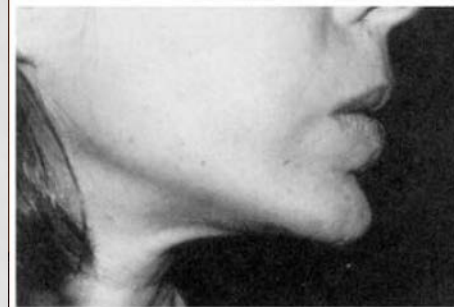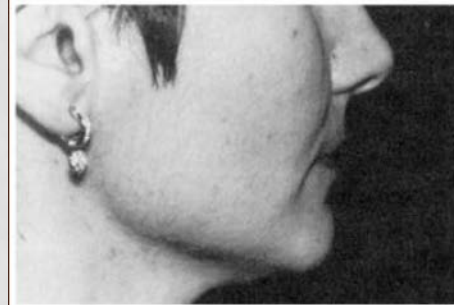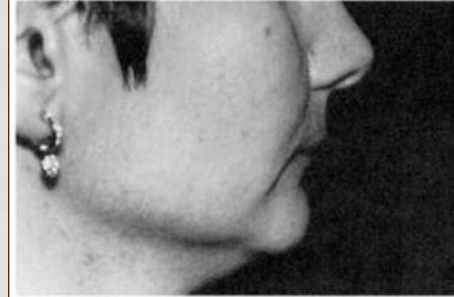PATIENT WITH JOWLS



- 35 F – Before and 4 months after chin implant with liposuction from jowls and submental area.

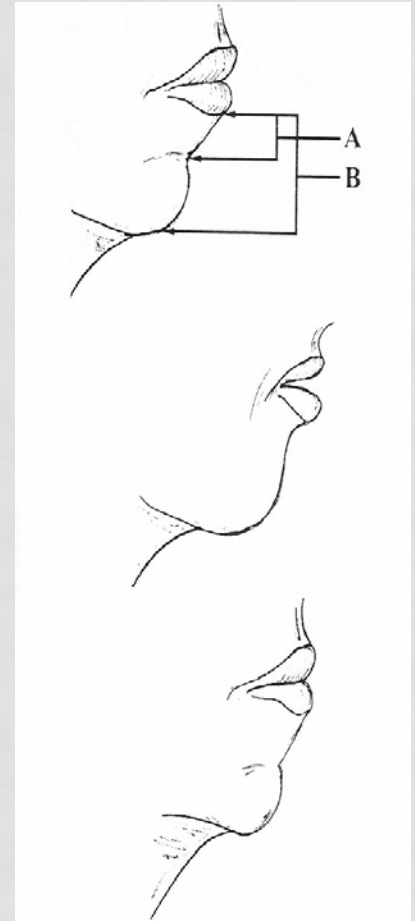PATIENT WITH RETROGNATHIA

- Patient with retrognathia, voluntary protrusion of jaw (better candidate for mandibular advancement)
- Patient with retrognathia and chin implant (deepened labiomental fold).



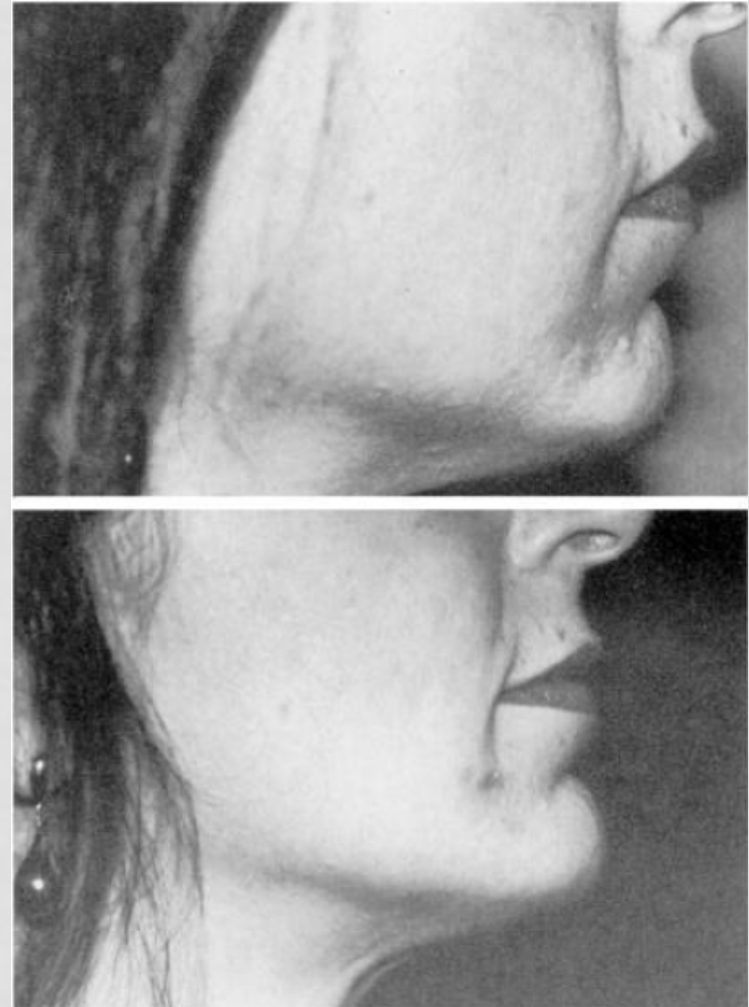
Lower lip analysis- Labiomental fold

- Position of the labiomentental fold determines the chin pad percentage of the lower facial height.
- High labiomentental fold → Poor candidate.
Augmentation will enlarge the entire lower face.
- Low labiomentental fold → Good candidate.
Augmentation will accentuate the chin only.



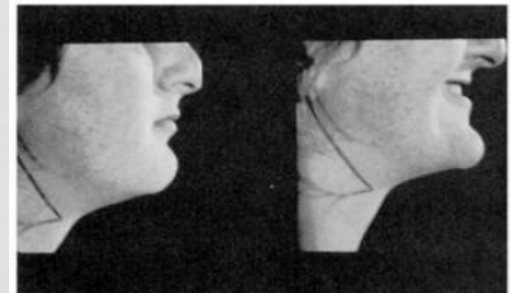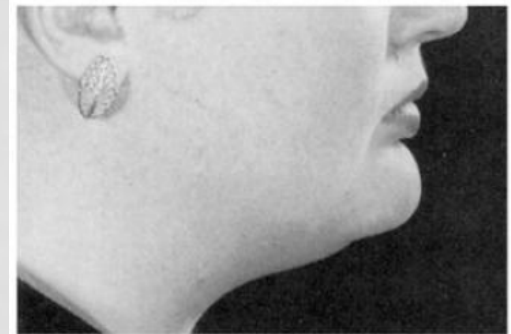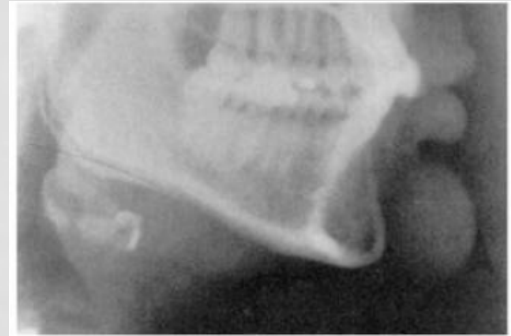LOW LABIOMENTAL FOLD

- Patient with low labiomenal fold
- Before and after chin augmentation.



CHIN PAD THICKNESS

- Soft tissue thickness: normal= 8 to 11 mm.
- Cephalogram demonstrating a very thick chin pad.
- Avoid setting back jaws with thick pads; leads to bony irregularities, soft tissue pad ptosis and an unsupported chin pad.
- Patient with thin chin pad but prominent bony chin → May benefit from deprojection by removal of bony.



TREATMENT OF CHIN DEFICIENCIES

- **Alloplasts vs. sliding genioplasty**

Alloplasts: simpler, removable, fewer complications

- **Sliding genioplasty:** useful in asymmetric jaws and extreme microgenia.

CONTRAINDICATIONS TO CHIN IMPLANTS

- Severe periodontal disease
- Extreme microgenia
- Excess or insufficient vertical mandibular height
- Labial incompetence with chin dimpling and strain


BIOMATERIALS FOR IMPLANTS

- Silicone implants-
 - soft or firm available
 - easily inserted
 - Inert, capsule formation
 - bony absorption

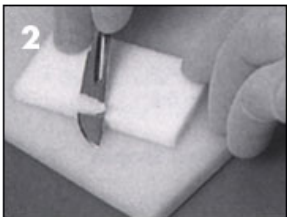


- ePTFE = expanded Polytetrafluoroethylene ~ Gore-tex
 - easily inserted, micropores to allow some tissue ingrowth, no capsule.
- Porous Polyethylene ~ MedPor
 - Non-absorbable polyester fiber sheet with large pores that allow much tissue ingrowth
 - - requires crafting and more technical expertise.

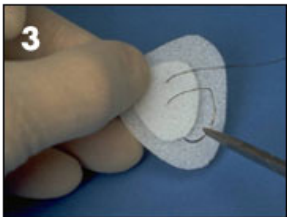
MEDPOR



Sheets and blocks trim easily with surgical scissors or a small scalpel blade.



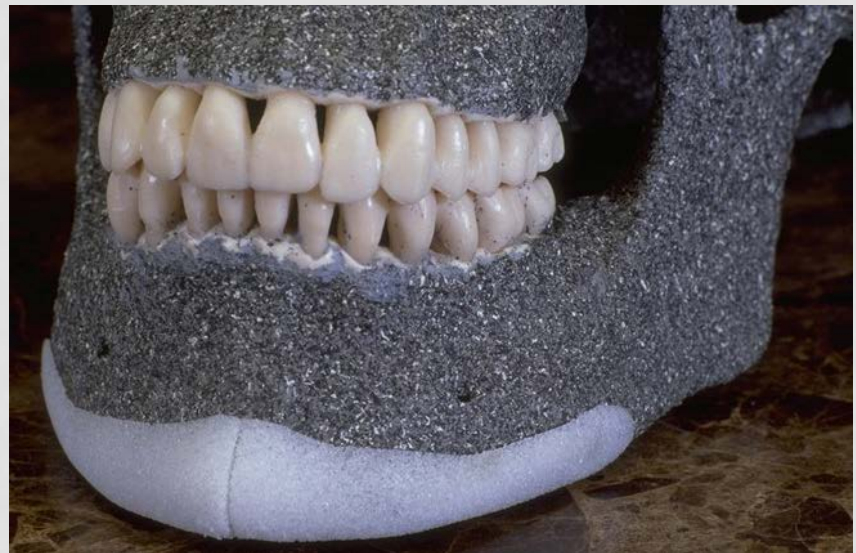
Thicker implants may be shaped with large scalpels, bone cutters or a cutting burr.



Multiple pieces of implant material may be stacked and sutured together.



Proper rigid fixation techniques allow for stabilization of the implant.



IMPLANT SIZES

- Actual soft-tissue augmentation stabilizes in 2 years at 70% of implant thickness.
- 10-mm implant would yield a 7-mm soft-tissue increase.
- The gain is reduced because of a small amount of implant settling, bone resorption, and soft-tissue compression.
- Always safer to underaugment slightly to avoid deformity.

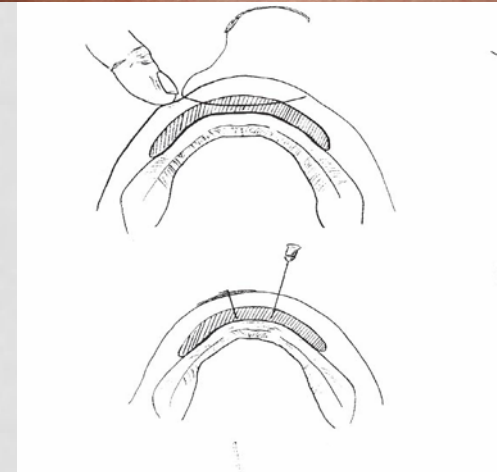
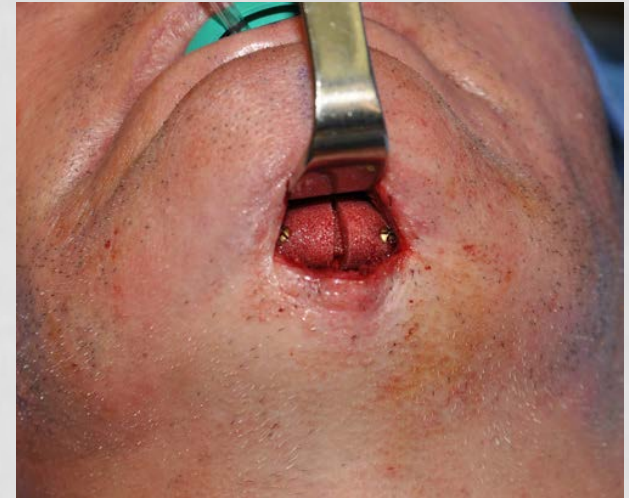SURGICAL TECHNIQUE

- **Extraoral alloplast placement**
 - + 10-15 mm incision at submental crease
 - + allows implant to be sutured stabilized to the periosteum
 - - External scar
- **Intraoral alloplast placement**
 - + No external scars
 - - larger incision line
 - - Intraoral contamination
 - - Suture-line irritation
 - - Anterior geniobuccal sulcus scar contracture
 - - inability to stabilize the implant internally
 - - potential for labial incompetence if the mentalis muscle is disrupted.

-

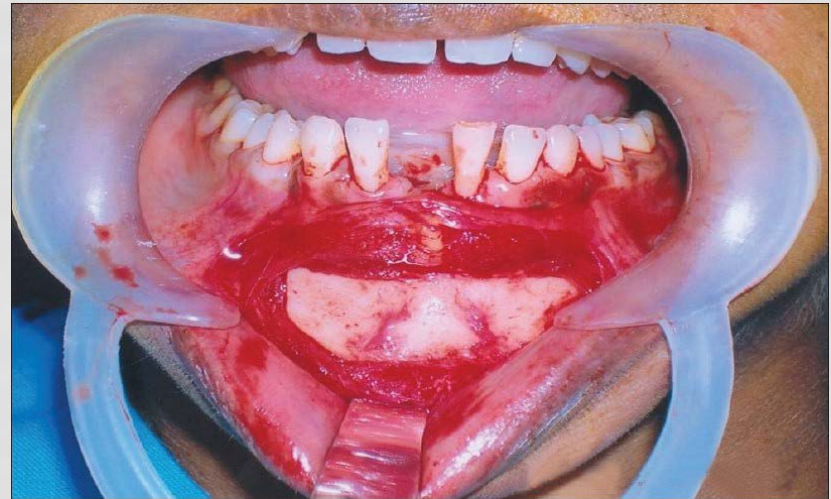OPERATIVE PROCEDURE

- External Approach:
 - 10-15 mm incision at submental crease
 - Deepened through the SC fat and muscle layer down to periosteum
 - Periosteum is sharply cut and elevated superiorly.
 - Implant is inserted into the subperiosteal pocket
 - Placement on the pogonion
 - Center the implant
 - Periosteum is closed with 3-0 chromic; then skin closure.
 - Pressure dressing for days.



INTRAORAL APPROACH

- Vertical incision is made through the anterior gingivobuccal frenulum
 - Incision is carried through the muscle down to the periosteum
 - Periosteum is sharply cut and elevated superiorly.
- Implant is inserted into the subperiosteal pocket
 - Placement on the pogonion
 - Center the implant
- Close periosteum, muscle, mucosa with 3-0 chromic.
 - Pressure dressing for days.



COMPLICATIONS OF CHIN IMPLANTS

Risks

- Displaced implant
- Infection or tissue reaction
- Bony resorption
- Improper size selection
- Mental nerve injury
- Hypertrophic scar

Tips

- Preoperative antibiotics
- Washing implants and gloves of all powder or oils
- Making the superiosteal pocket only as big as necessary to accept the implant
- Suturing the implant to the periosteum
- Selecting the implant size carefully

MALPOSITIONED IMPLANT

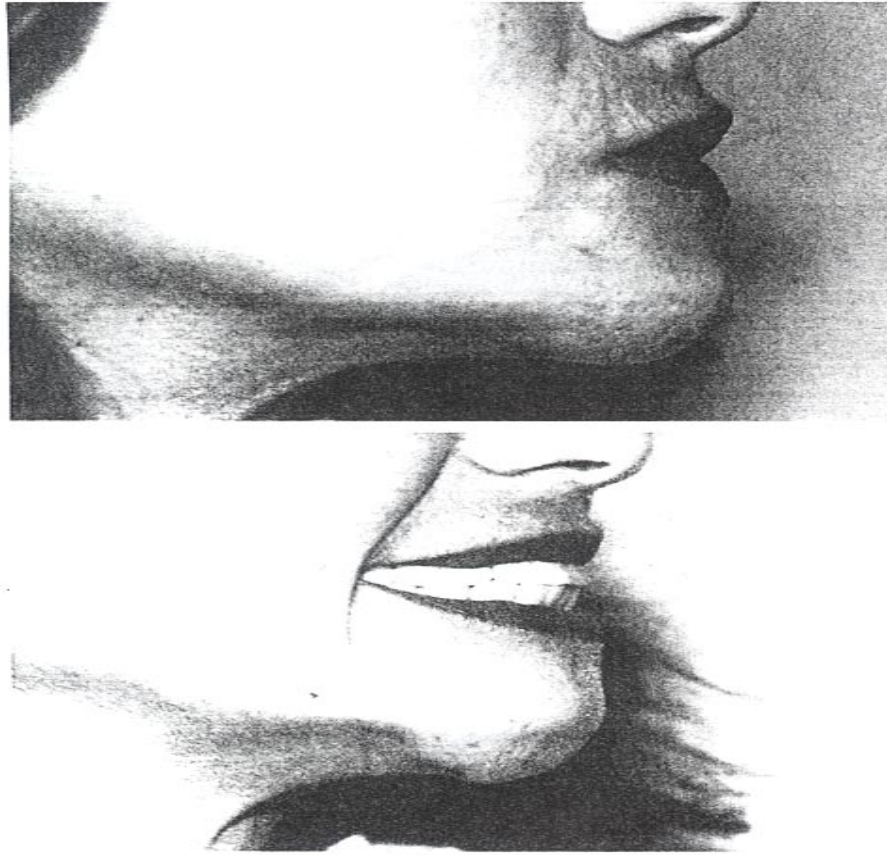


FIG. 14. Photographs of malpositioned chin implant. (*Above*) Right lateral photograph of patient in repose. (*Below*) Lateral photograph demonstrating increased visibility of implant (placed too high) when smiling. This emphasizes the need for a preoperative dynamic examination of the chin.

LIP NUMBNESS

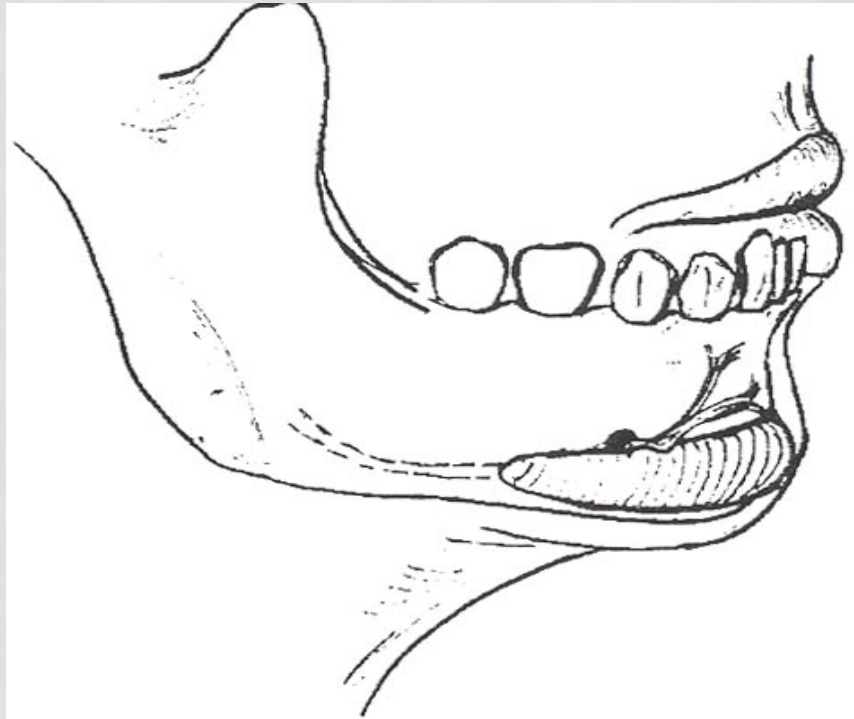


FIG. 18. Line drawing demonstrating a situation in which the mental foramen may be below the chin implant or the implant may be placed too high. Leaving the implant in place when it impinges on the mental foramen will result in lower lip numbness.

POSTOPERATIVE RESULT

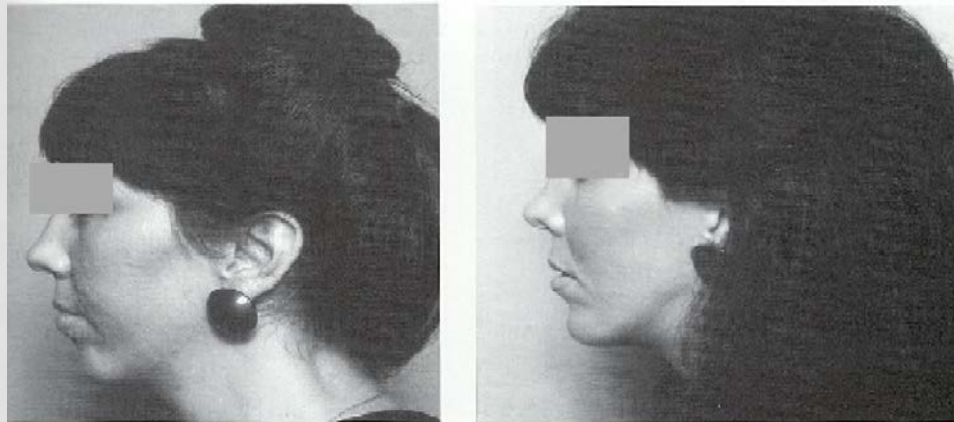


FIG. 186-10. This patient had a facelift, rhinoplasty, chin augmentation, and malar implants. **A:** Preoperative view; patient with flattened malar prominence and receding chin. **B:** Postoperative view; facelift with chin implant and cheek implant. Notice the malar prominence and strong chin with shallow mento-labial fold. (See Color Plates 186-10A and B.)

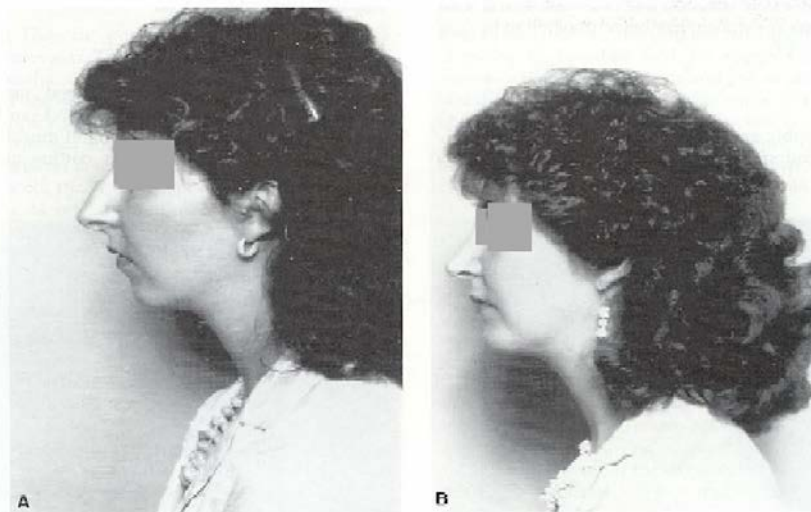


FIG. 186-11. This patient had chin augmentation and rhinoplasty. **A:** Preoperative view; patient with a nasal dorsal hump and a hypoplastic mandible. **B:** Postoperative view; rhinoplasty with chin implant.

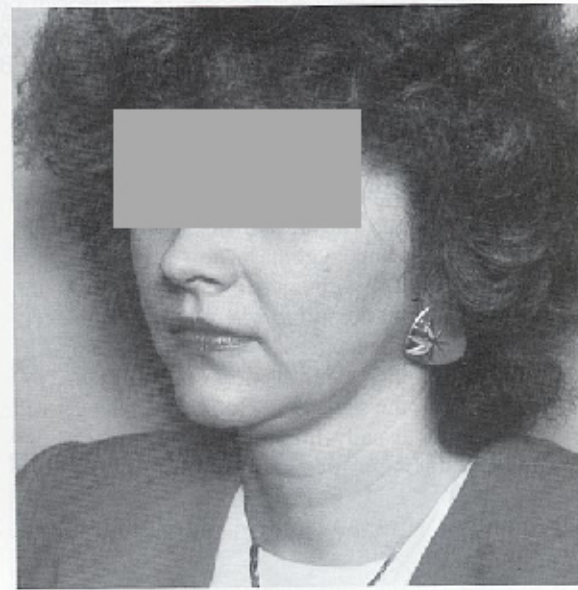
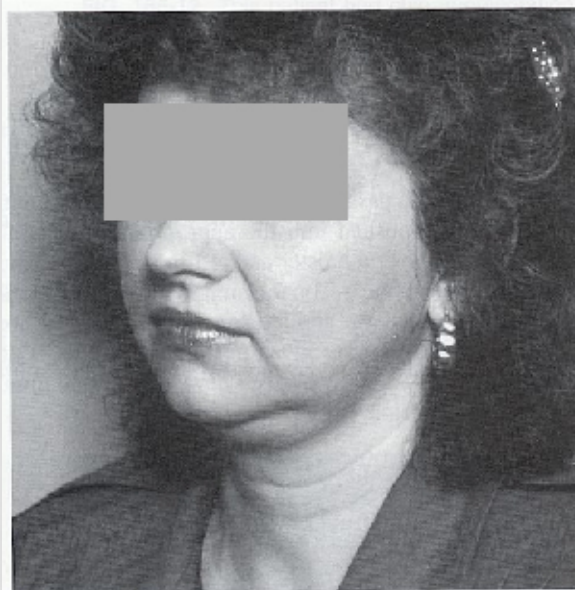
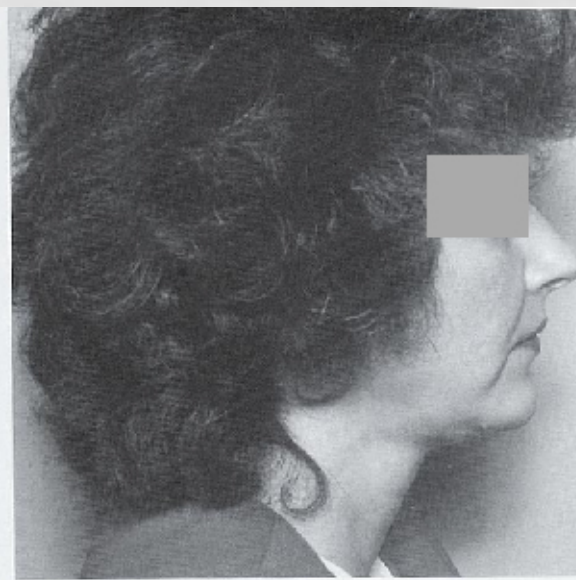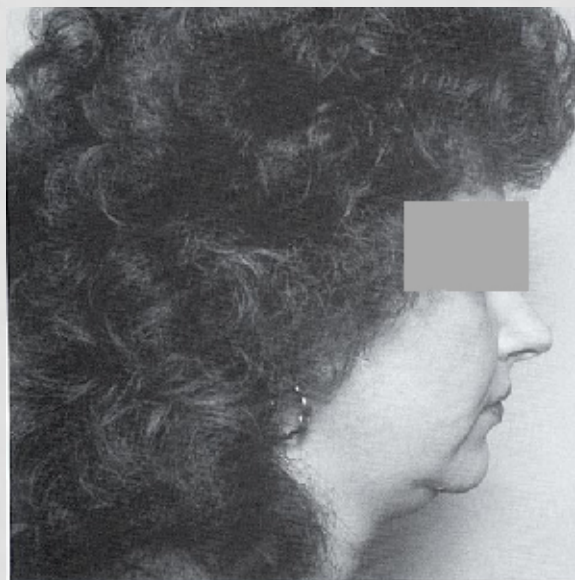FIG. 186-15. Chin augmentation and lipectomy. **A, C:** Preoperative views: hypoplastic mandible and fullness of fatty tissue in submental area. **B, D:** Postoperative views: liposuction and insertion of chin implant. Notice the more acute cervical mental angle.

SLIDING GENIOPLASTY

- Indications

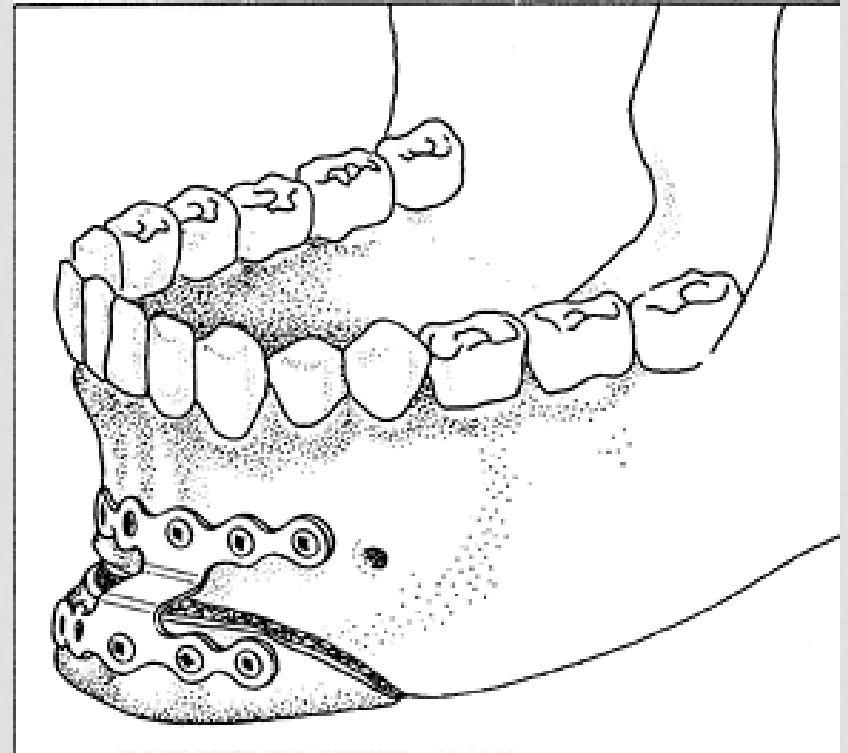
- To decrease or increase the vertical height of the chin in patients with excess or insufficient vertical mandibular height
- Extreme microgenia, hemifacial atrophy or mandibular asymmetry
- Failed alloplastic chin augmentation.

- Disadvantages

- Increased surgical time,
- Longer healing time,
- Risk of injury to anterior teeth, mucous membranes
- Risk to lose lip competence (if poor reapproximation of the mentalis muscle).

SLIDING GENOPLASTY

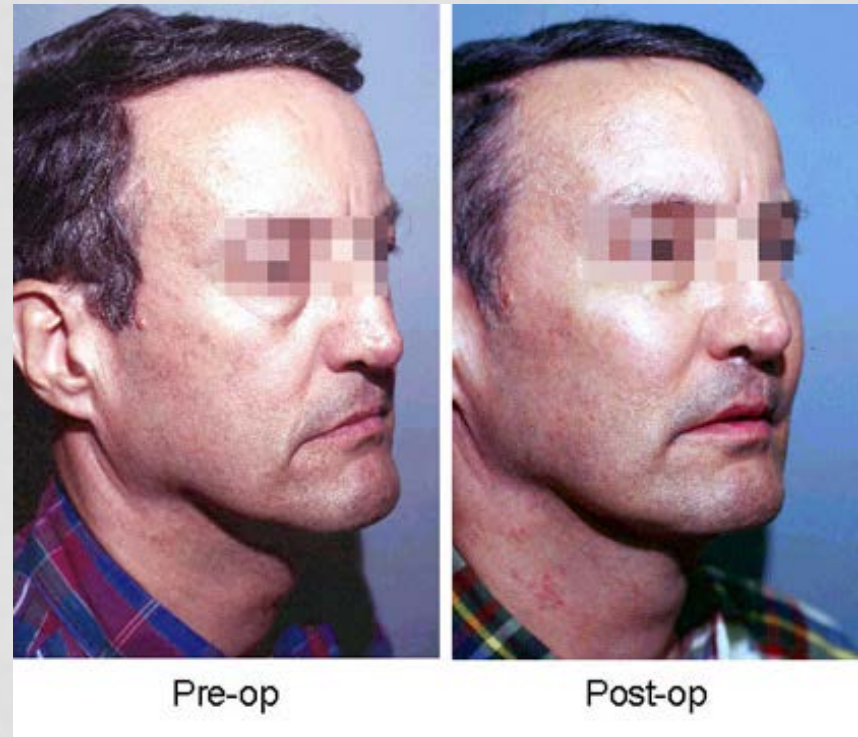
- Incision anterior to gingivobuccal sulcus
 - Extended laterally to cuspid teeth
 - Carried down to the mandible, passing through the orbicularis and mentalis muscles.
- Periosteum is elevated
- An osteotomy is made below the cuspid apices and mental foramina
 - Inferior segment is advanced and held in place with a four-screw cross-plate
- Incision is closed in two layers, taking care to reapproximate the mentalis muscle to avoid lip incompetence.
 - A pressure dressing is applied to support the lip.



MALAR AUGMENTATION

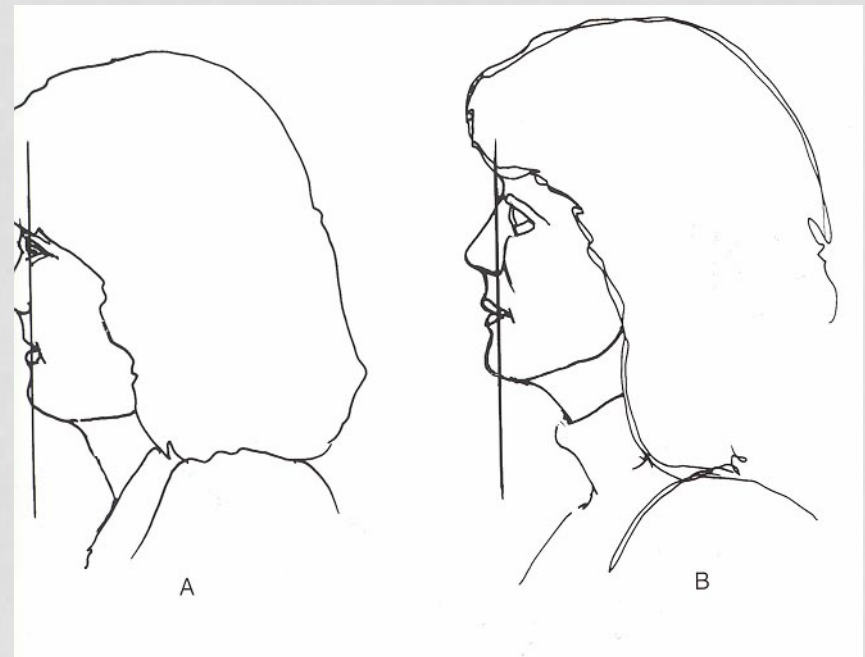
Indications:

- Congenital lack or asymmetry of malar prominence
- Traumatic injury
- Aging: malar soft tissues overlying the zygoma atrophy and descend, giving the face a less youthful, balanced appearance.
- Augmentation gives a youthful appearance to an older face and provides a happier, more decisive look.




DETERMINATION OF MALAR EMINENCE

- Related more to aesthetic appreciation than to an actual measurement
- General rule: deficiency when malar prominence falls more than 5 mm posterior to the nasolabial groove on lateral projection




MALAR PROMINENCE TRIANGLE

- Drop a vertical line from the lateral canthus.
- Draw a horizontal line bisecting the upper lip. The intersection of lines 1 and 2 forms point A.
- Reflect a line from point A to the medial canthal area.
- Reflect a line laterally from point A, creating the same angle as created in step 3.
- Draw a horizontal Frankfort line.



SILASTIC MALAR IMPLANT

- Can be inserted into a small pocket
- Can be used over a malar bone (maxillary sinus) that has been fractured with less concern for future infection contamination.
- Easily removed via capsulotomy
- **Disadvantages:** tend not to stay in original position and must be anchored with suture at initial insertion.
- Surrounding capsule may be palpable as surgical site matures.



GORE-TEX MALAR IMPLANT

- Allows for carving of the implant; conforms easily; stays in place without slipping.
- PTFE forms no capsule and has good tissue fixation secondary to its porosity.

Disadvantages:

- Requires large pocket for insertion.
- If infection from tooth or fractured sinus, then all connective tissue must be completely freed from around the entire implant before trying to remove it.



OPERATIVE TECHNIQUE

- 3 cm intraoral incision inferior and anterior to Stensen's duct
- Subperiosteal dissection and elevation over zygoma
- Avoid injury to infraorbital nerve
- Precise pocket
- Fixation unnecessary
- Watertight two-layer closure of muscle and mucosa

Figure 5. Intraoral view of subperiosteal pocket. Converse retractor (Snowden-Pencer, Tucker, Ga) is in superior position.

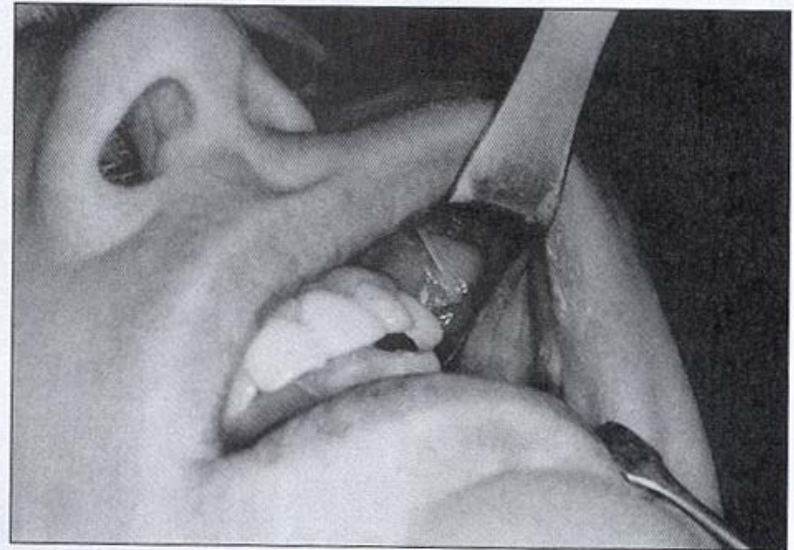


Figure 6. Midfacial malar implant (McGhan Medical, Santa Barbara, Calif) is in position without suture or screw fixation.



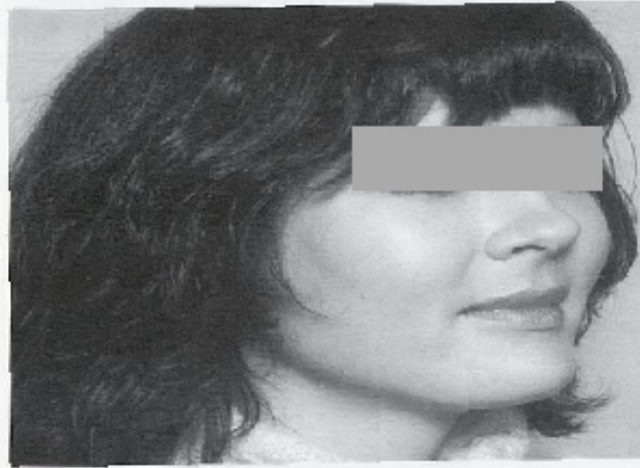
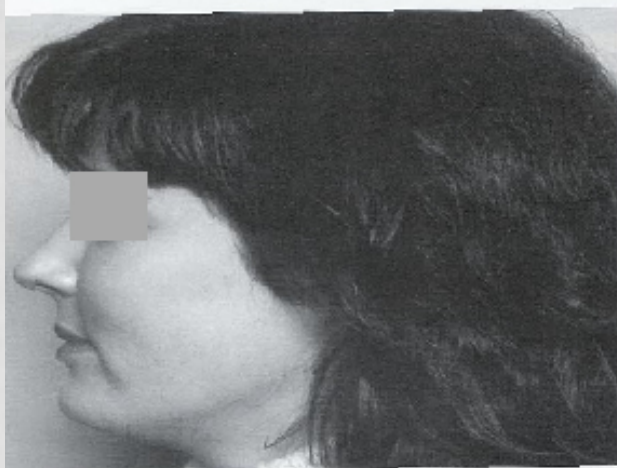
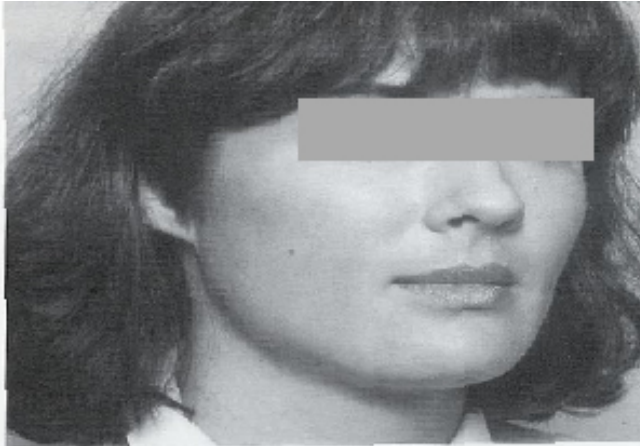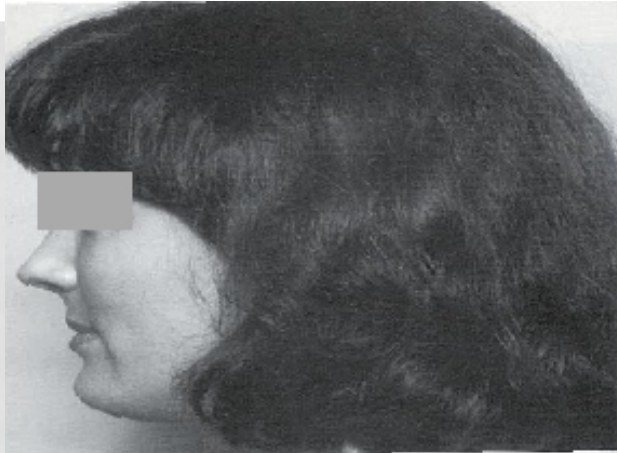FIG. 186-7. Young model who desired more fullness of her cheekbones. **A:** Preoperative view: shallow cheek projection. **B:** Preoperative view: nonprominent malar bone. **C:** Postoperative view shows cheek line in front of nasal alar crease. **D:** Postoperative view shows fullness of cheek.

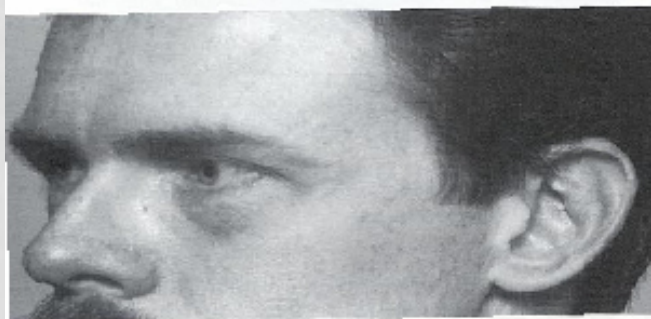

FIG. 186-8. Patient with flattened, withdrawn look. **A:** Preoperative view: flattened malar prominence. **B:** Postoperative view: malar prominence accentuates facial sharpness.

CHAPTER HIGHLIGHTS-

- Ideal chin projection can be determined by using a perpendicular line to the Frankfort horizontal line, intersecting the lower lip vermilion border.
- A solid silicone implant is an excellent choice for chin augmentation, inserted through an external submental incision. Submental placement is preferred. A two-layer closure is needed, followed by a pressure dressing.
- Complications of chin implants are displaced implant, infection or tissue reaction, periosteal resorption, improper size selection, mental nerve injury, and hypertrophic scar.
- Sliding genioplasty is an alternative to a chin implant but is technically more difficult. It should be considered in patients with insufficient vertical mandibular height, mandibular asymmetry, or failed alloplastic chin implant.

CHAPTER HIGHLIGHTS-

- Malar implants are used to increase the fullness of the malar area. This decreases the depth of the melolabial fold and gives a decisive look.
- Indications for malar implants are deep melolabial folds, a flattened malar prominence, asymmetry of the malar prominence, and as an adjunct to facelifts.
- The malar prominence triangle was created to help surgeons place the implant properly. Malar implants can be made of preformed porous material or silicone.
- Complications of malar implants are a malpositioned implant, exposure of the implant, an implant too large or too small, and an infection around the implant.