

PULMONARY PATHOLOGY GROSSING GUIDELINES

Specimen Type: LOBECTOMY

Procedure:

Please note that as part of our research studies we are collecting fresh neoplasm for tissue banking. Please cooperate. Please make sure there is enough neoplasm for diagnostic evaluation, unless otherwise directed by the research protocol and/or by the TPCL staff.

You must check the chart to see if the patient received neoadjuvant therapy. This will affect how the specimen is grossed.

Procedure for cases without neoadjuvant therapy

1. Describe nature of the specimen (entire lung, lobe, wedge resection).
2. Weigh, measure to the mm and photograph
3. Describe pleural surface, noting color, granularity, and presence of adhesions, retraction, and tumor. Describe state of inflation and consistency.
4. Inflate the specimen with 10% formalin. Margins should be inked. After fixation, serially section the specimen.
5. Describe cut surface of lung, noting color and consistency and focal lesions. For tumors, describe size, color, consistency, location, relationship to bronchi and closest distance to pleura and margin or resection. Photograph all tumors.
6. Describe lymph nodes, noting location, range of sizes and appearance of cut surface.

Procedure for cases with neoadjuvant therapy

*Note that steps which are not standard have been highlighted in yellow in the procedure and gross to stand out.

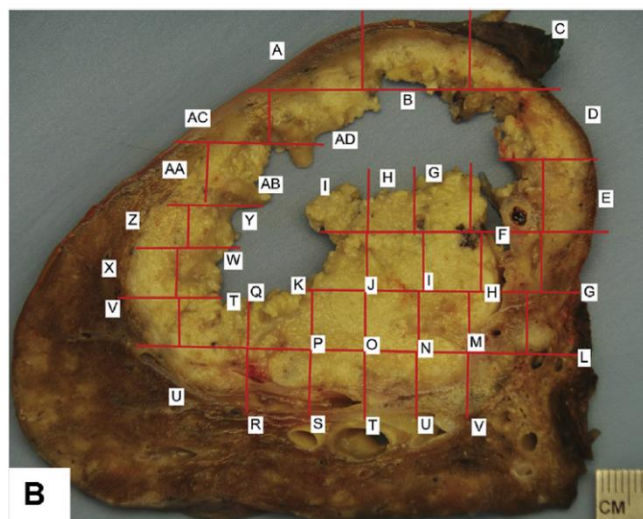
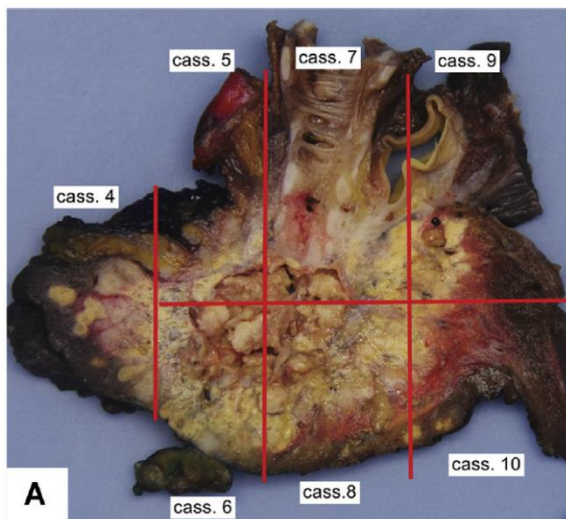
7. Describe nature of the specimen (entire lung, lobe, wedge resection).
8. Weigh, measure to the mm and photograph.
9. Describe pleural surface, noting color, granularity, and presence of adhesions, retraction, and tumor. Describe state of inflation and consistency.
10. Inflate the specimen with 10% formalin. Margins should be inked. Identify tumor and measure in three dimensions
11. **Section the specimen (after fixation) in the plane that demonstrates the maximum dimension of the tumor and best shows the tumor/tumor bed and its relationship to the surrounding structures relevant for staging and surgical margins (ie. pleura and bronchovascular margins).**

PULMONARY PATHOLOGY GROSSING GUIDELINES

- i. Sectioning in this manner will optimize gross and histologic assessment of lung tumor for major pathologic responses to treatment.
12. Photograph the cut surface demonstrating the tumor/tumor bed and adjacent structures. You will be making a tissue map of your submitted cassettes.
13. For tumors, describe size, color, consistency, location, relationship to bronchi and closest distance to pleura and margin or resection. Estimate percentage of gross necrosis of tumor (this will be correlated with the necrosis seen microscopically on the slides).
14. Describe cut surface of remaining lung, noting color and consistency and any additional focal lesions.
15. Describe lymph nodes, noting location, range of sizes and appearance of cut surface.
 - Lymph nodes <0.5cm should be bisected along the long axis and entirely submitted.
 - Lymph nodes ≥0.5 cm should be serially sectioned at 0.3 cm intervals and entirely submitted
16. Submit one full cross section of tumor/tumor bed showing maximum dimension. The sections submitted along the periphery of the tumor should include a border of at least 1 cm of surrounding non-neoplastic lung parenchyma, if possible. Use photomapping software (SPOT camera or paint) to label exact cassette submission on photo. See below:
 - a) Submit entire tumor/tumor bed if less than 3 cm in greatest dimension.
 - b) One section demonstrating closest approach to pleura (order EMT stain on this section).
 - c) Submit at least 1 additional section of tumor for potential biomarker studies (if entire tumor is not entirely submitted)
 - d) Bronchial margin of resection. If tumor is more than 2 cm from margin, take section of entire circumference. If tumor is less than 2 cm from margin, take one or more sections perpendicular to inked margin.
 - e) Pulmonary vascular margins of resection.
 - f) One section of uninvolved parenchyma (including bronchi).
 - g) Sections of any other lesions.
 - h) All lymph nodes entirely submitted.
 - Lymph nodes <0.5cm should be bisected along the long axis and entirely submitted.

PULMONARY PATHOLOGY GROSSING GUIDELINES

- Lymph nodes ≥ 0.5 cm should be serially sectioned at 0.3 cm intervals and entirely submitted



Gross Template:

MMODAL Command: "INSERT LOBECTOMY"

It consists of a [insert weight***] gram, [insert dimensions*** x *** x ***]cm, [intact/previously incised***] [indicate laterality, and if upper, middle, or lower***] lobectomy. The [bronchus measures/bronchi measure***] cm in length x [***] cm in diameter, with a [describe the appearance of the bronchi mucosa and if it's remarkable for features, such as presence/absence of lesion/grossly unremarkable***].

The pleura is [intact/ruptured/smooth/glistening/roughened/puckered***]. There is a [minimal, moderate, extensive***] amount of anthracotic pigmentation. Sectioning reveals [describe all lesions including size, color, involvement of pleura, and distance from margins- bronchovascular, stapled margin, and pleura ***]. The [lesion/tumor/fibrosis] is grossly [***]% degenerated.

The endothelium of the vasculature is [tan-yellow and smooth or remarkable for calcifications***]. The mucosa of the bronchi is [tan-yellow, corrugated, and grossly unremarkable or remarkable for-describe presence of lesion***]. The remaining lung parenchyma is [emphysematous/spongiform/fibrotic/unremarkable***]. [Describe number/size of lymph nodes if identified- indicate if hilar or intraparenchymal- and color/consistency***]. Gross photographs are taken. [A tissue mapping diagram is taken-for treated tumors only, otherwise delete***]. [Representative sections are submitted/The mass is entirely submitted and representative sections of the remaining specimen are submitted***].

INK KEY:

Blue stapled resection margin
Green puckered pleura overlying lesion

Total Formalin fixation: [***] hours

[insert cassette summary***]

Cassette Submission: 10-15 cassettes

PULMONARY PATHOLOGY GROSSING GUIDELINES

Sampling for cases without neoadjuvant therapy

- Bronchial resection margin
 - o Submit shave if tumor is greater than 2 cm away from the margin
 - o Submit 1 or 2 perpendicular sections of margin if tumor is less than 2 cm away from the margin (often centrally located tumors such as SCC)
- Pulmonary vascular resection margins, shave
- 3-4 sections of tumor or 1 section per centimeter if tumor is large
- One section of pleura closest to tumor (if not previously submitted)
 - o Order EMT stain on this section
- One cassette of uninvolved lung (including bronchi)
- Submit all lymph nodes
 - o Indicate hilar vs intraparenchymal LN

Sampling for cases with neoadjuvant therapy

- Bronchial resection margin
 - o Submit shave if tumor is greater than 2 cm away from the margin
 - o Submit 1 or 2 perpendicular sections of margin if tumor is less than 2 cm away from the margin (for centrally located tumors such as SCC)
- Pulmonary vascular resection margins, shave
- Entire cross section of tumor submitted showing greatest maximum dimension. Submit entire tumor if less than 3 cm.
 - o If no mass/fibrotic area is grossly identified then have another person in the gross room confirm. If the second person cannot identify a mass/fibrotic area then submit the entire region known to have tumor based on diagnostic biopsy and/or radiographic studies.
- One section of pleura closest to tumor (if not previously submitted)
 - o Order EMT stain on this section
- Submit at least one additional cassette of tumor for potential biomarker studies if tumor is not already entirely submitted
- One cassette of uninvolved lung (including bronchi)
- Submit all lymph nodes
 - o Indicate hilar vs intraparenchymal LN
 - o Lymph nodes <0.5cm should be bisected along the long axis and entirely submitted.
 - o Lymph nodes ≥0.5 cm should be serially sectioned at 0.3 cm intervals and entirely submitted

PULMONARY PATHOLOGY GROSSING GUIDELINES