


UCLA Radiology

NEWSLETTER OF THE DEPARTMENT OF RADIOLOGICAL SCIENCES

WINTER 2017

**Radiology
meets artificial
intelligence**



IN THIS ISSUE | RADIOLOGY MEETS ARTIFICIAL INTELLIGENCE P. 1-2 | MACHINE LEARNING P. 3 |
ABLATION THERAPY P. 4 | IRREVERSIBLE ELECTROPORATION (IRE) P. 5 | CME P. 6

Radiology meets artificial intelligence



Dieter Enzmann, MD
Professor of Radiology
Leo G. Rigler Chair
Radiological Sciences

The media and even radiology presentations are filled with Cassandraesque statements on the sunset of radiology. These oracular pronouncements are based on artificial intelligence's (AI) recent success in solving complex tasks (Watson for Jeopardy; Google for Go). Machine learning algorithms (MLs), a subcategory of AI, excel in "pattern" identification; when applied to images, this ability overlaps that of radiologists.

Headline-grabbing quotes, such as, "the role of the radiologist will be obsolete in five years"¹ are the result of simplistic extrapolation of early achievements. This "role" is a narrow, somewhat uninformed view of radiologists' contribution to patient care. Google's vice president of health offers an interesting counterpoint to this notion, stating, "there literally have to be thousands of algorithms to even come close to replicating what a radiologist can do on a given day. It's not going to be all solved tomorrow."² This reflects a more informed understanding of MLs, and it also raises the important question, "who will make sense of hundreds to thousands of MLs relevant to radiology's care of patients?" Radiologists have this golden opportunity, which in turn has given rise to the catchphrase, "radiologists won't be replaced by AI, but by radiologists who use AI."

The perceived "role" noted above should prompt not only the radiologists, but the entire radiologic team, to take a proactive, encompassing role in delivering diagnostic and therapeutic patient care, preferably as an integrated service. Predictions of future human behavior in times of rapid change can become exaggerated. In the case of

AI, the exponential increase in computing power is assumed to directly translate into an exponential increase in human, business and economic capabilities and productivity. An exponential pattern is unlikely. Change in complex systems occurs not in a smooth line, but rather in a step-like pattern known as punctuated equilibrium.³ Not surprisingly, when such "punctuations" first appear, linear extrapolations can become quite extravagant. Nevertheless, AI, especially in the form of machine learning, clearly will impact radiology, and will do so positively.

Machine learning as noted by one of its founders, Arthur Samuel in the 1950s, is defined as giving computers the ability to learn a task without being directly programmed to solve that task.⁴ The solution to the task is generated, not by software code specific to that task, but rather by code that learns how to solve the problem posed by the task. Machine learning is a powerful technique, with many variations and applications. Diagnostic radiology must certainly understand and use MLs to accelerate improvements in offering accurate, integrated diagnostic information.

First of all, MLs should not be feared; running from them is not an option. MLs will even

Machine learning algorithms, a subcategory of AI, excel in "pattern" identification; when applied to images, this ability overlaps that of radiologists.


MLs will evolve from detecting abnormalities, to characterizing them to interpreting them in light of broader clinical and pathologic information.

be fun, because machine learning outputs can create extremely interesting “images.” It is helpful to view machine learning as families of algorithms that can solve different classes of problems (diagnostic, therapeutic, etc.). Radiologists will need to acquire skill, experience, and knowledge in how and when to choose appropriate machine learning programs to solve diagnostic or treatment problems. It is useful to know that machine learning’s value is primarily in making predictions based on previous data. MLs will expand radiology’s range of information services. Such an expansion was exemplified by a machine learning algorithm based on chest CT images that successfully evaluated overall health and mortality risk in individuals older than age 60.⁵ Why would this work? Many patients have comorbidities that are recorded in electronic medical records or radiology reports in just a few words. Actual chest CT images, however, reveal these comorbidities in a rich informational image format. MLs can integrate such variegated image data better than the human mind can integrate a list of words, such as diffuse lung disease, emphysema, enlarged heart and aorta, vascular calcification, abnormal mediastinal masses, bone lesions, etc.

MLs will evolve from detecting abnormalities, to characterizing them to interpreting them in light of broader clinical and pathologic information. They will add further intelligence to imaging based screening for breast, lung and prostate cancer. MLs will make radiology teams more accurate, a key source of value. Both diagnostic and interventional radiologists should embrace MLs, by melding this new form of expertise with their knowledge domains, skillsets and judgement abilities.

While an oversimplification, this melding can be at the data science level, at the radiology workflow level and at radiology’s operational level. At the data science level, mathematical innovations in neural networks will be critical in ensuring the accuracy of MLs. MLs, once tested for accuracy and reliability, will be applied to image acquisition, image processing, image analytics, and image interpretation, i.e., the workflow level as represented in the components of radiology’s value chain.⁶ At UCLA, at the workflow level, MLs already accurately analyze, interpret and quantitatively measure drug treatment effects in pulmonary fibrosis. This type of machine learning measurement of changes on lung CTs in response to treatment precedes the human visual system’s ability to describe them even qualitatively.

MLs can also be employed in the analysis of and the running of large-scale radiologic operations involving everything from patient access to enriching the final report, such as in pulmonary fibrosis. MLs will increase efficient use of our high-cost capital equipment, an imperative for cost reduction. MLs could streamline MR protocols by reducing acquisition of duplicate information. They can be used in improving safety by X-ray dose optimization or by assessing risk of contrast media reactions. UCLA is looking into using MLs to improve operations such as reducing wait times for patients. For MLs to be widely adopted, tools to measure their accuracy and value (cost in dollars, time, etc.) need to be developed. Our department has already developed methods to measure machine learning clinical accuracy.

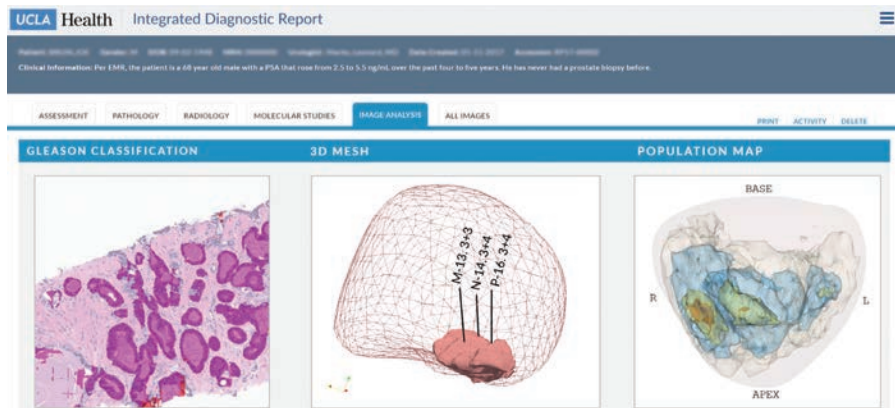
MLs should be seen as knowledge tools to be understood, adopted and utilized by all members of radiology teams to produce better, faster, safer and less expensive diagnostic and therapeutic services. Used intelligently, MLs will increase radiology’s value to patients, as well as raise quality, both of which are essential in the current healthcare environment.⁷ Don’t worry, be happy and befriend machine learning! 

References

- ¹ Farr C. *Here’s why one tech investor thinks some doctors will be ‘obsolete’ in five years.* <http://www.cnbc.com/2017/04/07/vinod-khosla-radiologists-obsolete-five-years.html> April 7, 2017.
- ² Bergen M. *The AI Doctor Orders More Tests.* Bloomberg BusinessWeek. <https://www.bloomberg.com/news/articles/2017-06-08/the-ai-doctor-orders-more-tests> June 8, 2017.
- ³ Enzmann DR, Feinberg DT. *The Nature of Change.* J Am Coll Radiol. 2014 May;11(5):464-70. doi: 10.1016/j.jacr.2013.12.006. Epub 2014 Apr 2. [http://www.jacr.org/article/S1546-1440\(13\)00813-2/fulltext](http://www.jacr.org/article/S1546-1440(13)00813-2/fulltext)
- ⁴ Machine learning, from Wikipedia, https://en.wikipedia.org/wiki/Machine_learning
- ⁵ Oakden-Raymer L, Carneiro G, Bessen T, Nascimento JC, Bradley AP & Palmer L J. *Precision Radiology: Predicting longevity using feature engineering and deep learning methods in a radiomics framework.* www.nature.com/scientificreports. 10 May 2017. <https://www.nature.com/articles/s41598-017-01931-w>
- ⁶ Dieter R. Enzmann. *Radiology’s Value Chain* Radiology Vol. 263: Issue. 1, Pages. 243-252 (Issue publication date: April 2012) <https://doi.org/10.1148/radiol.12110227>
- ⁷ Vivian S. Lee. *Annual Oration: Driving Value through Imaging* Radiology Vol. 285: Issue. 1, Pages. 3-11 (Issue publication date: October 2017) <https://doi.org/10.1148/radiol.2017170798>

UCLA developing machine learning to improve management of prostate cancer

Corey Arnold, PhD
Associate Professor of Radiology,
Pathology & Laboratory Medicine



The UCLA Integrated Diagnostic Report for prostate cancer correlates radiology and pathology findings. This unique report provides a platform that researchers can use to translate machine learning insights to physicians.

Could artificial intelligence eventually be used to help diagnose and treat patients' prostate cancer using data from medical imaging and pathology? A group led by Corey Arnold, PhD, associate professor in UCLA's Department of Radiological Sciences and Department of Pathology & Laboratory Medicine, is developing machine learning algorithms with the potential to improve doctors' abilities to recommend the appropriate treatment for prostate cancer patients — and, equally important, to allow patients with slow-growing cancer to possibly defer invasive diagnostic and treatment procedures.


UCLA currently offers a state-of-the-art imaging program that employs a combination of ultrasound imaging and magnetic resonance imaging (MRI) to screen men for prostate cancer. Radiologists review the images, and if certain regions are deemed suspicious for prostate cancer, a biopsy is performed and the extracted tissue is sent to pathologists for diagnosis and assessment of the cancer's severity. Because many forms of prostate cancer are slow growing, some men with low-risk tumors who choose to delay or forgo immediate treatment — which comes with the risk of significant side effects — may be placed in a program of active surveillance. Typically, a new biopsy is performed on these men every six to 12 months to ensure that their cancer has not become more aggressive and in need of treatment.

But biopsy can be an unpleasant procedure, typically involving the insertion of at least a dozen needles into the prostate to collect tissue, and it carries its own potential side effects, including the risk of infection. So Dr. Arnold and colleagues are exploring the feasibility of using machine learning to perform an "imaging biopsy." Such technology may allow radiologists to improve their identification of suspicious regions — adding value for subsequent targeted biopsies — or may even allow some men to defer physical biopsy until the imaging biopsy indicates its necessity.

"We have a very rich set of imaging data, including anatomical images and functional images of the prostate," Dr. Arnold explains. "Our hypothesis is that this data contains untapped complex signals that differentiate between slow-growing and


more aggressive prostate cancers, and that these signals can be detected using deep learning [a type of machine learning] techniques. We believe that one day these algorithms will help men avoid unnecessary biopsies, and may also allow us to identify men who would benefit from a particular treatment plan."

The team developing machine learning for integrated diagnostics includes several clinical and scientific researchers, and represents a collaboration between the radiology and pathology departments. UCLA has a massive database with which to develop the algorithms, using pathology results from previous biopsies and prostatectomies as gold standards against which the predictive models are measured. "Our initial results indicate that the use of machine learning to identify serious cancer from medical images is promising," Dr. Arnold says.

In addition to developing machine learning algorithms for prostate imaging, Dr. Arnold and his colleagues have similar projects for other cancers, including brain and lung. "In the next five to 10 years, with the ability to train these deep learning algorithms with more and more high-quality data, we will see the development of tools that will assist radiologists in performing their jobs more efficiently and at higher levels of accuracy," Dr. Arnold explains. "There is also the potential that a machine-learning algorithm that has been trained with our data and expertise could be used by general radiologists in other parts of the country, improving health care in areas where there is not the same level of subspecialty expertise." 

Ablation therapy an effective, minimally invasive treatment option for many liver tumors

David Lu, MD
Professor of Radiology
Chief of Cross Sectional
Interventional Radiology
Director of CT, High Intensity Focused
Ultrasound, and UCLA Liver Tumor Ablation



Liver cancer is a major public health issue in the United States, particularly given the high incidence of chronic hepatitis C infection, which increases the risk for liver cirrhosis and cancer. For patients with either hepatocellular carcinoma (primary liver cancer) or metastatic disease that spreads to the liver, advances in the field of tumor ablation therapy are providing a much-needed minimally invasive and effective treatment option, says David Lu, MD, professor of radiology and director of the UCLA Liver Tumor Ablation Program, one of the oldest and largest such programs in the United States.


When radiologists several decades ago developed the ability to use ultrasound, CT and other imaging modalities to insert a needle through the skin into a tumor, it opened up the possibility of treating the tumor in the same, minimally invasive fashion. The first approach involved the use of alcohol — so-called ethanol injection therapy. This was followed by cryo-ablation, which uses a probe to freeze the tumor; and radiofrequency ablation, which kills the tumor by heating it. “With radiofrequency ablation, the field became much more popular,” Dr. Lu says. “Using a small needle, and either an ultrasound machine or CT, you could get the probe into the tumor, generate a two to three centimeter ablation zone, and effectively deal with small liver tumors with a percutaneous procedure that took an hour or two.”

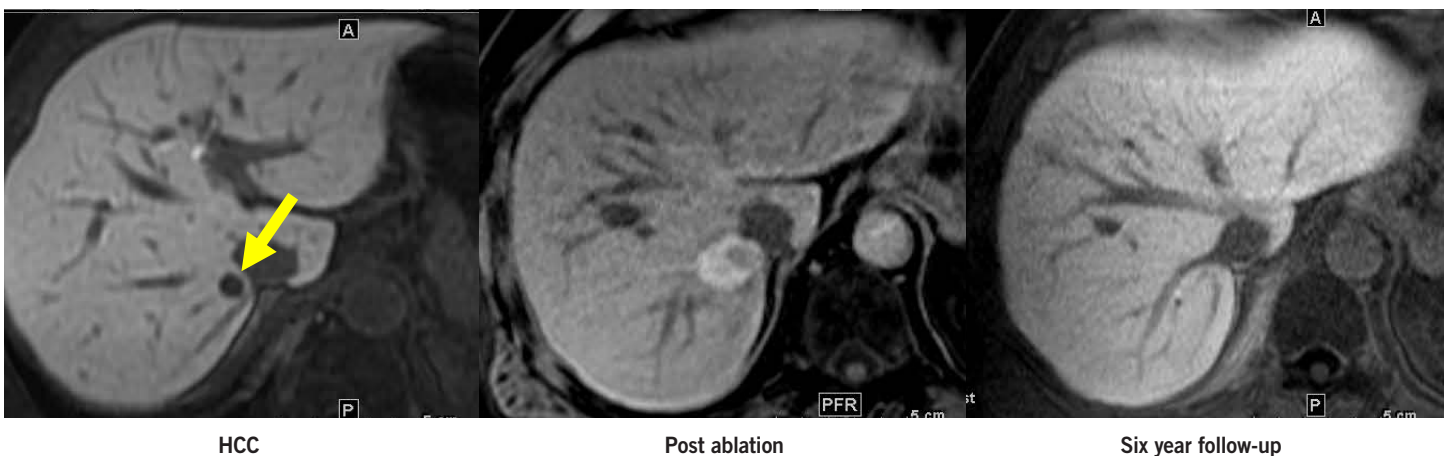Radiofrequency ablation as a treatment for liver tumors grew dramatically in the last two decades, Dr. Lu notes. At the same time, beginning in the mid-2000s, a new heat-based ablation approach, microwave ablation, began to emerge. “With microwave, we can generate larger ablation zones because we can heat tissue at a higher temperature over a shorter time period, and we can place simultaneous microwave probes to make the ablation zones even bigger,” Dr. Lu says. “That has made it feasible to treat larger tumors that were once considered too difficult.”

Microwave has become the most popular thermal ablation therapy in the United States, although radiofrequency ablation, cryoablation and in some cases ethanol injections are still used,

Dr. Lu adds. A new non-thermal ablation technology known as irreversible electroporation, which sends short, high-voltage electric pulses to the tumor, is currently under investigation.

Although ablation is used for several types of tumors, it is particularly well suited for liver cancer. “In the early stages of hepatocellular carcinoma, when the tumor is confined to the liver, we can achieve a 50 percent five-year survival rate — nearly identical to surgical resection — with a minimally invasive procedure,” Dr. Lu says. Moreover, he notes, many patients who develop liver cancer have cirrhosis of the liver and are awaiting a transplant. The wait can be months, or years, and in the meantime these patients are closely monitored for tumors that develop in the liver, which can be immediately ablated. After hepatocellular carcinoma, the next most common liver tumor is metastasized colon cancer. While these small metastases may not be good candidates for resective surgery, patients’ lives can be significantly prolonged with ablative treatments.

At UCLA a multidisciplinary team works together to determine the best course of action for treating the lesions. “We are able to treat liver cancer percutaneously — with good outcomes and low complication rates — using these ablation techniques, but it’s important to remember that the outcomes of this therapy are best when the tumors are small and early-stage,” Dr. Lu says. “Therefore, it’s extremely important that patients who are at risk for developing liver cancer are consistently screened and monitored.” 

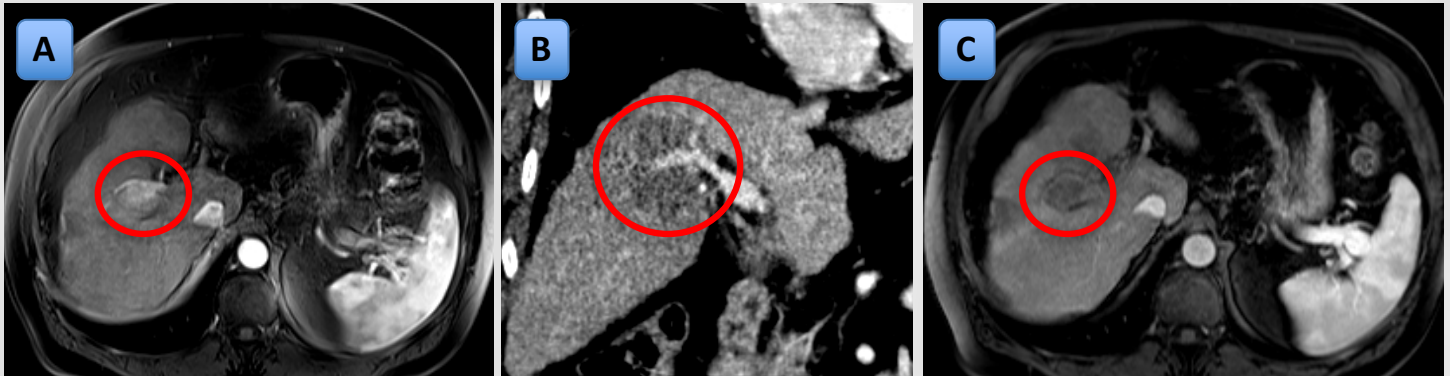


IRE exploits programmed cell death to target cancer cells

Stephen Kee, MD
Professor of Radiology
Section Chief of
Interventional Radiology



Irreversible electroporation (IRE) is an ablative cancer treatment in which needle electrodes apply electrical impulses to a well-defined treatment area. The electricity stimulates cells to open their pores — as they normally would to take in nutrients — but opens them permanently and induces apoptosis, a process of programmed cell death in which the intact cell simply shuts down and dies. Multicellular organisms rely on apoptosis to eliminate unnecessary or unwanted cells.



(A) Pre-IRE ablation MRI showing tumor in the liver with enhancement; (B) Immediately post-IRE ablation demonstrating complete eradication of liver tumor sparing large portal vein, which is very unique and advantageous for IRE ablation; (C) Post-IRE ablation MRI showing complete eradication of liver tumor without residual.

IRE is a fast, painless and effective cancer treatment. Its principle strength lies in its ability to kill cancer cells that are in close proximity to vital structures that must be left intact. Unlike other ablation techniques — including microwave, radiofrequency ablation and cryoablation — IRE does not destroy cells by means of coagulation necrosis (heating or freezing), which changes the nature of cell proteins and damages cell membranes. IRE's ability to induce apoptotic cell death is the key to its ability to spare important nearby structures, such as blood vessels and bile ducts in the liver.


“The trouble with coagulation necrosis is that the cells adjacent to the ones being treated are also at least partially destroyed by heat or freezing temperatures that emanate from the treatment zone,” explains Stephen Kee, MD, professor of Radiology and chief of Interventional Radiology at UCLA. “Irreversible electroporation works in a different way. It causes them to open their pores and tells them, ‘your time is done; you need to die.’”

UCLA played an active role in IRE basic scientific research, conducting pre-clinical studies of the technology. UCLA physicians are now using IRE to treat select liver, pancreatic and kidney cancer patients. At present, the procedure is reserved for cases where more standard ablation techniques would be problematic — principally due to adjacent vital structures that must be preserved.

The irreversible electroporation procedure is performed under general anesthesia because the electrical pulses cause local muscles to spasm during the treatment. The interventional radiologist places needle probes in parallel pairs across the treatment area. The electrical energy flows between the paired needles, which define the treatment area, so accurate placement is critical to treatment success. Mapping software helps determine the number of needle pairs required and how they should be positioned. Needle placement is done with CT or ultrasound guidance, or both.

“With IRE, the delivery of energy to the right place is technically very demanding,” states Dr. Kee. “Getting the needles around the tumor accurately can be very cumbersome. In treating liver tumors, for example, the ribs can get in the way of placing needles in their ideal locations — you sometimes have to angle them in from less ideal insertion points.”

With the needles in place, delivery of energy to treat the tumor takes only minutes. Follow-up treatment may be required after about two months to treat edges of the tumor that continue to grow.

IRE is just one of the latest cancer treatment modalities offered by UCLA interventional radiologists, who perform both vascular and percutaneous procedures. Each case is evaluated independently and patients are offered the treatments that are most appropriate for their health needs. 



David Geffen
School of Medicine

8th Annual UCLA Musculoskeletal Ultrasound Course and Hands-on Workshop

Featuring optional full-day interventional training with cadaver lab

Course Director



Benjamin D. Levine, MD
Associate Professor of Radiology
Director, Musculoskeletal Interventions

Clinical Co-director



Kambiz Motemedi, MD
Professor of Radiology
Director, Beach Imaging &
Interventional Center



January 27 & 28, 2018
Course and Hands-on Workshop
UCLA Medical Center,
Santa Monica

January 29, 2018
Cadaver Lab
UCLA Center for Health Sciences
UCLA Campus
Los Angeles, CA



David Geffen
School of Medicine

MRI, Targeted Biopsy, Intervention and Biomarkers in Prostate Cancer Management 2018

A paradigm shift in detection, grading, staging, reporting, biopsy and treatment

Course Director



**Steven Raman, MD,
FSAR, FSIR**
Professor of Radiology
Director of Abdominal Imaging
Fellowship
Co-director of UCLA Fibroid
Treatment Program



Saturday, February 17, 2018
UCLA Meyer & Renee Luskin Conference Center
UCLA Campus
Los Angeles, CA



Registration and course information <http://radiology.ucla.edu/cme>

UCLA Health

Department of Radiological Sciences

405 Hilgard Avenue
Los Angeles, CA 90095

NONPROFIT
ORGANIZATION
U.S. POSTAGE

PAID

UCLA



You have the power to make a world of difference in Radiological Sciences. Join forces with UCLA to advance human health and improve outcomes and quality of life for patients and their loved ones. If you would like information on how you can help, please contact:

Silviya Aleksiyenko, MPA
Director of Development
Health Sciences Development



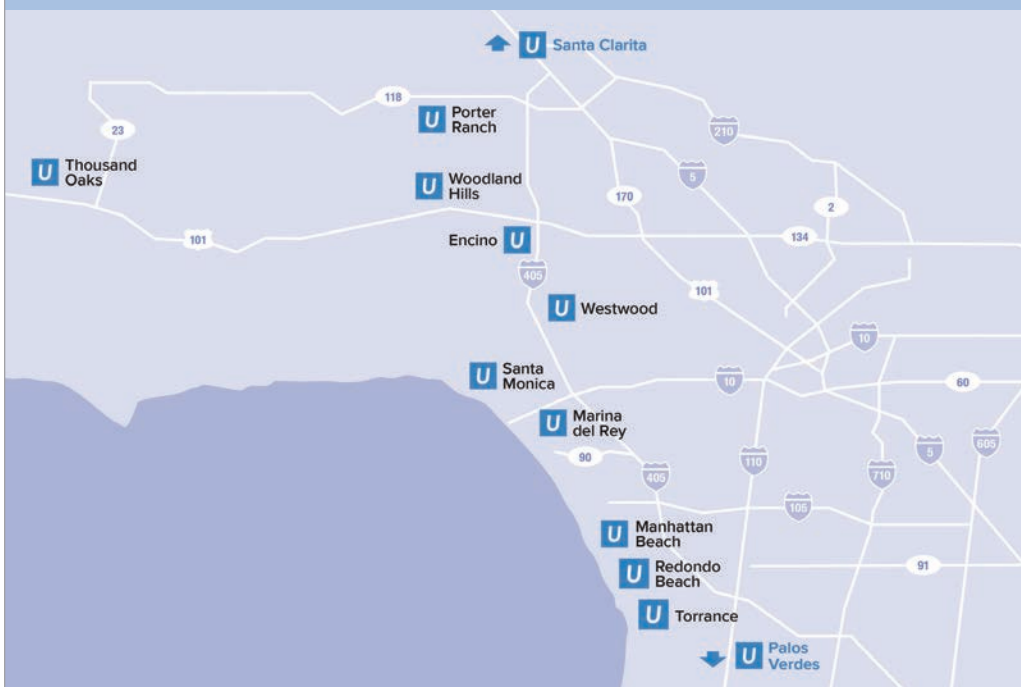saleksiyenko@support.ucla.edu
or go to: www.radiology.ucla.edu
310-206-9236



Our locations

UCLA Radiology is committed to providing outstanding patient care by combining excellence in clinical imaging, research and educational programs with state-of-the-art technology.

For more information, visit radiology.ucla.edu or call (310) 301-6800.



UCLA Radiology

WINTER 2017

LEO G. RIGLER CHAIR AND PROFESSOR

Dieter R. Enzmann, MD

EXECUTIVE VICE CHAIR

Jonathan G. Goldin, MD, PhD

CHIEF ADMINISTRATIVE OFFICER

Brenda Izzi, RN, MBA

CHIEF FINANCIAL OFFICER

Suzie Morrel, MSF

BUSINESS DEVELOPMENT

Leila Farzami

WRITERS

David Barrad

Dan Gordon

DESIGN

SD Graphics



Contact us at:

RadNewsletter@mednet.ucla.edu

A Publication of
UCLA Department of Radiological Sciences
©2017 UCLA Radiology Department All rights reserved