

CARDIOVASCULAR PATHOLOGY GROSSING GUIDELINES

NOTE: Please review all complex or “interesting” gross specimens with the HL attending assigned to the case.

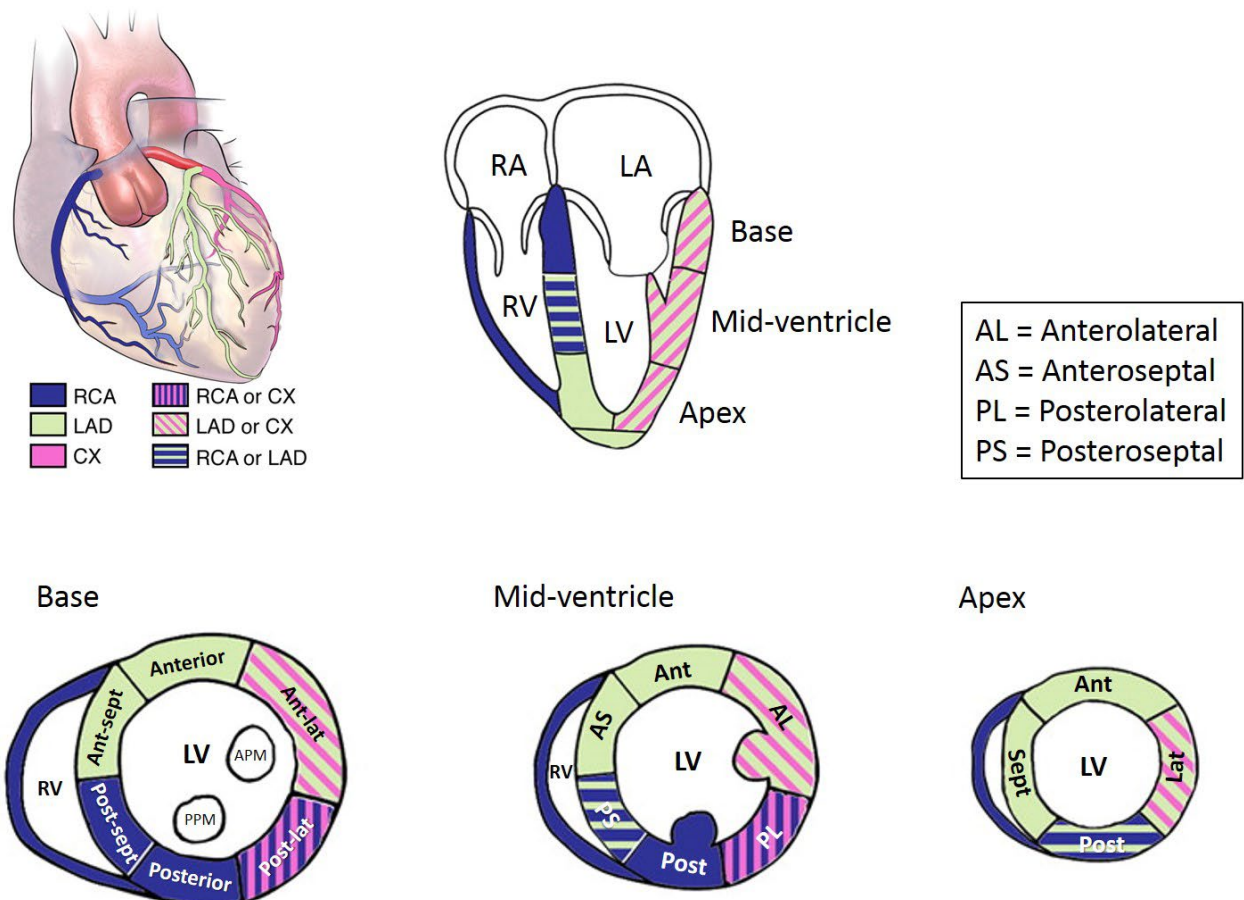
Specimen Type: HEART TRANSPLANT (recipient explant specimen)

Procedure:

1. Discuss the case with the attending before putting the heart in formalin.
2. Photograph the anterior and posterior surfaces; get an x-ray.
3. Weigh and measure the specimen (base to apex; left to right).
4. Provide an external examination with focus on the following:
 - a. Is the heart dilated?
 - b. If present, what is the morphology of the atrial appendages?
 - c. What is the configuration of the great arteries?
 - d. Are there pericardial adhesions?
 - e. How much pericardial fat is there?
5. If calcified, the coronary arteries may need to be dissected off before proceeding (x-ray can help decide this). If decalcification is needed:
 - a. Dissect the coronary arteries from the heart noting course, size and dominance of vessels. Remove with any vein or internal mammary grafts.
 - b. Fix overnight.
 - c. Decalcify adequately.
 - d. Cut at 3 mm intervals.
 - e. Note distribution of lesions and degree of luminal narrowing.
 - f. Note characteristics of lesions.
 - g. Photograph.
 - h. At a minimum, submit regions of maximum narrowing for histologic sections (LAD, RCA, LCx). If any gross lesions are identified, submit sections of those too.
 - i. If grafts are present, submit regions of gross lesions and sites of anastomosis to coronary arteries (remove sutures if possible).
 - j. Look out for stents (x-ray can be helpful).
6. Hearts with congenital malformations must be reviewed with the attending pathologist prior to dissection. For all other hearts, unless otherwise specified:
 - a. Breadloaf the heart from apex to mid ventricle (3 – 4 transverse slices).
 - b. Photograph the slices.
 - c. Open the heart in the direction of blood flow.
 - d. Photograph any intracardiac lesions if present.
7. The atria and/or appendages may not be included with the specimen, indicate if absent.
8. Describe the individual chambers. Are they dilated? Are the walls thinned? Is there hypertrophy? Aneurysms?

CARDIOVASCULAR PATHOLOGY GROSSING GUIDELINES

9. Describe the endocardial surfaces (Note thickening, hemorrhage, mural thrombus, fibrosis, etc...).
10. Describe the appearance of the cardiac valves. For semilunar valves, note number of cusps, their thickness, and status of commissures. Note the presence of calcifications of leaflets or annulus. Examine chordae tendineae for thickening, shortening, or fusion. Measure valve circumferences.
11. Examine the coronary circulation. Is it right, left, or co-dominant? Is the course normal or anomalous? Is the course epicardial (normal) or are there areas of myocardial tunneling. Are the ostia in the normal positions? At least one section of each major coronary vessel is recommended (LAD, RCA, LCx).
12. If any hardware is present (e.g. ventricular assist device, pacemaker, etc...), photograph the hardware and note the serial number on the device. Try to be as specific as possible when describing the device (e.g. "HeartMate II" rather than just "LVAD"). Sample adherent tissue to evaluate for infection.
13. Every heart is different, so the sections of myocardium you submit may be different on a case by case basis (discuss with attending). Always sample any focal lesions in addition to the standard sections, as illustrated below:



Adapted from Lang RM, et al. Eur Heart J Cardiovasc Imaging 2006, 7:79-108

1. Anteroseptal
2. Anterior

CARDIOVASCULAR PATHOLOGY GROSSING GUIDELINES

3. Anterolateral
4. Posterolateral
5. Posterior
6. Posteroseptal
7. Right ventricle

Take sections from the mid-ventricle so as to include the papillary muscles. Make sure sections are transmural (include endocardium and epicardium). The endocardial side is of particular importance, since most pathology will be subendocardial. Sampling in this way will help identify which coronary vessel(s) are involved.

14. For your write-up, list the primary pathologic process (e.g. atherosclerotic coronary artery/ischemic heart disease, dilated cardiomyopathy, complex congenital heart disease, etc...) followed by the sequelae of the primary disorder or secondary findings (e.g. myocardial infarction). List the past procedures and comment on the presence or absence of any device pathology, if applicable.

Gross Template:

MMODAL COMMAND: INSERT HEART TRANSPLANT

It consists of a [***] gram, [*measure in three dimensions****] cm cardiac explant specimen, transected at the level of the atria. [Note: X-ray the heart before dissection, and take anterior and posterior external photographs before cutting specimen and cut surface photos after sectioning-delete sentence from dictation***]The epicardial surface is remarkable for [*focal or dense adhesions/smooth/increased fat****]. The configuration of the great arteries is [*normal, abnormal, describe****]. The right atrium is [*normal in size, dilated, hypertrophied****]. The foramen ovale is [*closed, patent, cannot be assessed****]. The tricuspid valve has the normal number of leaflets and is free of thrombi, calcification, myxomatous degeneration, and vegetations [*if abnormal, describe****]. The chordae tendineae are of [*normal length and thickness, fused, shortened****]. The right ventricle is [*normal size, dilated, hypertrophied****]. The pulmonic valve is grossly unremarkable [*if abnormal, describe****]. The left atrium is [*normal size, dilated, hypertrophied****]. The mitral valve has the normal number of leaflets and is free of thrombi, calcification, myxomatous degeneration, and vegetations [*if abnormal, describe****]. The chordae tendineae are of [*normal length and thickness, fused, shortened****]. The left ventricle is [*normal size, dilated, hypertrophied****]. The aortic valve is grossly unremarkable [*if abnormal, describe****]. The coronary ostia are [*in the normal position, anomalous (describe)****]. The coronary arteries are [*right dominant, left dominant****] and have a [*normal epicardial course, anomalous course (describe), intramyocardial course (describe location, length of intramyocardial component, and depth***)*]. The right coronary artery is [*patent, calcified, % stenosis****]. The left anterior descending coronary artery is [*patent, calcified, % stenosis****]. The left circumflex coronary artery is [*patent, calcified, stenosis****]. [*Describe any stents or bypass grafts present****]. The mural endocardium is [*translucent, fibrotic (distribution***)*]. The myocardium is [*brown and unremarkable, fibrosis, myocardial infarction****].

The heart measurements are as follows:

Tricuspid valve (cm): [*circumference in cm****]

Pulmonic valve (cm): [*circumference in cm****]

Mitral valve (cm): [*circumference in cm****]

Aortic valve (cm): [*circumference in cm****]

Right ventricular free wall (cm): [*wall thickness measured ~1 cm inferior to PV****]

Interventricular septum (cm): [*wall thickness excluding trabeculae****]

CARDIOVASCULAR PATHOLOGY GROSSING GUIDELINES

Left ventricular free wall (cm): [*wall thickness excluding trabeculae****]

[*Describe any devices present – VAD, pacer wires, separately received soft tissue fragments etc.****].
Representative sections are submitted. Gross photographs are taken. A faxitron image is taken.

[*insert cassette summary*]