

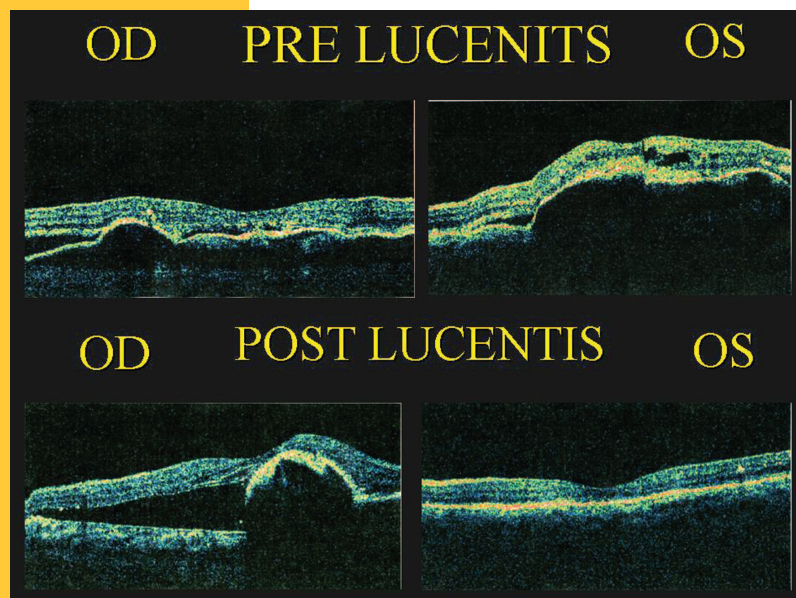


Clinical Update

January 2008

Volume 17, Number 1

Intraocular Anti-VEGF Injection Therapy: A Revolution in AMD Treatment but not a Panacea



Above: OCT images of the macula pre- and post-Lucentis therapy. The patient had RPE detachments and the wet form of AMD in each eye pre-Lucentis. After Lucentis, the patient developed an RPE tear and blindness in the right eye, whereas the left eye normalized and improved vision.

Within the last two years, new therapies have revolutionized the treatment of wet age-related macular degeneration (AMD). Intraocular injections of Avastin and Food and Drug Administration (FDA)-approved Lucentis, both of which inhibit vascular endothelial growth (VEGF), have dramatically improved the vision and quality of life of patients with wet AMD. However, a UCLA retina specialist cautions that not all patients experience an optimal outcome. Macular scarring may limit the visual prognosis, and this scarring can in some cases result from a complication of the therapy – retinal pigment epithelium tears. Although this complication is unlikely to change the course of treatment for wet AMD patients, it may be important to educate susceptible patients about this potential adverse effect, says David Sarraf, M.D., associate clinical professor

at UCLA's Jules Stein Eye Institute, whose research has begun to describe the risk factors.

Approximately 10 million Americans are affected by AMD, and at least one million of them have the wet form, which is the leading cause of blindness in the developed world. For many years, Dr. Sarraf notes, these patients were treated with two types of laser therapies, neither of which improved vision. FDA approval in 2004 of Macugen, the first anti-VEGF treatment, represented an important breakthrough, but, while delaying vision loss, it did not improve vision. That changed with the advent of two anti-VEGF antibodies, Avastin and Lucentis. "Studies have found that both of these drugs improve vision, on average, by at least two to three lines, which is unprecedented in the long history of AMD," Dr. Sarraf says.

Lucentis and Avastin appear to have similar modes of action, Dr. Sarraf explains – both inhibit factors that drive the growth of blood vessels, halting or reducing the leakage and bleeding under the macula that is responsible for the cell death and scarring that can result in central blindness. It appears the efficacy of the two antibodies is also comparable, although they have not been directly compared; a large federal trial is now embarking on that process. For now, the major known difference is that Lucentis, which was approved by the FDA in July 2006, has been more rigorously

INTRAOCULAR ANTI-VEGF INJECTION THERAPY *(continued from page 1)*

studied, with prospective trials; data on the use of Avastin, which is not FDA-approved for intraocular injection in AMD, are predominantly retrospective. On the other hand, there is a substantial financial difference: Lucentis costs about 40 times more than Avastin.

One in Six Occult-form Patients Experience Adverse Event

Both Lucentis and Avastin are indicated for the two main types of wet AMD – the occult form (comprising roughly two-thirds of AMD patients), in which the new blood vessels are hidden under the retinal pigment epithelium (the pigment


already elevated and taut, to tear, and that can stimulate more scar formation.”

This complication is not always visually compromising. “Some patients can develop small tears that are not in the center of the vision, and in which the fluid and the blood have already resorbed,” Dr. Sarraf says. “These patients can maintain relatively good vision. However, the majority who experience this complication have more significant tears that go through the center and can drastically limit their visual prognosis.”

Dr. Sarraf and his colleagues have published two papers on the

not clear that being able to identify higher-risk patients would affect their treatment course. “Most likely we would continue to inject these patients, because of the low incidence of this complication and because the treatment holds significant potential for improvement,” he says. “But these patients would need education so that their expectations are realistic and they understand the possibility that even though the treatment is a major breakthrough, there is still the possibility that they could lose their central vision.”

Other important questions remain to be addressed through research. Among these is whether it is best to proceed with the injections when patients have a tear and are continuing to leak or bleed. “We don’t have the answer yet, but I think at this point we need to consider continuing the injections in these patients,” Dr. Sarraf says. His group is also looking into whether it is possible and beneficial to identify patients who have micro-tears – smaller RPE tears that are more difficult to identify clinically – and limit injections to prevent the more serious tears. Ultimately, Dr. Sarraf hopes, a better understanding of this complication might lead to strategies for preventing it.

For now, Dr. Sarraf concludes, it is important for ophthalmologists to apply caution when counseling their patients. “There is great optimism and expectation with regard to these anti-VEGF therapies, which are unprecedented in their ability to improve vision,” he says. “Nevertheless, patients need to be properly educated and understand that these are not panaceas, and that there are potentially adverse outcomes.” 

“THERE IS GREAT OPTIMISM AND EXPECTATION WITH REGARD TO THESE ANTI-VEGF THERAPIES, WHICH ARE UNPRECEDENTED IN THEIR ABILITY TO IMPROVE VISION.”

layer under the macula referred to as the RPE); and the classic form, in which the new blood vessels have broken through the RPE and are exposed under the macula. “The injections seem to work with near equal efficacy with both the occult and classic types,” says Dr. Sarraf.

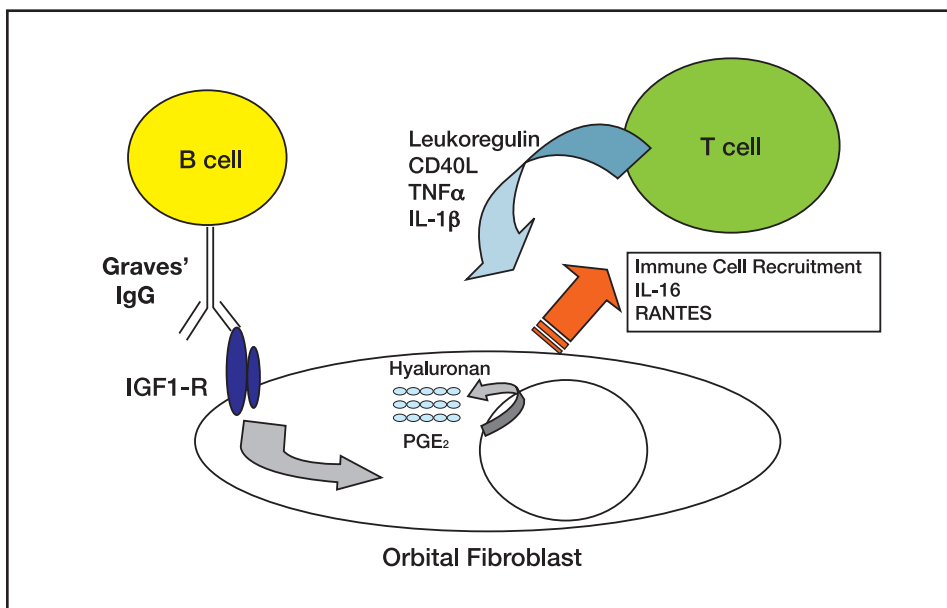
There is one caveat, which has been the focus of Dr. Sarraf’s research: When one of the new anti-VEGF therapies is used to treat patients with the occult form and a detached RPE, an RPE tear may develop following the injection. “For some of these patients, injection with the antibody blocks the chemical messenger for new blood vessels to grow, causing the new blood vessels to contract or scar,” explains Dr. Sarraf. “This can cause the pigment epithelium, which is

complication; a third report, in which they conducted a systematic comparison of the occult AMD eyes that tore vs. those that did not, is expected to be published next spring. In that study, 60 patients with RPE detachments were studied, 10 of whom experienced a tear. Using angiography and optical coherence tomography, Dr. Sarraf’s team found that the latter patients had much larger, more elevated pigment epithelial detachments than patients in the non-tearing group.

Research Aims to Identify At-risk Patients Prospectively

Dr. Sarraf hopes that this and follow-up studies might lead to the ability to identify which patients are at greater risk prior to the injection treatments. On the other hand, it is

Thyroid Eye Disease: The Quest for Effective Medical Treatment



JSEI investigators believe that antibodies present in the sera of Graves' patients interact with the IGF-1 receptor on the orbital fibroblasts, setting off a cascade of events including hyaluronan production, cytokine production, and signaling and recruitment of lymphocytes.

Thyroid-related orbitopathy continues to be a frustrating problem for ophthalmologists. Substantial progress has been made in surgically treating the late structural changes that are caused by the disease: for example, advances in orbital decompression pioneered at the Jules Stein Eye Institute (JSEI) have resulted in better success rates with fewer complications. However, surgery is certainly not perfect, and what is really needed is the ability to accurately diagnose the disease early, and treat it effectively medically, to eliminate the late fibrotic changes that cause so much disability for the patient.

Molecular Mechanisms in Graves' Orbitopathy

Raymond Douglas, M.D., Ph.D., Terry Smith, M.D., Robert Alan Goldberg, M.D., and Angelo Tsirbas, M.D., the faculty of the JSEI Orbital and Ophthalmic Plastic Surgery

Division, have embarked on a multi-pronged research effort with the goals of identifying basic molecular mechanisms that underlie Graves' orbitopathy, and developing effective treatments for the condition.

Over the past few years, key molecular features of the disease have been illuminated based on the work of Drs. Douglas and Smith. The IGF-1 receptor has been shown to have an important role in Graves' orbitopathy and likely represents the antigen that provokes the autoimmune response. This receptor is increased on orbital fibroblasts and also lymphocytes. JSEI investigators believe that antibodies present in the sera of Graves' patients interact with the IGF-1 receptor on the orbital fibroblasts, setting off a cascade of events including hyaluronan production, cytokine production, and signaling and recruitment of lymphocytes (see figure above). As the

(continues on page 4)

Orbital Disease Center

The Orbital Disease Center brings multidisciplinary expertise to the treatment and study of orbital diseases arising from trauma, cancer, inflammation and infection. Care is organized around a team of experts in ophthalmology, neuroradiology, neurosurgery, head and neck surgery, radiation oncology and craniofacial surgery.

Both medical and surgical management is employed in the Center. Modern ophthalmic operating rooms within the Jules Stein Eye Institute provide advanced instrumentation for ophthalmic surgery, oculoplastic surgery, orbital bony reconstruction and orbital microsurgery. The treatment team performs procedures that are not usually available in the community, including orbital decompression microsurgery for orbital apical tumors, optic canal decompression and bony reconstruction to address traumatic or congenital defects. The Center has an active program for patients with Graves' disease and is conducting outcomes research to evaluate new surgical techniques for these patients, as well as data analysis to further understand the progress of the disease.

Information and referral

Phone: (310) 206-8250

Fax : (310) 825-9263

THYROID EYE DISEASE *(continued from page 3)*

molecular mechanisms are elucidated, multiple points in the complex feedback loops are identified that might represent therapeutic targets. These targets include the IGF-1 receptor itself, the cytokines that participate in signaling, and the T and B lymphocytes that participate in the immune response.

There are already some biologic agents available that might successfully interrupt these pathways. For example, Rituximab is currently under investigation. Certainly, the coming decade will see increasing numbers of biologic immunomodulating agents developed. In order to test these drugs, investigators need a reliable and well characterized response index.

Providing Leadership in Graves' Research


JSEI is spearheading an interna-

tional study group, which had its first meeting at the Jules Stein Eye Institute in November 2006, attracting scientists and clinicians from around the world. Using the models established for the study of rheumatologic diseases such as arthritis and scleroderma, and with expectation of government funding, the group is in the process of creating a validated clinical index that will include quality of life measurements.

A natural outcome of the national and international collaboration is the formation of relationships and identification of centers of excellence that will establish the foundation for multicenter clinical trials. JSEI scientists will continue to participate and provide leadership in national and international Graves' research.

Finally, JSEI continues to develop

a regional, national and international referral practice in Thyroid Related Orbitopathy. The Institute's high clinical volume, with more than 1,000 patients in its Graves' disease registry, allows JSEI orbital and ophthalmic plastic surgeons to develop enormous clinical expertise in medical and surgical treatment of patients with thyroid eye disease, and to train residents and fellows. Each patient is carefully characterized and the clinical data is catalogued in an electronic medical record. This extensive clinical patient base provides the foundation for current and future research.

The Jules Stein Eye Institute values referrals of patients with thyroid-related orbitopathy and believes that Graves' patients benefit from the rich expertise and experience of its Orbital Disease Center. 

JSEI CONTINUING EDUCATION PROGRAMS & GRAND ROUNDS SCHEDULE
2007-2008

For information or to add your name to our distribution list,
contact the Office of Academic Programs at (310) 825-4617
or visit our website at <http://www.jsei.org>.

Jules Stein Eye Institute UCLA
100 Stein Plaza
Box 957000
Los Angeles, CA 90095-7000
U.S.A.

First Class Mail
U.S. Postage
PAID
UCLA