

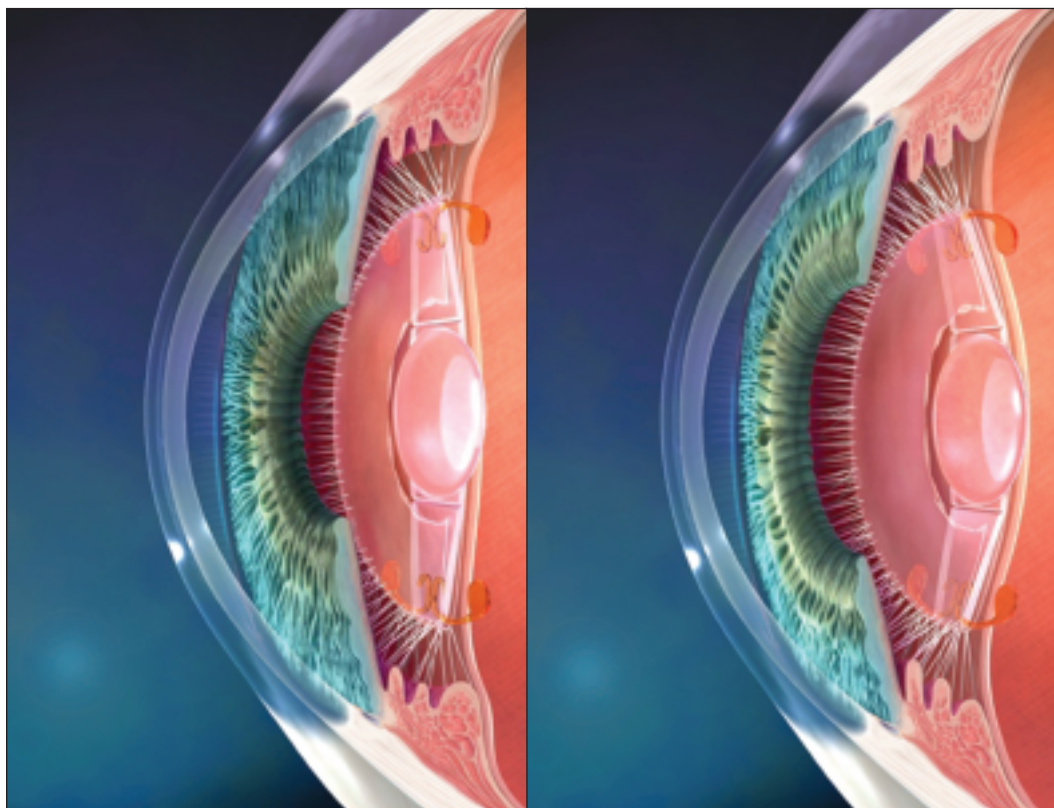


Clinical Update

September 2004

Volume 13, Number 3

Accommodating Change: Intraocular Lenses



Position of Crystalens is further forward in the eye when viewing a near object

Position of Crystalens is further back in the eye when viewing a distant object

The Jules Stein Eye Institute now offers patients a mode of vision correction available at only a handful of Southern California centers—the accommodative intraocular lens. Since November 2003, when the Crystalens™ (eyeonics, inc., Aliso Viejo, CA) was approved by the Food and Drug Administration (FDA) for use in this country, it has attracted much interest from clinicians and patients, reports D. Rex Hamilton, M.D., Assistant Professor of Ophthalmology at the Institute and Director of the UCLA Laser Refractive Center. “It can simultaneously solve two problems of aging eyes: cataract and presbyopia. Unlike standard single-

focus lens implants, which correct distance vision only, the Crystalens has a flexible, hinged design allowing movement backward and forward within the eye (see illustrations above). For select patients, Crystalens restores the most natural range of near, intermediate, and distant focusing ability currently available,” Dr. Hamilton says.

Greater Expectations

At present, the best candidates for Crystalens have some lens yellowing (or other changes requiring cataract surgery) and are hyperopic, but have an otherwise healthy eye: a normal cornea, and no macular degeneration, significant

Our web site address is
<http://www.jsei.org>

Physician's Direct
Referral Line:

(310) 794-9770

(continued on page 2)

INTRAOCULAR LENSES *(continued from page 1)*

glaucoma, or high astigmatism. Crystalens implantation will not restore near vision to that of a 20-year old, Dr. Hamilton admits, but for most patients it will provide "practical" vision for tasks such as reading labels, cellphones, or menus. "Today's lens model may be somewhat limited for the mildly myopic patient, especially one without much of a cataract who could simply remove his or her glasses to read. Future technical refinements will likely increase the amount of accommodation that can be restored, but for now it's important to set expectations appropriately," he notes.

Finer Biometry

Patient expectations for largely eyeglass-free vision mean that Crystalens surgery must rely on preoperative measurements of optic features that are much more detailed and precise than standard ultrasound provides for the typical cataract patient. Explains Dr. Hamilton, "The biometrist at the Institute is incredibly experienced in immersion A-scan ultrasound as well as another state-of-the-art device called the IOL Master; these devices are essential to ensuring the most accurate measurements of the length of the eye. In addition, we use the very latest corneal topography system, known as the Orbscan, to generate a detailed elevation map of the cornea. Processing this data using specialized software provides us with calculations for optimal correction through precision lens selection and placement of the Crystalens within the capsular bag."

Intensive Care

While the Crystalens surgery is essentially as brief and straightforward as typical cataract surgery,

the immediate postoperative period differs in key ways. "The lens takes several weeks to settle into perfect position; to some degree, the capsular bag must heal into place against the lens before it can begin to restore focusing power to the eye. We educate patients not to expect near vision to be perfect on day one. As time goes by, however, near vision typically improves dramatically in the implanted eye and improves even further once the second eye has received the Crystalens," Dr. Hamilton notes.

Postoperative care is also critical because the Crystalens sits in a very different position than a normal lens and must be closely monitored to ensure that it seats itself properly. Therefore, accuracy of the lens power selection and lens position within the eye are checked the day after Crystalens implantation in the first eye, and remeasured two weeks later. If no adjustments are needed, the second eye can be implanted, then assessed on day one, at week two, and again at one month.


Patient Viewpoint

Dr. Hamilton describes the patient experience of Crystalens surgery as also distinctive from other remedies for those with presbyopia. "Though LASIK and contact lenses can be very effective for patients who wish to avoid wearing glasses for distance and reading, these techniques are somewhat workarounds for the problem of presbyopia. They do not restore a dynamic focusing ability to the eye as does the Crystalens, which takes advantage of the documented fact that the ciliary muscle of the eye is still capable of functioning well into one's 80s. By replacing the aging lens of the eye with the Crystalens,

we can restore some of its dynamic focusing capability," he says.

Upcoming Attractions

Dr. Hamilton continues to scrutinize several other designs, some very different, for accommodating intraocular lenses currently in development or in clinical trials abroad. At this time, they offer too little near vision correction, or have yet to resolve technical issues related to implantation, healing, and scarring. "Once we have more experience with this technology and know more about its benefits and limitations on a large scale, an accommodative lens could potentially be something every cataract surgeon might use," he says.

Medicare currently disallows Crystalens replacement for anyone with a documented visually significant cataract, so most patients now seen at the Institute for Crystalens replacement are under 65 years of age. But Dr. Hamilton thinks accommodative lenses offer people who already need surgery for cataract replacement the added advantage of seeing things near, far, and in between, "thus restoring function to the eye in a way like no other. From that perspective, accommodating intraocular lenses give us an opportunity to provide a huge benefit to the patient." 

CRYSTALENS REFERENCES:

Doane JF. Accommodating intraocular lenses. *Curr Opin Ophthalmol* 2004; 15(1):16-21.

Cumming JS, Slade SG, Chayet A. AT-45 Study Group. Clinical evaluation of the model AT-45 silicone accommodating intraocular lens: results of feasibility and the initial phase of a Food and Drug Administration clinical trial. *Ophthalmology* 2001; 108(11):2005-9.

High Resolution Magnetic Resonance Imaging in Treatment of Severe Exotropia Following Scleral Buckling for Retinal Detachment

The following case report was submitted by Joseph L. Demer, M.D., Ph.D., Professor of Ophthalmology in the Pediatric Ophthalmology and Strabismus Division and Director of the Ocular Motility Laboratory in the Jules Stein Eye Institute.

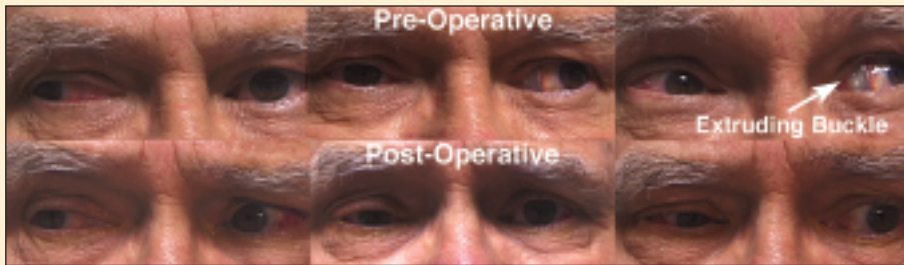

Figure 1. Clinical photos showing correction of severe exotropia.

Case 1

A 61-year-old man presented to the Jules Stein Eye Institute with horizontal, binocular diplopia following bilateral scleral buckling performed elsewhere for retinal detachments associated with high myopia. He had undergone scleral buckling on the left eye 4 years previously. Another retinal detachment occurred in the right eye 8 months before presentation, and was also corrected by scleral buckling. Corrected acuity was 20/20 in both eyes. On examination, there was 65 prism diopters left exotropia and 15 prism diopters left hypertropia (Figure 1 top). The scleral buckle was exposed and extruding nasally from left eye. Forced duction testing demonstrated mild restriction to full adduction of the left eye, but force generation testing detected no left medial rectus force. High resolution magnetic resonance imaging (MRI) was performed using high performance surface coils and optical fixation control in multiple gaze positions. Axial views (Figure 2 top) showed disinsertion of the left medial rectus muscle behind a large silicone explant, with the terminal tendon apparently adherent to the connective tissue along the posterior border of the explant. The right medial rectus muscle was normally inserted anterior to its buckle. By repeating the MRI scan in right and left gaze positions, normal contractile thickening was demonstrated for both medial rectus muscles in adduction.

Treatment

After approval of the original retinal surgeon, the exposed scleral buckle was removed through a nasal peritomy in one piece, recognizing from preoperative MRI that the junction of the buckle ends was located temporally (Figure 2 bottom). Guided by the imaging, the left medial rectus muscle was recovered and reinserted on an adjustable suture via a nasal conjunctival approach after scraping of the epithelialized bed of the exposed buckle. The right medial rectus muscle was resected 4 mm, and the lateral rectus muscles recessed 7 - 8 mm. After the second surgery, patient was orthotropic in all gaze positions (Figure 1 bottom).

Discussion

High resolution, multipositional MRI of the extraocular muscles can be clinically valuable in guiding the management of severe or complex strabismus, particularly when disinserted, lost, or traumatized muscles are suspected. Through long-term support of the National Eye Institute, Dr. Demer's laboratory at the Jules Stein Eye Institute has developed MRI hardware and clinical imaging protocols capable of achieving near microscopic resolution of the extraocular muscles and motor nerves. These methods employ standard clinical MRI scanners, surface coils that are available in most centers, and most importantly procedures optimized for extraocular muscle imaging. The techniques typically employed for MRI of the brain are not adequate for extraocular muscle imaging. In order to get MRI images of the quality illustrated here, the ophthalmologist must work very closely with the imaging facility.

Good quality orbital MRI in multiple gaze positions offers two clinical insights. First, the contractility of extraocular muscle bellies can be assessed by observing the degree of change in muscle size and shape in the deep orbit during contraction and relaxation. Contractile changes are easily evident even in muscles widely disinserted from the globe and therefore unable to exert rotational force on the eye.

(continued on page 4)

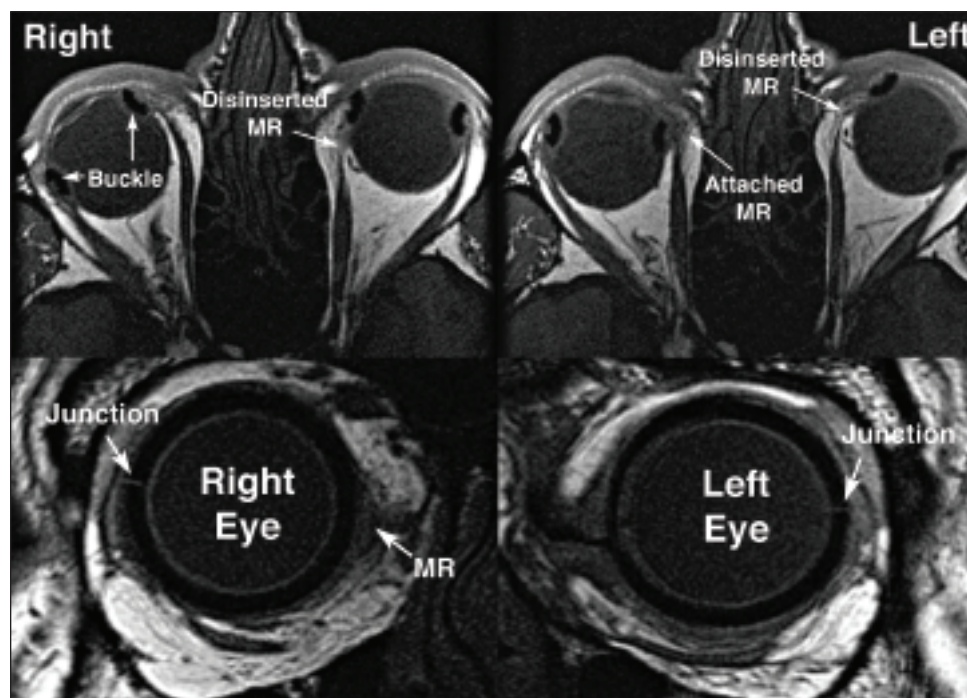

CASE REPORT: TREATMENT OF SEVERE EXOTROPIA *(continued from page 3)*

Figure 2. (Top) Axial MRI shows disinserted left medial rectus (MR) muscle. (Bottom) Coronal MRI revealed the junction of the buckle ends was located temporally.

serted for many years can function well after surgical recovery and reattachment. With modern orbital imaging and surgical techniques, disinserted extraocular muscles should no longer be regarded as “lost” when they are no longer inserted on the sclera. Extraocular muscle imaging consultations for this purpose can be arranged through the Jules Stein Eye Institute. 

Second, multipositional MRI can aid in determination of muscle attachment, since attached muscle insertions remain in constant spatial relationship with the globe during

ductions, and disinserted muscles do not. Reattachment of disinserted extraocular muscles can have gratifying clinical results. Even extraocular muscles that have been disin-

RECENT PUBLICATIONS

Demer, JL. A 12 year, prospective study of extraocular muscle imaging in complex strabismus. *J AAPOS* 2003; 6:337-47.

JSEI Continuing Education Programs & Grand Rounds Schedule 2004 – 2005



For information or to add your name to our distribution list, contact the Office of Academic Programs at (310) 825-4617 or visit our website at <http://www.jsei.org>

Jules Stein Eye Institute UCLA
100 Stein Plaza
Box 957000
Los Angeles, CA 90095-7000
U.S.A.

First Class Mail
U.S. Postage
PAID
UCLA