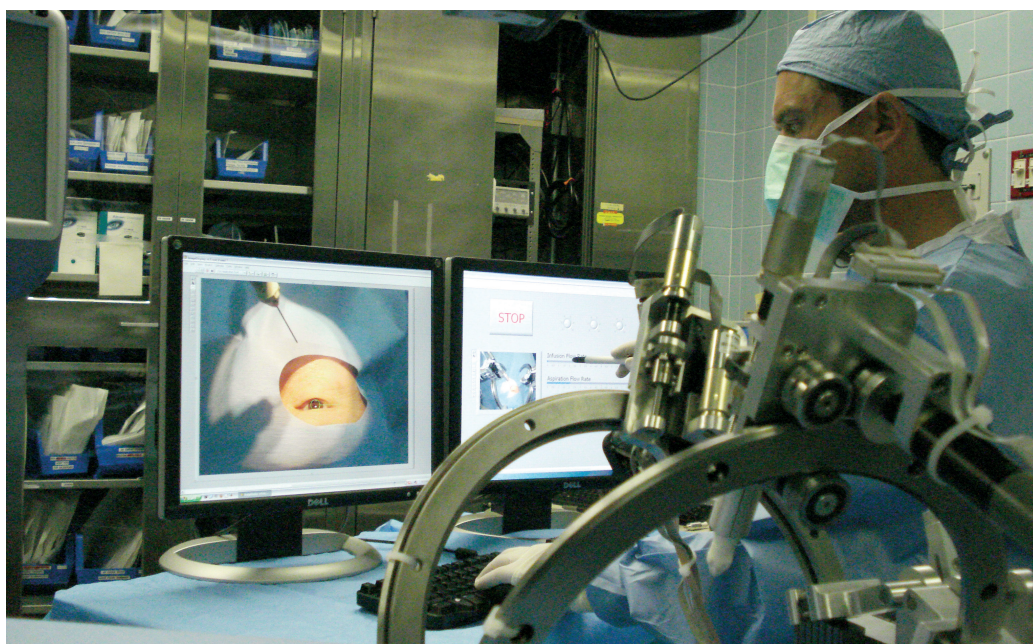


CLINICAL UPDATE



Dr. Jean-Pierre Hubschman and view of the current prototype of ocular robotic surgical platform.

Researchers Adapt Robotics for Ocular Surgery

The use of robotics has become increasingly popular among surgeons in many subspecialties. For minimally invasive procedures, such a system enables the surgeon to sit at a console with a three-dimensional view inside the patient as he or she manipulates robotic arms that grasp the instruments that carry out the surgery. These robotic arms act like human wrists, but with greater flexibility and precision: A system that filters out hand tremor, enables better range of motion, while the amplified stereoscopic, high-definition visualization system facilitates more exact movements.

The state-of-the-art *da Vinci* robotic system used at UCLA has been FDA-approved for a variety of interventions, including urological, gynecological, cardiac and general surgery procedures. Thus far, however, robotics has not

been suitable for ocular surgery. But that may soon change, thanks to a team that includes two Jules Stein Eye Institute scientists along with colleagues from the engineering school. They have developed the UCLA Intraocular Robotic Interventional Surgical System in an effort to use fully automated robotic surgery to decrease the complications and improve vision compared to the standard ocular surgical approach.

Adapting Existing System

Jean-Pierre Hubschman, MD, assistant professor in JSEI's Retina Division, has for the last four years been working with Steven D. Schwartz, MD, the division chief, and engineers at UCLA's Center for Advanced Surgical and Interventional Technology (CASIT) to adapt the *da Vinci* system for ocular surgery. "The *da Vinci*

continued on page 4

Erectile Dysfunction Drugs Impact on Ischemic Optic Neuropathy Studied

The Jules Stein Eye Institute is playing a key role in an international effort to determine whether there is a causal relationship between three major erectile dysfunction drugs and the development of nonarteritic anterior ischemic optic neuropathy (NAION).

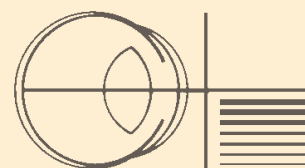
In recent years a number of case reports have been published in which individuals experienced visual loss from NAION after taking one of the phosphodiesterase (PDE)-5 inhibitors – sildenafil (Viagra), vardenafil (Levitra), and tadalafil (Cialis). In the wake of these reports, the U.S. Food and Drug Administration has required the three manufacturers (Pfizer, Bayer and Eli Lilly, respectively),

continued on page 3

May 2011
Vol.20 | No.2

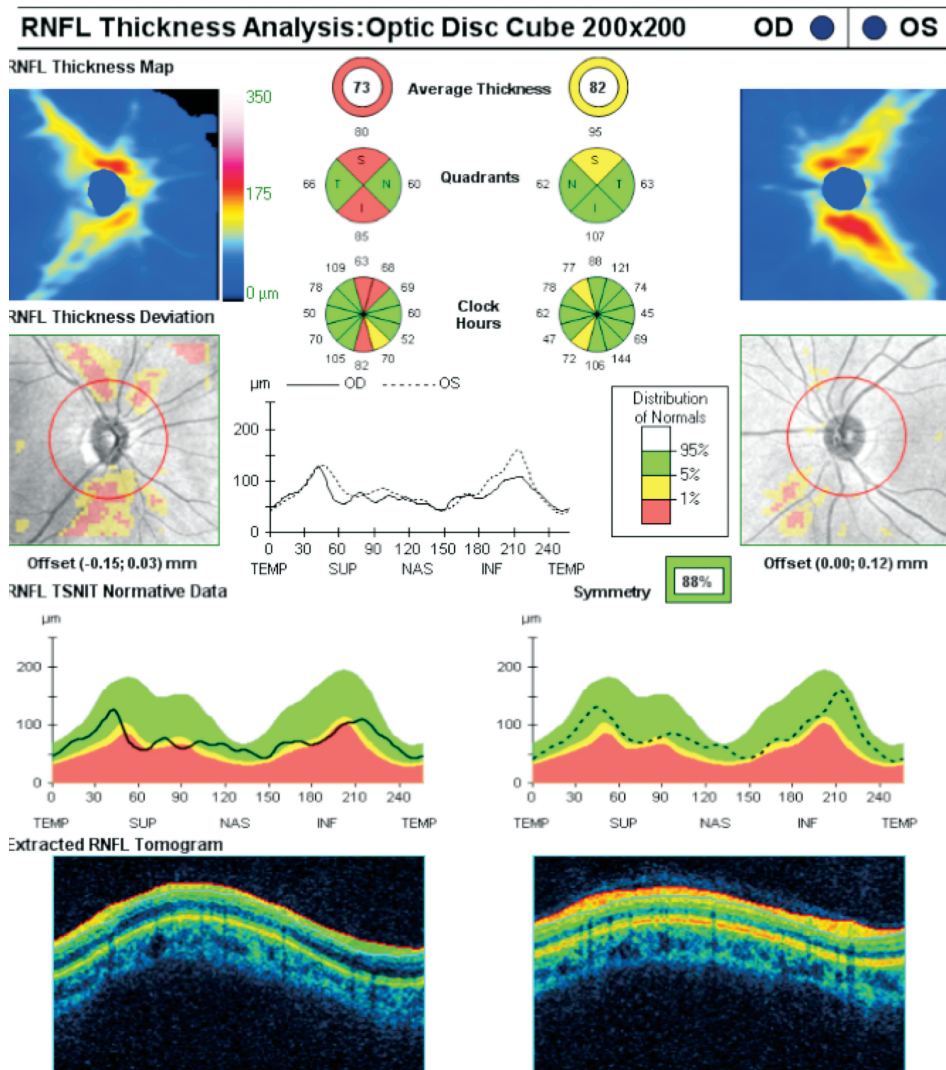
In This Issue

Robotic Surgery	Cover
Erectile Dysfunction Drugs	Cover
Spectral-Domain OCT	p. 2



JULES STEIN EYE INSTITUTE

Expanding Role of Spectral-Domain OCT in Glaucoma



An example of an SD-OCT printout. Some SD-OCT machines provide a cube of information (here a 6x6 mm area) instead of measurements only from a peripapillary circle, as in time-domain OCT. The right eyes show evidence of nerve fiber loss in both the superior and inferior regions.

A new imaging technology used at Jules Stein Eye Institute for measuring the retinal nerve fiber layer and optic nerve head in glaucoma patients may prove to have even wider benefits — potentially improving the way glaucoma is diagnosed and treated, according to Kouros Nouri-Mahdavi, MD, MSc, JSEI assistant professor of ophthalmology.

Spectral-domain optical coherence tomography (SD-OCT), a rapidly advancing tool, provides high-resolution cross-sectional imaging of the

optic nerve head (ONH), retinal nerve fiber layer (RNFL), retina and choroid. Although measuring the RNFL and ONH continues to be the main use of the SD-OCT machines in glaucoma, Dr. Nouri-Mahdavi notes that measurements of other ocular structures could shed light on the pathophysiology and structural changes in glaucoma. “Spectral-domain OCT may prove to be a valid tool for detecting structural glaucoma progression over time,” he says. “It could also help clinicians to better understand the disease.”

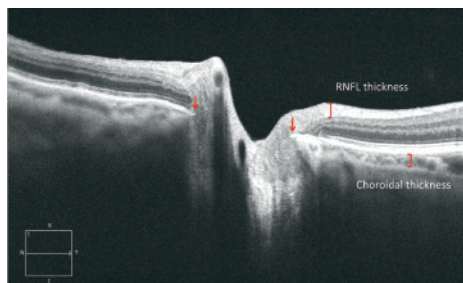
An OCT machine works similarly to B-scan ultrasound imaging, but uses light rather than sound waves, Dr. Nouri-Mahdavi explains. SD-OCTs, also called Fourier-domain OCTs, are based on simultaneous measurements of reflected light rays — varying within a narrow wavelength — by a spectrometer. “Compared to time-domain OCT, SD-OCTs have higher speed and better resolution,” says Dr. Nouri-Mahdavi. “This has led to less motion artifacts. SD-OCT has the ability to measure a more extensive area in the posterior pole, and the potential for imaging deeper tissues such as the choroid and peripapillary region. It is revolutionizing ocular imaging in glaucoma.”

A Promising Tool

SD-OCT has yet to prove to be superior to time-domain OCT for cross-sectional detection of glaucoma, Dr. Nouri-Mahdavi says. However, its most promising feature is its potential for detecting glaucoma progression — specifically RNFL thinning or neuroretinal rim loss — over time. A recent study suggested that SD-OCT can potentially detect a change of less than 5 microns in average RNFL thickness. Dr. Nouri-Mahdavi notes that there is also mounting evidence that measuring the macular ganglion cell complex (GCC: the total thickness of the RNFL, ganglion cells and inner plexiform layer) can be as sensitive as peripapillary RNFL measurements when it comes to differentiating between glaucoma patients and normal subjects.

Measuring the total retinal thickness in the posterior pole may also provide valuable diagnostic information. “There is still a significant amount of variability with RNFL or GCC measurements,” Dr. Nouri-Mahdavi says. “The total retinal thickness provides more robust measurements because the anterior and posterior borders of the retina are easier to delineate automatically. Any change over time in the retinal thickness is then presumed to be due

Below: A high-definition linear scan passing through the disc. All retinal layers can be delineated with fair precision. The edge of the Bruch's membrane forms the border of the disc in this eye (arrows). The RNFL and choroidal thickness can also be measured with high precision.



to thinning of the RNFL or GCC, assuming that no retinal pathology has occurred.”

Thanks to the higher resolution provided by SD-OCTs, Dr. Nouri-Mahdavi and his colleagues are also gaining a better understanding of the peripapillary changes in glaucoma. “We can now better delineate the extent and type of

peripapillary atrophy and determine where the true border of the disc is located,” Dr. Nouri-Mahdavi explains.

Better Understanding Glaucoma

The new imaging technology opens the door to a variety of studies that could assist clinicians through a better understanding of glaucoma's pathophysiology. Dr. Nouri-Mahdavi notes that laboratory studies have confirmed that in most subjects, the edge of the Bruch's membrane forms the true border of the ONH, while in a minority of subjects, the border tissue of Elschnig is what clinicians determine to be the ONH edge. The measurement of choroidal thickness in glaucoma provides another potentially fruitful

area of research. “The choroid is a very dynamic vascular structure,” says Dr. Nouri-Mahdavi. “Its thickness varies with each heartbeat, breathing, posture and eye pressure, among other factors. We are just beginning to understand the role of choroidal expansion in angle closure glaucoma as a result of the information gleaned from enhanced depth SD-OCT imaging.”

Dr. Nouri-Mahdavi is optimistic about the progress that can be made for the benefit of glaucoma patients. “The imaging revolution is just in its infancy,” he says. “We should soon have exciting new knowledge available that could improve the way we diagnose and manage glaucoma.”



Erectile Dysfunction Drugs *continued from cover*

to evaluate whether there is a causal link between their drug and NAION risk. The FDA also called for the companies to include information on NAION on the drug labels. NAION is characterized by an acute, painless loss in the visual field associated with optic nerve swelling (see photo). There is no effective treatment, and the damage is typically irreversible, notes Anthony C. Arnold, MD, chief of JSEI's Neuro-Ophthalmology Division.

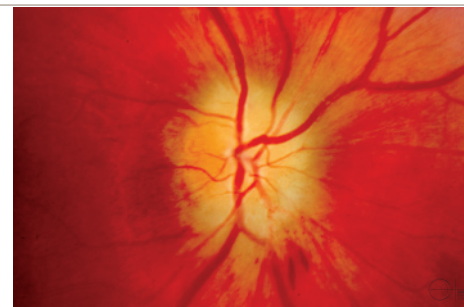
Unclear Whether Link Is Causal

The possibility that there is a causal link between the PDE-5 inhibitors and NAION is based on both the temporal relationship in some of the cases — between 30 minutes and 36 hours from the time the individual took the drug — and a suggested mechanism for the effect. “The theory is that the drugs lower blood pressure, so that in certain people who might be predisposed to the disorder, there is not enough blood flow to the optic nerve,” Dr. Arnold explains. “These individuals would already have some disease of the blood vessels in the optic nerve, and this drop in blood flow would create what is effectively a small stroke in that area.”

Dr. Arnold notes that while this is a sound theory for why the drugs might increase the risk for NAION, it is not clear whether it's a cause-and-effect relationship. “The problem is that no one actually checks the blood pressure before development of the disease to document that it was actually low,” he says, “and we have no way of imaging the blood vessels in the optic nerve to see whether they're blocked.” Further clouding the issue, Dr. Arnold explains, is that the major risk factors for the development of NAION are the same as those that would lead individuals to use the erectile dysfunction drugs – diabetes, hypertension, coronary artery disease, smoking and hyperlipidemia.

JSEI Playing Key Role in Study

Clarity on whether there is a significant link between using the medication and developing the disease is expected to come from the new studies, the first and largest of which is being funded by Pfizer. Dr. Arnold is one of the key advisers for the study, and JSEI is one of more than 125 participating centers in the United States and other countries. The Pfizer study, which began in 2008, will recruit as many as



Color fundus photograph of the optic disc in acute NAION; optic disc edema and flame hemorrhages are present.

1,000 patients who develop the disease, and then analyze their medication use. “It's a large epidemiologic analysis that will assess with the best certainty whether there is a risk of developing ischemic optic neuropathy from taking the drug,” Dr. Arnold says. Recruitment is estimated to be completed by 2013, after which JSEI will also participate in the data analysis.

Until then, Dr. Arnold says, caution in taking one of the PDE-5 inhibitors is recommended for certain patients. These include those who have already had ischemic optic neuropathy in one eye. Individuals who develop NAION within a day of taking the drug are advised to stop using it.





AARP The Magazine ranks Jules Stein Eye Institute as No. 3 in the country for complex eye-care referrals.



Please recycle

Robotic Surgery continued from cover

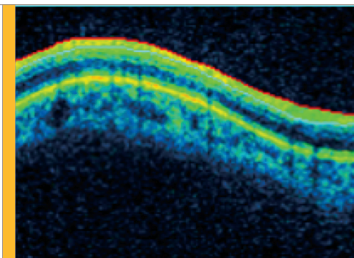
was designed for laparoscopic surgery, and we found that the instruments were too bulky to be used in the eye,” explains Dr. Hubschman. “We had to redesign the hardware to make it work for this type of microsurgery.”

To better understand the specifications that would be needed for the new robots, the researchers conducted a study in which they placed sensors on surgical instruments to learn the range and speed of motion during cataract surgery and vitrectomy. With that information, they began building a robot dedicated to eye surgery, including the hardware, visualization system, joystick to control the robot, and the software to make it all work together.

The new system, which will integrate scanning laser incisional technologies into the robotic program, is now ready for testing in the laboratory as the researchers continue to lay the foundation for clinical trials.

Dr. Hubschman explains that for intraocular surgery, the advantages associated with the robotic approach are somewhat different from those of other surgeries. “We already have a stereoscopic view of the surgical target, we are seated comfortably during the surgery, and we have great maneuverability,” he says. “The main benefit for intraocular surgery is the automation. The robot will be able to analyze the situation every hundredth of a second and provide ‘real time’ feedback for a safer intraocular surgery.”

Cataract surgery is one of the most common surgeries in the world; more than 3 million are performed each year in the United States. “In 10 years we can foresee using a femtosecond laser to cut the cornea, do a capsulorhexis and slice the lens, then the robot can aspirate the pieces of the lens that were cut and implant them,” Dr. Hubschman says. “We believe this is the future and that it will revolutionize cataract and other types of ocular surgery in the next 10-15 years.”



JULES STEIN EYE INSTITUTE

CLINICAL UPDATE

MAY 2011
VOL. 20 | NO. 2

DIRECTOR

Bartly J. Mondino, MD

MANAGING EDITOR

Gloria P. Jurisic

CONTRIBUTOR

Dan Gordon

DESIGN

Hada-Insley Design

JSEI Continuing Education Programs & Grand Rounds

For information, or to add your name to our distribution list, contact the Office of Academic Programs at (310) 825-4617, visit our website at www.jsei.org, or email ACProg@jsei.ucla.edu.

For inquiries about Clinical Update, contact JSEI Marketing & Contracting, 100 Stein Plaza, UCLA, Los Angeles, CA 90095-7000; email: jurisic@jsei.ucla.edu

Copyright © 2011 by The Regents of the University of California.
All rights reserved.