
FOUNDATION LECTURE

TOTAL THYROIDECTOMY: THE EVOLUTION OF SURGICAL TECHNIQUE

LEIGH DELBRIDGE

University of Sydney Endocrine Surgical Unit, Royal North Shore Hospital, Sydney, Australia

The present paper outlines the development of thyroid surgery from early times to the twenty-first century. The significant changes that have occurred in the past few decades in relation to the evolution of techniques for safe and effective total thyroidectomy are then summarized. In the last 25 years total thyroidectomy has replaced bilateral subtotal thyroidectomy as the preferred option for the management of all patients with bilateral benign multinodular goitre, Graves' disease, and all but very low-risk thyroid cancer patients. The principal change in operative technique has been the move from 'lateral dissection' to 'capsular dissection'. Associated with that has been a focus on 'encountering' the recurrent laryngeal nerve (RLN), recognizing sympathetic-laryngeal nerve anastomoses, and routinely identifying the external branch of the superior laryngeal nerve (EBSLN). Completeness of resection has been assured by moving from an anatomically based approach to an embryologically based approach. This requires an awareness of the vagaries of thyroid development including attention to pyramidal remnants, to abnormalities associated with the tubercle of Zuckerkandl, and to thyrothymic thyroid rests. Preservation of parathyroid function has moved from the time-consuming technique of dissection of a vascularized pedicle in all cases, to initially selective, and then routine, parathyroid autotransplantation. These changes have ensured that total thyroidectomy can now be offered as a safe and efficacious procedure with a minimal complication rate.

Abbreviations: EBSLN, external branch of the superior laryngeal nerve; RLN, recurrent laryngeal nerve; SILAB, sympathetic-inferior laryngeal nerve anastomotic branch; UCI, Unit of Clinical Investigation.

EARLY DEVELOPMENT OF THYROID SURGERY

Despite the many early reports of surgery for 'struma', it is likely that most of these procedures were actually for tuberculous cervical lymph nodes. However, these early surgeons were still very much aware of the anatomy of the region, with Paul of Aegina warning of damage to 'carotid arteries and nerves recurrentes' during such procedures. The first credible descriptions of thyroid surgery came from the School of Salerno in thirteenth century, although the techniques used were restricted to the use of a setons and hot irons, with asphodel powder applied to the remnant.¹ The first well documented 'anatomical' total thyroidectomy was performed by Guillaume Dupuytren in Paris in 1808. He described dividing all four arteries and removing the goitre by sharp dissection. There was little blood loss but, unfortunately, the patient died of 'shock'. By 1850, there had been 14 successful partial or total thyroidectomies reported across Europe.¹ Nonetheless the procedure retained a poor reputation. Samuel Gross wrote in 1866: 'if a surgeon should be so adventurous or foolhardy as to undertake thyroidectomy, every step he takes will be environed with difficulties, every stroke of his knife will be followed by a torrent of blood, and lucky will it be for him if his victim lives long enough to enable him to finish his horrid butchery ... no honest and sensible surgeon, it seems to me, would ever engage in it'.²

This paper was delivered as the Foundation Lecture, Section of Endocrine Surgeons, Royal Australasian College of Surgeons ASC, Adelaide 2002. It is dedicated to Emeritus Professor T. S. Reeve, FRACS, CBE, AC, mentor, colleague and friend.

L. Delbridge MD, FRACS.

Correspondence: Professor Leigh Delbridge, University Department of Surgery, Royal North Shore Hospital, St Leonards, NSW 2065, Australia.
Email: leighd@med.usyd.edu.au

Accepted for publication 2 January 2003.

The era of modern thyroid surgery was introduced by Theodore Billroth. Initially, in Zurich, he had a mortality of 40% and so abandoned the procedure. However, by 1877 he had moved to Vienna and many of the problems of sepsis had been resolved. He was then able to report thyroidectomy with a mortality of only 5%. Billroth preferred conservative 'subtotal' operations but still had a significant morbidity with 36% recurrent laryngeal nerve damage; although hypothyroidism and tetany were rarely, if ever, seen. However, safe and effective thyroid surgery came of age with Theodore Kocher, Professor of Surgery in Berne. He used the technique of capsular dissection and by 1883 had reported 101 cases including 18 total thyroidectomies. In that report he noted, having recalled all his patients, that those who had had total excision of their glands were not thriving and had what he termed 'cachexia strumipriva', a condition he attributed to chronic asphyxia. In reality he was describing hypothyroidism; nonetheless, he abandoned total thyroidectomy at that stage. By 1895 he had reported 900 thyroid procedures with a mortality of only 1% and minimal morbidity.¹ He received the Nobel Prize in 1909 – the first surgeon ever to do so.

Australia was a leading centre for thyroid surgery in the early twentieth century. By 1911 Thomas Dunhill had reported 230 consecutive cases of exophthalmic goitre from St Vincent's Hospital in Melbourne with only three deaths. He pioneered the technique of lobectomy together with removal of half to two-thirds of the contralateral lobe at the same procedure – the 'Dunhill Procedure'; but he almost never performed a total thyroidectomy.³ Subtotal thyroidectomy progressively became the standard procedure worldwide for dealing with bilateral benign thyroid disease. In centres such as the Mayo Clinic, which had reported a staggering 37 668 thyroid procedures performed by 1935, subtotal thyroidectomy remained the definitive treatment for Graves' disease and nodular goitre.²

In Sydney, Frank Rundle, a student of Sir Cecil Joll, was instrumental in the formation of the 'Unit of Clinical Investiga-

tion' (UCI) at Royal North Shore Hospital in 1950.⁴ The UCI was a major influence in the introduction of ¹³¹I as an agent for both the diagnosis and treatment of thyroid disease. In 1956 Thomas Reeve was appointed to what had now become a Teaching Hospital of the University of Sydney and by the 1960s and 1970s the unit was performing between 300 and 400 thyroid procedures each year. The mainstay of surgery in those times was bilateral subtotal thyroidectomy for Graves' disease and benign multinodular goitre.^{5,6} Total thyroidectomy was reserved for the management of thyroid cancer. While subtotal thyroidectomy was an effective procedure for benign thyroid disease, there were problems: surgery for recurrent nodular goitre was common, comprising up to 25% of cases at its peak, and significant numbers of patients returned with persistent symptoms caused by posterolateral thyroid remnants often lying behind the trachea or oesophagus⁷ (Fig. 1). Subtotal thyroidectomy for Graves' disease, although practiced in the unit for nearly 40 years, was associated with a recurrence rate of 5% and long-term remnant failure of 72%.⁸

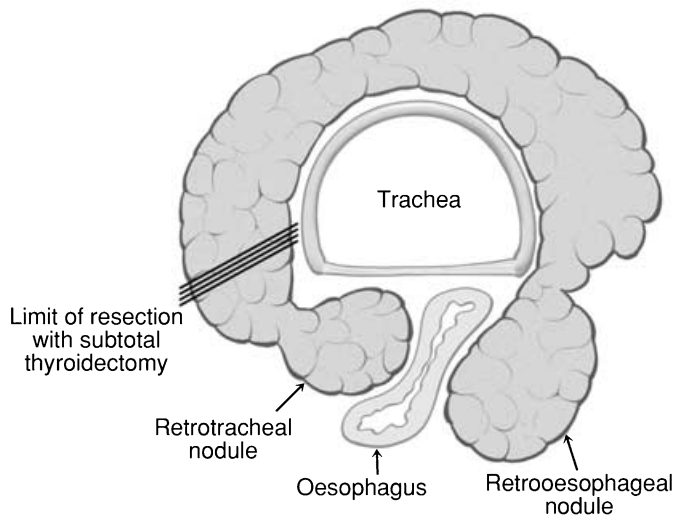


Fig. 1. Posteriorly placed thyroid nodules potentially left behind because of limited posterolateral dissection during subtotal thyroidectomy.

EVOLUTION OF TECHNIQUE FOR TOTAL THYROIDECTOMY

By 2002, total thyroidectomy had become the standard procedure in the unit at Royal North Shore Hospital for all patients with benign bilateral multinodular goitre, all patients with Graves' disease and all except very low-risk thyroid cancers (i.e. those patients with low-risk papillary cancer or papillary microcarcinomas found incidentally on histopathological examination, or those patients having hemithyroidectomy for follicular neoplasms where the final pathology was reported as a minimally invasive follicular cancer with capsular invasion only). Associated with that change in philosophy over 25 years was a major evolution of surgical technique, with the result that total thyroidectomy can now be offered as a safe and efficacious procedure, with minimal complications and improved outcomes. Those changes are summarized in Table 1.

THE TECHNIQUE OF CAPSULAR DISSECTION

In the 1970s the standard approach to the thyroid gland was to identify, very early in the procedure, the recurrent laryngeal nerve (RLN) as it lay in the tracheo-oesophageal groove. The nerve was then dissected throughout its entire length to the cricopharyngeus, removing all tissue medially while attempting to preserve the vascular supply of the parathyroid glands in the process. There were two major problems with this approach: first, the blood supply to the parathyroid glands is very much at risk with removal of all tissue medial to the RLN, even when the vascular pedicle to each gland is identified and carefully dissected; second, extensive dissection and exposure of the RLN may place it at greater risk of neuropraxia because of interference with the blood supply to the vasa nervorum along its length. Capsular dissection, as previously described,^{9,10} involves commencing the lateral component of the dissection high on the surface of the thyroid gland (Fig. 2), dividing only the tertiary branches of the inferior thyroid artery and progressing posteriorly. In the process the vascular supply of the parathyroid glands is often well preserved and minimal dissection and exposure of the RLN is the rule.

'Encountering' the RLN

The RLN is thus 'encountered', usually close to the ligament of Berry, rather than being dissected along its entire length. This

Table 1. Evolution of the surgical technique of bilateral thyroidectomy over the past 25 years

	1970s	Today
Preferred operation	Bilateral subtotal thyroidectomy	Total thyroidectomy
Technique	Lateral dissection	Capsular dissection – 'Encountering' the recurrent laryngeal nerve (RLN) – Recognizing sympathetic-laryngeal nerve anastomosis (SILAB) – Routinely identifying the external branch of the superior laryngeal nerve (EBSLN)
Completeness of resection	Anatomical approach	Embryological approach – Thyroglossal tract and pyramidal remnants – Thyrothymic thyroid rests – The tubercle of Zuckerkandl
Parathyroid preservation	Preservation <i>in situ</i>	Autotransplantation – Selective autotransplantation – Routine autotransplantation

manoeuvre reduces the potential for neuropraxia from prolonged dissection of the nerve, as well as focusing attention on the real 'danger area' for the nerve, namely the ligament of Berry. Identification of the recurrent nerve early on in the tracheo-oesophageal groove can lull the less-experienced surgeon into a false sense of security ('I've already seen the nerve') when the site of greatest risk of damage to the nerve has yet to be approached. 'At risk' nerves stretched over the capsule of the thyroid are also more likely to be safely encountered and preserved than by attempting to locate them in a more lateral plane initially.

Recognizing sympathetic-laryngeal nerve anastomoses

Although occasional direct connections between cervical sympathetic ganglia and the RLN (sympathetic-inferior laryngeal nerve anastomotic branch or SILAB) have been well described previously,^{11,12} it is now appreciated that very fine direct anastomoses from the sympathetic ganglia to both the RLN as well as the external branch of the superior laryngeal nerve (EBSLN), and then on to the substance of the thyroid gland, are very common if not universal (Fig. 3). It has been reported¹³ that up to 2% of SILAB are larger than the RLN and may thus be mistaken for a non-recurrent laryngeal nerve, thus placing the true RLN at risk of division. If there is any doubt about the nature of apparent anastomotic branches they should be traced back laterally. A non-recurrent laryngeal nerve will arise from the vagus whereas a SILAB will usually arise from the middle cervical ganglion, or occasionally from the inferior or superior ganglia. Occasionally a sympathetic branch from the superior cervical ganglion, hitchhikes along the EBLN and then communicates via a further branch to the RLN along with the 'nerve of Galen', although this nerve itself is thought to contain primarily sensory and some motor fibres. Branches also leave the RLN passing directly into the substance of the thyroid gland. While any such branch appearing to pass into the thyroid should be carefully examined in order to avoid dividing a small true anterior branch of the RLN,

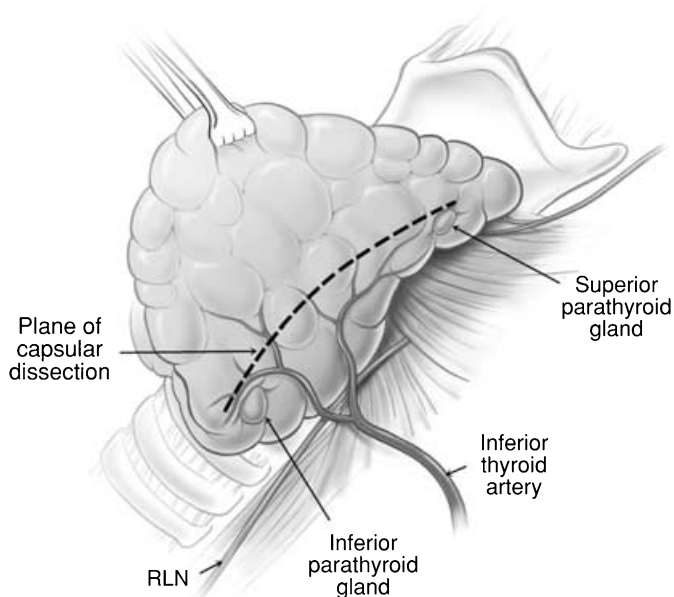


Fig. 2. Plane of commencement of capsular dissection as indicated by the dotted line on the thyroid surface.

recognition of the existence of sympathetic anastomoses is vital during thyroid dissection.

Routinely identifying the EBSLN

The EBSLN has been labelled 'the neglected nerve' of thyroid surgery.¹⁴ Most surgeons have simply attempted to avoid this nerve on the assumption that so doing will prevent injury; however, it is now recognized that injury is relatively common and associated with the potential for significant impairment, especially for those who use their voices professionally. The policy in our unit has always been to attempt to identify the nerve, although previously this was only achieved in 60% of cases.¹² Recently Aina and Hisham have shown that the nerve can be routinely identified in over 90% of cases,¹⁵ a level that sets a new benchmark for endocrine surgeons. The key to identifying the nerve is to develop the avascular plane between the cricothyroid muscle and the medial border of the upper pole of the thyroid lobe, a manoeuvre facilitated by lateral retraction of the lobe¹⁶ (Fig. 4). Awareness of the various positions of the EBSLN according to the Cernea classification is also essential if the nerve is to be both identified and preserved.¹⁷ Type 1 EBSLN are located well clear of the thyroid, more than 1 cm above the upper pole of the lobe passing directly into the cricothyroid muscle (Fig. 5a). Type 2a nerves pass in the vicinity of the superior thyroid vessels as they enter the gland substance, and Type 2b nerves cross over the anterior surface of the thyroid lobe (Fig. 5b). Awareness of the anatomic variations, such as the nerve of Galen, a direct communication between the RLN and EBSLN, is important in avoiding injury to the nerve.

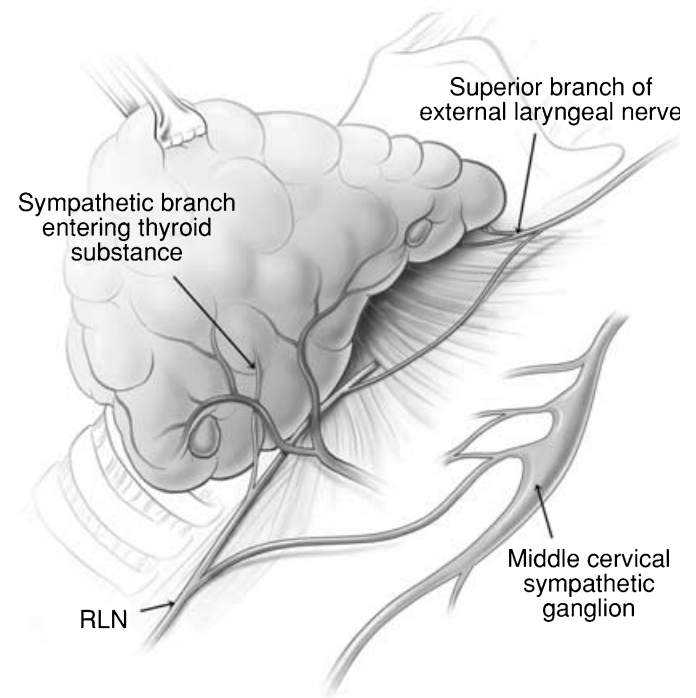


Fig. 3. Sympathetic connections between the cervical sympathetic ganglia, the recurrent laryngeal nerve and the thyroid gland. The connection between the recurrent laryngeal and the external branch of the superior laryngeal nerve (nerve of Galen) is also shown.

ENSURING COMPLETENESS OF RESECTION

The technique of subtotal thyroidectomy formerly employed relied on the anatomical removal of visibly abnormal thyroid tissue, leaving behind bilateral posterior remnants. The move to total thyroidectomy has meant not only that more thyroid tissue is now removed, but that rather there has been a progressive awareness of the vagaries of embryological development of the thyroid,

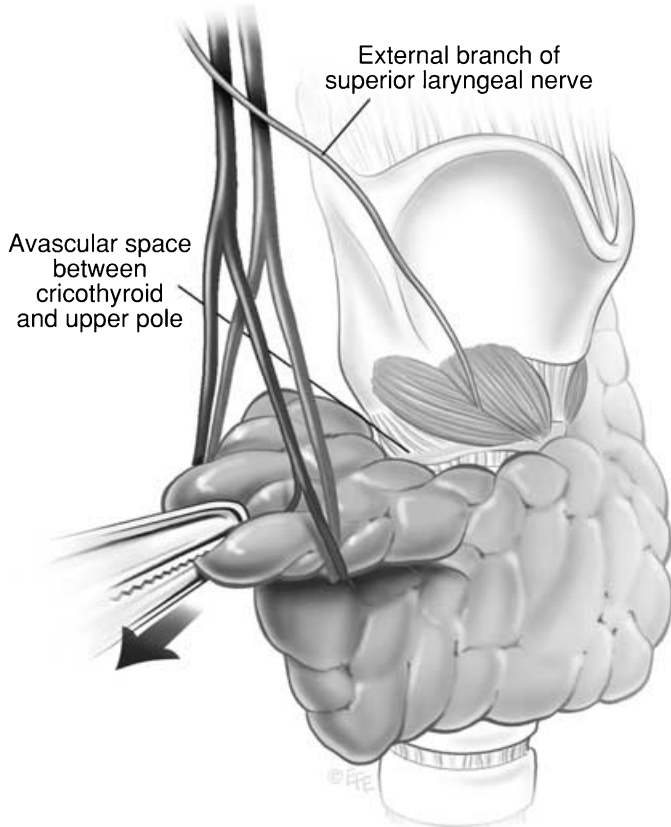


Fig. 4. Lateral retraction of the upper pole of the thyroid lobe in order to open up the avascular space between the lobe and the cricothyroid muscle, thus exposing the external branch of the superior laryngeal nerve.

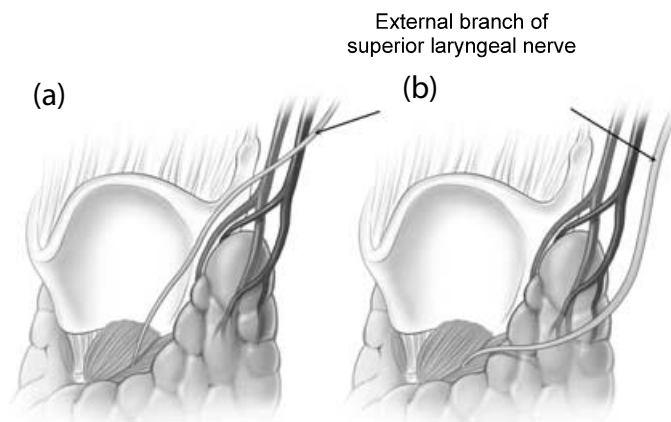


Fig. 5. (a) Type 1 EBSLN passing more than 1 cm above the upper pole; (b) type 2b EBSLN passing over the anterior surface of the thyroid lobe.

with dissection now focused on those changes in order to ensure completeness of resection, and thus efficacy of the procedure. Thyroid development (Fig. 6) involves the midline descent of thyroid tissue from the foramen caecum to the level of the larynx along the thyroglossal tract, at which stage the left and right lobes develop.¹⁸ What is not as well appreciated is that thyroid descent may well continue into the thyrothymic region (and even into the anterior mediastinum) forming a prolongation of thyroid tissue or even completely separate thyrothymic thyroid rests.¹⁹ In addition the lateral thyroid component arising from the 4th branchial cleft and ultimobranchial body fuses with the median component to form the tubercle of Zuckerkandl, a distinct anatomical structure.²⁰ This fusion is not only the source of the thyroid's C-cells, but is also essential in the process of follicular development.

Thyroglossal tract and pyramidal remnants

Routine dissection of the pyramidal area up to the laryngeal cartilage should be part of every total thyroidectomy. Even minimal recurrence in this area can be very apparent to the patient. More importantly, in patients with Graves' disease, a small pyramidal

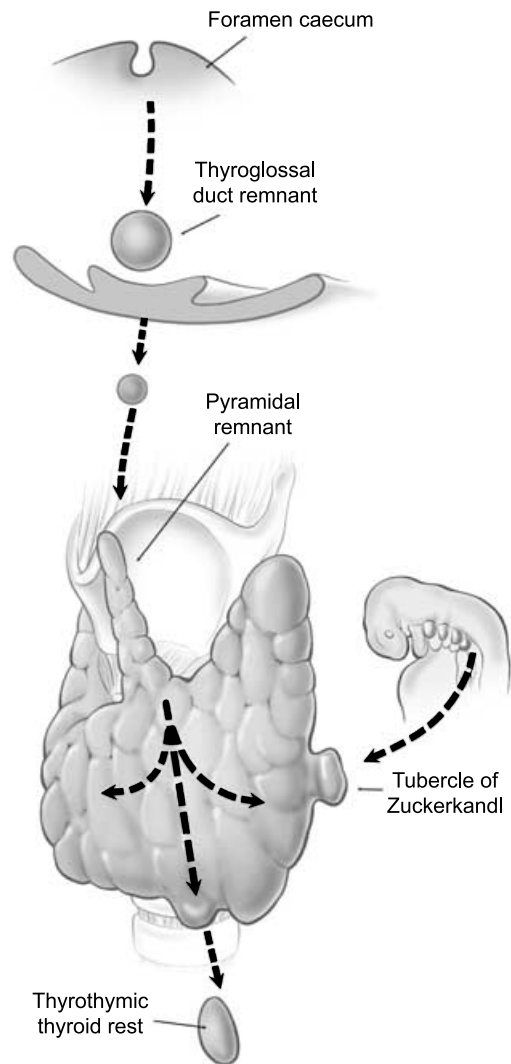


Fig. 6. Embryological development of the thyroid gland.

lobe remnant can contain sufficient thyroid tissue to cause clinical recurrence even after an apparent 'total' thyroidectomy.

Thyrothymic thyroid rests

Thyrothymic thyroid rests are present in over 50% of patients (if looked for), although most are small. They are often mistaken for small lymph nodes, or even parathyroid glands, and mostly cause no real problems. They are classified according to the nature of their connection to the thyroid gland proper (Fig. 7). Grade I is a protrusion of thyroid tissue from the lower edge of the thyroid lobe, grade II is a thyroid rest connected by a bridge of thyroid tissue while grade III is connected by only a fibrovascular core. Grade IV has no connection at all with the thyroid proper. Their clinical significance lies in the fact that, if not removed at the initial operation, they may well reappear as retrosternal recurrence after apparent 'total' thyroidectomy.^{21,22} Routine dissection of the thyrothymic area down to the thoracic inlet looking for such rests should therefore be part of every total thyroidectomy.

The tubercle of Zuckerkandl

This structure, first described by Zuckerkandl in 1902, is a distinct anatomical entity, and can be found in nearly two-thirds of patients undergoing thyroid surgery.²⁰ It is classified according to size (grades 0–3) using a system developed by Pelizzo *et al.*²³ The tubercle of Zuckerkandl is often the source of local pressure or obstructive symptoms, especially when the thyroid itself is relatively small. The importance of the tubercle of Zuckerkandl, once again, is that if not looked for and removed during thyroid surgery, it may be a source of persistent unrelieved symptoms or recurrence.

An understanding of the anatomy of the tubercle of Zuckerkandl is also central to safe surgical dissection. It usually enlarges lateral to the RLN, with the nerve appearing to pass into a cleft medial to it – a situation that some surgeons used to describe as the nerve passing into the thyroid substance (Fig. 8). Early elevation of the tubercle of Zuckerkandl usually allows the recurrent nerve to be easily and safely 'encountered' even though not initially visible. However, an uncommon but high risk situation is where the RLN runs lateral to an enlarged tubercle of Zuckerkandl, placing it at increased risk of damage during dissection. Another important point is that the normal superior parathyroid gland, also being derived from the fourth branchial cleft, is commonly found in close association, cephalad to the tubercle of Zuckerkandl (Fig. 8).

PARATHYROID PRESERVATION

For many years, the fundamental principle of parathyroid preservation during thyroid surgery had been to maintain all the parathyroids *in situ* on a vascularized pedicle. In addition there was a belief that any parathyroid apparently preserved, which maintained a tan colour, was viable and could thus be left intact. Although the incidence of permanent hypoparathyroidism has always been acceptably low in our unit^{24,25} it still occurred in 1–2% of cases, presumably because of late or unrecognized ischaemia of the preserved parathyroid glands. It is now recognized that, not only is dissection of parathyroid glands on a vascularized pedicle a very time consuming process, especially for those situated high on the thyroid surface, but it does not necessarily guarantee their preservation. Many a parathyroid gland that has been painstakingly dissected on a long pedicle simply infarcts later on as a result of thrombosis of the tenuous vascular supply, or as a result of oedema and swelling of the gland within its dissected capsule.

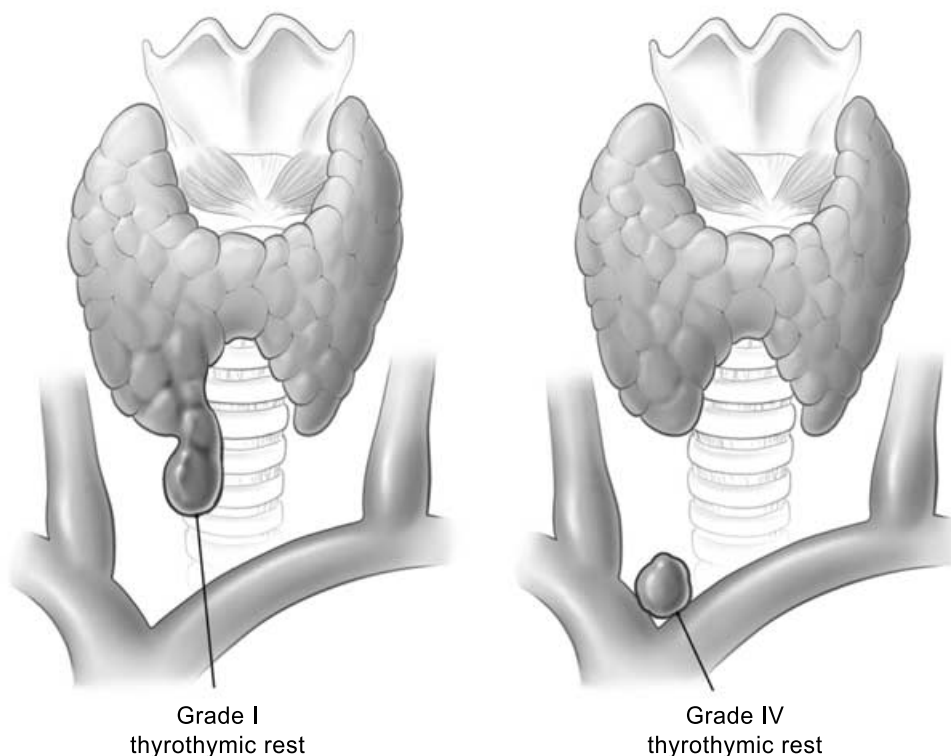


Fig. 7. Examples of grade I and grade IV thyrothymic thyroid rests.

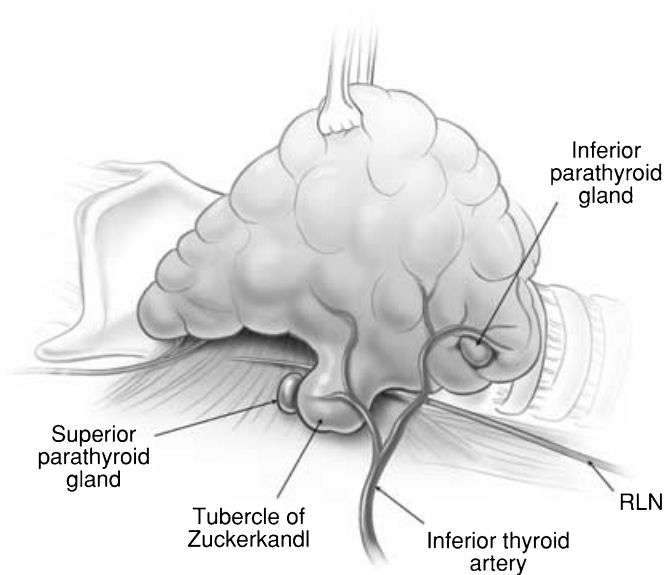


Fig. 8. The most common relationship of the tubercle of Zuckerkandl to the recurrent laryngeal nerve and the superior parathyroid gland.

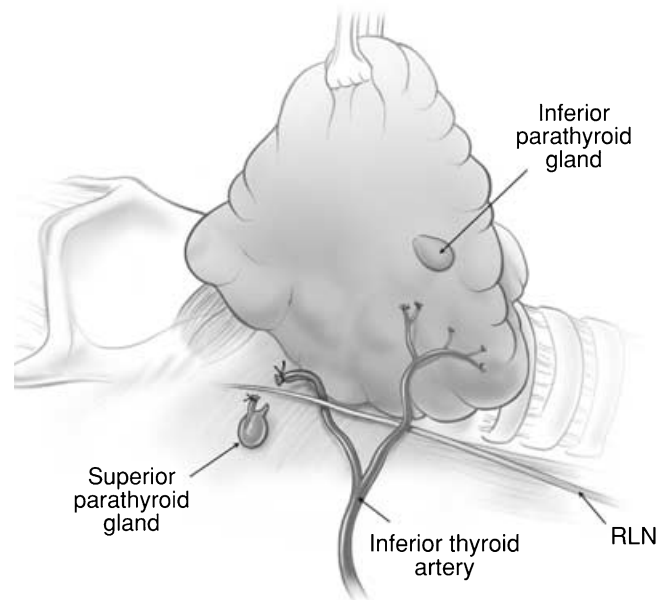


Fig. 9. Parathyroid glands requiring autotransplantation, the inferior parathyroid due to anatomical location and the superior gland due to devascularization following dissection of the recurrent laryngeal nerve.

Selective parathyroid autotransplantation

Although there had been sporadic reports of parathyroid autotransplantation, it has only been in the last 20 years, after Wells confirmed both biochemically and clinically the success of parathyroid autotransplantation in a large series of patients undergoing parathyroidectomy²⁶ that the technique has become used. In fact, only in recent times has it really become accepted as part of routine clinical practice during total thyroidectomy. The initial approach of the unit was to selectively autotransplant any parathyroid gland that was difficult to dissect or was of dubious viability after dissection. It was during this stage that it was recognized that not all 'tan' parathyroids are viable. Venous obstruction in association with pedicle ligation will lead to the classic 'black' ischaemic parathyroid; however, isolated ligation of the end artery to a parathyroid gland will often lead to the gland becoming ischaemic while remaining tan. This led to the use of the 'knife' test where the capsule of dubious parathyroid glands is carefully incised – the absence of capillary oozing is an additional indication for autotransplantation.

Parathyroid autotransplantation can be readily achieved by the 'injection technique'.²⁷ Each parathyroid gland removed for autotransplantation is made into a suspension of parathyroid cells in 2-mL buffered saline by mincing with scissors. The suspension can then easily be injected into the ipsilateral sternomastoid muscle with a blunt vial access pin (Micro Pin MP-100, Braun, Melsungen, Germany).

Routine parathyroid autotransplantation

Although most authors still favour the approach of selective ('ready') parathyroid autotransplantation,²⁸ the unit has now adopted routine autotransplantation, a philosophical approach based on the understanding that while parathyroid autotransplantation is very effective, the viability of *in situ* vascularized parathyroids remains unpredictable with late ischaemia always a

possibility. The routine autotransplantation of at least one parathyroid gland during every total thyroidectomy, while unnecessary in most cases, provides insurance in cases where late ischaemia of the remaining glands actually occurs.²⁹ The parathyroid gland chosen for routine autotransplantation is either one determined to be non-viable on the basis of anatomical location (Fig. 9) or a failed knife-test, or else the least viable appearing of the remaining *in situ* glands. Routine autotransplantation will be associated with an increase in the rate of temporary hypocalcaemia in the short term²⁸ but has, in theory, the potential to reduce permanent hypoparathyroidism to zero.²⁹

THE FUTURE

Total thyroidectomy, based on the principles described in this paper, has now become the preferred option for all patients presenting with bilateral benign multinodular goitre³⁰ Graves' disease³¹ and most patients with thyroid cancer.^{32,33} The only exceptions to total thyroidectomy are patients with single thyroid nodules requiring diagnostic lobectomy, patients with nodular disease macroscopically confined to one lobe³⁴ or selected patients with very low-risk thyroid cancer (either incidentally discovered papillary cancer³⁵ or minimally invasive follicular thyroid cancer without evidence of vascular invasion³⁶). It is a procedure which can be performed with safety and efficacy not only within specialized endocrine surgical units, but also by well trained general surgeons in provincial centres³⁷ as well as by trainees.³⁸ Our unit was one of the pioneers of the philosophical approach of total thyroidectomy for the management of benign thyroid disease, with one of the very first ever publications recommending total thyroidectomy for multinodular goitre having come from the unit.³⁰ In so doing, Kocher's original ideas and technical approach to capsular dissection and complete removal

of the thyroid for benign disease – an approach he abandoned for the wrong reasons – have been rediscovered. Endocrine surgeons around Australia³⁹ and throughout the world have increasingly adopted this approach. Indeed in an editorial in *The Lancet*, Wheeler has written, ‘total thyroidectomy for benign thyroid disease is likely to become an accepted component of the endocrine surgeon’s armamentarium’.⁴⁰

The only change on the horizon is the introduction of minimally invasive (or minimal access, or video-assisted, or endoscopic) thyroidectomy. Miccoli *et al.* recently reported a prospective randomized controlled trial of 35 patients with papillary thyroid cancer comparing open total thyroidectomy with total excision using the technique of minimally invasive video-assisted thyroidectomy.⁴¹ A recent symposium in the *Asian Journal of Surgery*, devoted to minimally invasive endocrine surgery, reported a variety of techniques for minimally invasive thyroidectomy. However, in an accompanying editorial, Duh cautioned about their widespread introduction noting that ‘only a fraction of patients undergoing thyroidectomy are candidates for minimally invasive thyroid surgery’.⁴² Our unit has recently reported a series of minimal access thyroid procedures including hemithyroidectomy and local excision of thyroid nodules performed at the same time as minimally invasive parathyroidectomy.⁴³ While such approaches are technically feasible, not all the techniques reported to date would fulfil the criteria of safety and efficacy that have been outlined in this paper. In this coming era of minimally invasive surgery, it is vital that the fundamental principles of exposure and dissection that have evolved over decades are not put to the side for the sake of technology, expediency or the market place.

REFERENCES

1. Welbourn RB. The Thyroid. In: Welbourn RB (ed.) *The History of Endocrine Surgery*. New York: Praeger, 1990; 19–88.
2. Grant C. Presidential address: boiling water to iodine: a story of unparalleled collaboration. *Surgery* 2002; **132**: 909–15.
3. Vellar ID. Thomas Peel Dunhill: pioneer thyroid surgeon. *Aust. NZ J. Surg.* 1999; **69**: 375–87.
4. Sherington G, Vanderfield R. *The Royal North Shore Hospital 1888–1988. A Century of Caring*. Sydney: Horwitz Grahame, 1988.
5. Reeve TS. Thyroidectomy in the treatment of thyrotoxicosis. *J. Coll. Radiol. Aust.* 1964; **8**: 98.
6. Reeve TS, Hales IB, Thomas ID, Poole AG, Messner L. Thyroidectomy – a clinical evaluation of the results of 331 operations. *Med. J. Aust.* 1966; **1**: 202.
7. Reeve TS, Delbridge L, Brady P, Crummer P, Smythe C. Secondary thyroidectomy: a 20 year experience. *World J. Surg.* 1988; **12**: 449–53.
8. Dominello A, Guinea A, Reeve TS, Robinson B, Delbridge L. Progressive increase in thyroid dysfunction after subtotal thyroidectomy for Graves disease. *Asian J. Surg.* 2000; **23**: 131–5.
9. Delbridge L, Reeve TS, Khadra M, Poole AG. Total thyroidectomy – the technique of capsular dissection. *Aust. NZ J. Surg.* 1992; **62**: 96–9.
10. Bliss D, Gauger P, Delbridge L. The surgeons approach to the thyroid gland – anatomy and surgical technique. *World J. Surg.* 2000; **24**: 891–7.
11. Reeve TS, Coupland GAE, Johnson DC, Buddee FW. The recurrent and external laryngeal nerves in thyroidectomy. *Med. J. Aust.* 1969; **1**: 380–2.
12. Hunt PS, Poole M, Reeve TS. A reappraisal of the surgical anatomy of the thyroid and parathyroid glands. *Br. J. Surg.* 1968; **63**: 63–8.
13. Raffaelli M, Iacobone M, Henry JF. The ‘false’ nonrecurrent inferior laryngeal nerve. *Surgery* 2000; **128**: 1082–7.
14. Delbridge L. The ‘neglected’ nerve in thyroid surgery: the case for routine identification of the external nerve [Editorial]. *ANZ J. Surg.* 2001; **71**: 199.
15. Aina EN, Hisham A. The external laryngeal nerve in thyroid surgery: recognition and implications. *ANZ J. Surg.* 2001; **71**: 212–14.
16. Abdullah H, Bliss R, Reeve T, Delbridge L. Recognition of the avascular space medial to the upper pole of the thyroid and its surgical implications. *Asian J. Surg.* 2000; **23**: 86–9.
17. Cernea CR, Ferraz AR, Nishio S *et al.* Surgical anatomy of the external branch of the superior laryngeal nerve. *Head Neck* 1992; **14**: 380–3.
18. Clifton-Bligh R, Delbridge L. Thyroid Physiology. In: Clark OH, Duh WH, Siperstein C (eds). *Textbook of Endocrine Surgery* 2nd edn. Philadelphia: W. B. Saunders, 2003; pp. 3–7.
19. Sackett WR, Reeve TS, Barraclough BH, Delbridge L. Thyrotoxic thyroid rests: incidence and relationship to the thyroid gland. *J. Am. Coll. Surg.* 2002; **195**: 635–40.
20. Gauger PG, Delbridge L, Thompson N, Crummer P, Reeve TS. Incidence and importance of the tubercle of Zuckerkandl in thyroid surgery. *Eur. J. Surg.* 2001; **167**: 249–54.
21. Hsu B, Reeve TS, Guinea A, Robinson B, Delbridge L. Retrosternal recurrence following previous thyroid surgery. *Surgery* 1996; **120**: 1072–5.
22. Reeve TS, Delbridge L. Endocrine tumours of the mediastinum. In: Wood DE, Thomas CR (eds), *Medical Radiology. Diagnostic Imaging and Radiation Oncology – Mediastinal Tumours*. Bangalore: Macmillan, 1995; 55–62.
23. Pelizzo MR, Toniato A, Gemo G. Zuckerkandl’s tuberculum: an arrow pointing to the recurrent laryngeal nerve (constant anatomical landmark). *J. Am. Coll. Surg.* 1998; **187**: 333–6.
24. Khadra M, Delbridge L, Reeve TS, Poole AG, Crummer P. Total thyroidectomy – its role in the management of thyroid disease. *Aust. NZ J. Surg.* 1992; **66**: 91–5.
25. Younes N, Robinson B, Delbridge L. The aetiology, investigation and management of surgical disorders of the thyroid gland. *Aust. NZ J. Surg.* 1996; **66**: 481–90.
26. Wells SA Jr, Gunnells JC, Shelburne JD *et al.* Transplantation of the parathyroid glands in man: clinical indications and results. *Surgery* 1975; **78**: 34–44.
27. Gauger PG, Reeve TS, Wilkinson M, Delbridge LW. Routine parathyroid autotransplantation during total thyroidectomy: the influence of technique. *Eur. J. Surg.* 2000; **166**: 605–9.
28. Lo CY. Parathyroid transplantation during thyroidectomy. *ANZ J. Surg.* 2002; **72**: 902–7.
29. Zedenius J, Wadstrom C, Delbridge L. Routine autotransplantation of at least one parathyroid gland during total thyroidectomy may reduce permanent hypoparathyroidism to zero. *Aust. NZ J. Surg.* 1999; **69**: 794–7.
30. Reeve TS, Delbridge L, Cohen A, Crummer P. Total thyroidectomy: the preferred option for multinodular goitre. *Ann. Surg.* 1987; **206**: 782–5.
31. Barakate M, Agarwal G, Reeve TS, Barraclough BH, Robinson BG, Delbridge L. Total thyroidectomy is now the preferred option for the surgical management of Graves’ disease. *ANZ J. Surg.* 2002; **72**: 321–4.
32. Reeve TS, Delbridge L, Crummer P. Total thyroidectomy in the management of differentiated thyroid cancer. *Aust. NZ J. Surg.* 1986; **56**: 829–33.
33. Reeve TS, Delbridge L., Hobsley M (ed.) *Current Surgical Practice*. London: Edward Arnold and Sons, 1989; 85–99.
34. Wadstrom C, Zedenius J, Guinea A, Reeve TS, Delbridge L. Multinodular goitre presenting as a clinical single nodule – how effective is hemithyroidectomy? *Aust. NZ J. Surg.* 1999; **69**: 34–6.
35. Clark OH. Papillary thyroid carcinoma: rationale for total thyroidectomy. In: Clark OH, Duh QY (eds). *Textbook of Endocrine Surgery*. Philadelphia: W. B. Saunders, 2000; 90–4.

36. Delbridge L, Parkyn R, Philips J, Barraclough B, Robinson BG. Minimally invasive follicular thyroid carcinoma – completion thyroidectomy or not? *ANZ J. Surg.* 2002; **72**: 844–5.
37. Reeve TS, Delbridge L, Curtin A *et al.* Can total thyroidectomy be performed as safely by general surgeons in provincial centres as by surgeons in specialised endocrine surgical units. *Arch. Surg.* 1994; **129**: 834–6.
38. Martin L, Delbridge L, Martin J, Crummer P, Poole AG, Reeve TS. Trainee surgery: is there a cost? *Aust. NZ J. Surg.* 1989; **59**: 257–60.
39. Delbridge L, Guinea AI, Reeve TS. Total thyroidectomy for bilateral benign multinodular goiter: effect of changing practice. *Arch. Surg.* 1999; **134**: 1389–93.
40. Wheeler MH. Total thyroidectomy for benign thyroid disease [Editorial commentary]. *Lancet* 1998; **351**: 1526–7.
41. Miccoli P, Elisei R, Materazzi G, Capezzone M, Galleri D, Pacini F, Berti P, Pinchera A. Minimally invasive video-assisted thyroidectomy for papillary carcinoma: a prospective study of its completeness. *Surgery* 2002; **132**: 1070–4.
42. Duh QY. Recent advances in minimally invasive endocrine surgery. *Asian J. Surg.* 2003; **26**: 62–3
43. Sackett WR, Barraclough BH, Sidhu S, Reeve TS, Delbridge LW. Minimal access thyroid surgery (MATS) – is it feasible, is it appropriate? *ANZ J. Surg.* 2002; **72**: 777–80.