

Otolaryngology -- Head and Neck Surgery

<http://oto.sagepub.com/>

Balloon catheter sinusotomy: One-year follow-up—Outcomes and role in functional endoscopic sinus surgery

Frederick A. Kuhn, Christopher A. Church, Andrew N. Goldberg, Howard L. Levine, Michael J. Sillers, Winston C. Vaughan and Raymond L. Weiss

Otolaryngology -- Head and Neck Surgery 2008 139: S27

DOI: 10.1016/j.otohns.2008.05.010

The online version of this article can be found at:
http://oto.sagepub.com/content/139/3_suppl_1/S27

Published by:



<http://www.sagepublications.com>



On behalf of:
AMERICAN ACADEMY OF
OTOLARYNGOLOGY-
HEAD AND NECK SURGERY

FOUNDATION

[American Academy of Otolaryngology- Head and Neck Surgery](http://www.aao-hns.org)

Additional services and information for *Otolaryngology -- Head and Neck Surgery* can be found at:

Email Alerts: <http://oto.sagepub.com/cgi/alerts>

Subscriptions: <http://oto.sagepub.com/subscriptions>

Reprints: <http://www.sagepub.com/journalsReprints.nav>

Permissions: <http://www.sagepub.com/journalsPermissions.nav>

>> [Version of Record](#) - Sep 1, 2008

[What is This?](#)

ORIGINAL RESEARCH

Balloon catheter sinusotomy: One-year follow-up—Outcomes and role in functional endoscopic sinus surgery

Frederick A. Kuhn, MD, Christopher A. Church, MD, Andrew N. Goldberg, MD, MSCE, Howard L. Levine, MD, Michael J. Sillers, MD, Winston C. Vaughan, MD, and Raymond L. Weiss, MD, Savannah, GA; Loma Linda, CA; San Francisco, CA; Cleveland, OH; Birmingham, AL; Palo Alto, CA; and Biloxi, MS

OBJECTIVE: The primary objective was to assess the long-term effectiveness of balloon catheter sinusotomy.

METHODS: Patients who had sinus ostia dilated with balloon catheters were prospectively evaluated 1 year after surgery with nasal endoscopy, a CT scan, and the Sino-Nasal Outcome Test (SNOT-20).

RESULTS: Sixty-six patients (202 sinuses) were examined. One hundred seventy-two of 202 sinus ostia (85%) were endoscopically patent, 1 percent (2/202) were nonpatent, and ostial patency could not be determined by endoscopy in 28 of 202 (14%). In these “indeterminate” sinuses, the CT scans were normal in 13, implying functional patency in 91.6 percent of sinuses (185/202). Sinus CT scan scores were 1.95 at 1 year versus 8.89 at baseline ($P < 0.001$), and 1-year SNOT-20 scores (0.91) were significantly improved from baseline (2.14, $P < 0.0001$).

CONCLUSION: Balloon catheter sinusotomy results were durable over the study period, showing long-term effectiveness.

© 2008 American Academy of Otolaryngology–Head and Neck Surgery Foundation. All rights reserved.

The preservation of normal structures, restoration of sinus ventilation, and physiologic mucous drainage are central, time-tested principles used in treating patients with sinusitis as reported by Nauman,¹ Messerlinger,² Stamberger,³ and Kennedy et al⁴ over the last 40 years. During this time, many instruments have been used to open obstructed sinus ostia including curettes, grasping forceps, probes, seekers, tissue-sparing forceps, and microdebriders. Recently, a new device was introduced to accomplish this objective, a sinus balloon catheter.⁵ The balloon device is specially designed to microfracture and mold bone surrounding the sinus ostia by inflating to a specific diameter under high pressures. Recently, safety and outcomes of balloon catheter sinusotomy were reported with 6-month

follow-up data on durability of the ostial dilation.⁶ Because it is important to monitor outcomes and safety after introducing new technology, this study was performed to provide additional data from 1-year follow-up of these original patients.

The purpose of this study was to evaluate the durability of ostial patency and the patients' symptomatic improvement, comparing the 1-year symptom data with the patients' baseline preoperative and 24-week data. A secondary study objective was to gain insight into differences in postoperative debridement (Current Procedural Terminology (CPT) code 31237) and antibiotic usage in patients treated with balloon catheter devices as compared with those historically achieved with endoscopic sinus surgery. An additional objective was to compare frontal sinus outcomes achieved with balloon catheter sinusotomy to outcomes achieved by endoscopic sinus surgery.

METHODS

This study was designed as a prospective multicenter 1 year postsurgery analysis of balloon catheter sinus ostial dilation in patients with sinusitis. It extends analysis of the previously reported Safety and Outcomes of Balloon Catheter Sinusotomy study⁶ beyond the initial 24-week data-collection period to provide analysis 1 year after treatment. As in the original study, some patients had only the balloon catheter used to treat the sinuses (balloon-only patients), and in other patients balloons were used in some sinuses, whereas other sinuses were operated on using standard endoscopic instruments (hybrid patients).

Patient selection, study inclusion criteria, description of the balloon catheter sinusotomy, and original study design

Received January 18, 2008; revised April 23, 2008; accepted May 6, 2008.

have been previously described and reported.⁶ At completion of the original 24-week study, patient follow-up was extended to 1 year at seven of nine participating institutions, with institutional review board (IRB) approval. Regulations regarding human subject research and safeguarding of confidential patient data were followed. Two investigators could not participate in the longer follow-up analysis. One investigator moved and no longer had access to his patients. The other investigator could not reapply to his IRB in time for the 1-year follow-up study.

There were 86 possible candidates for the study at seven study sites. Sixteen patients were lost to follow-up. Each of the 70 successfully contacted patients signed an IRB-approved informed consent for the 1-year follow-up study. The patients were asked to have a nasal endoscopy and a CT scan and to complete a Sino-Nasal Outcome Test (SNOT-20). The investigator recorded the endoscopic status of each balloon-treated sinus ostium as either patent, nonpatent, or indeterminate. The term “indeterminate” was used if the ostium could not be visualized with rigid endoscopy at the postoperative office visits or if the patient did not tolerate a complete endoscopic examination.

Fifty-six of 70 patients had CT scans at 1 year. Three of these scans were not included because each patient had one sinus revised, leaving 53 scans to evaluate. Twenty-three were balloon-only patients, and 30 were hybrid patients who had some of their sinuses treated with balloon catheters and the remainder treated with traditional endoscopic techniques.

CT scans were analyzed by the investigators using the Lund/Mackay⁷ (L/M) scoring system. The presurgery and postsurgery CT scans were analyzed by sinus as well as by patient in order to eliminate any bias when comparing patients with fewer diseased sinuses (balloon-only patients) to those with more sinuses involved (ie, hybrid patients with ethmoid sinus disease who required endoscopic ethmoidectomy). Particular attention was given to the frontal sinus in

order to compare the outcome with published reports of standard endoscopic sinus surgery.

A statistician analyzed the SNOT-20 scores by using a paired *t* test and the L/M CT scan scores by using the Wilcoxon signed rank test. Baseline to 1-year L/M CT scores and baseline, 24-week, and 1-year SNOT-20 scores were compared. All patients' charts were retrospectively surveyed for the number of postoperative endoscopic sinonasal debridements, adverse events, and use of postoperative antibiotics.

Role of the Funding Source

The sponsor (Acclarent Inc, Menlo Park, CA) funded the investigation, provided administrative support in coordinating the investigation across the various study sites, maintained the central database, and funded independent statistical and data analysis performed by statistical consultants Lois Kellerman, MS, and Bruce Stouch, PhD. The sponsor did not design the study, write the paper, or make the decision to publish it.

RESULTS

Nasal Endoscopy

Of the 70 patients (217 sinuses) in the study cohort, 66 (202 sinuses) had nasal endoscopy. Nasal endoscopy was not performed in four patients because they could not return in time for the study. Nasal endoscopy showed that 85 percent of sinuses were patent (172/202), 1 percent (2/202) of visualized sinuses were nonpatent, and patency could not be determined by endoscopy in 14 percent (28/202). Consequently these sinuses were classified as indeterminate (Table 1).

Endoscopic analysis by individual sinus revealed that 74 frontal sinuses were endoscopically evaluated at 1 year.

Table 1
1-year postoperative patency by sinus

	Maxillary	Frontal	Sphenoid	Total
Postoperative endoscopic patency	90% patent (83/92)	85% patent (63/74)	72% patent (26/36)	85% patent (172/202)
All 1-year patients	0% nonpatent (0/92)	3% nonpatent (2/74)	0 nonpatent (0/36)	1% nonpatent (2/202)
Hybrid and balloon only	10% (9/92) indeterminate	12% (9/74) indeterminate	28% (10/36) indeterminate	14% (28/202)
Functional patency CT L/M = 0 all 1-year patients	3/9 stage 0	5/9 stage 0	5/10 stage 0	13/28 stage 0 (46%)
Overall patency	93.5% (86/92) (83 + 3/92)	91.9% (68/74) (63 + 5/74)	86.1% (31/36) (26 + 5/36)	91.6% (185/202)

Table 2
L/M mean patient CT scores

CT score	Balloon only patients (n = 23)	Hybrid patients (n = 30)
Preoperative	5.96	11.33
Postoperative	1.13	2.66
Change	-4.83	-8.67
P value	<0.001	<0.001

Sixty-three were patent, two were nonpatent, and nine were indeterminate. Eighty-three of 92 maxillary sinuses (90%) were endoscopically patent, zero were nonpatent, and nine of 92 were indeterminate. Twenty-six of 36 sphenoid sinuses were endoscopically patent, zero were nonpatent, and 10 were indeterminate.

CT Scan Results

Fifty-six patients had 1-year postoperative CT scans. Of the 14 patients who did not have a CT scan, four did not return for outpatient follow-up, eight had endoscopically patent sinus ostia, and the surgeon felt a scan was not indicated (n = 7) or the patient had already had a scan done before the 1-year follow-up visit (n = 1 at 9 months). The last two patients who did not have a 1-year CT scan had one indeterminate sinus each on endoscopy but were asymptomatic and not clinically indicated for a CT scan.

CT scores are reported for each group by the average L/M patient score (Table 2) and by the average L/M sinus score (Table 3) to remove any bias caused by more sinuses being involved in the hybrid patients (ie, those with ethmoid sinus disease). The hybrid patients' average preoperative CT scores were higher than in the balloon-only patients because the ethmoid sinuses were involved in the hybrid patients but not in the balloon-only patients. In addition, all ballooned frontal, maxillary, and sphenoid sinuses are reported (Table 4), which shows that CT scan evidence of improvement is similar regardless of which sinus is treated.

The mean balloon-only preoperative patient L/M CT score of 5.96 decreased (-4.83) to a mean postoperative score of 1.13 at 1 year ($P < 0.001$). The mean hybrid

Table 4
L/M score: all balloon-treated sinuses

	Frontal (n = 64)	Maxillary (n = 76)	Sphenoid (n = 32)	P value
Preoperative	1.03	1.05	0.97	<0.001
Postoperative				
1 year	0.22	0.34	0.19	<0.001
Change	-0.81	-0.71	-0.78	<0.001

preoperative patient L/M CT score of 11.33 decreased (-8.67) to a mean postoperative patient score of 2.66 at 1 year ($P < 0.001$).

The balloon-only patients' mean preoperative sinus CT score of 1.09 decreased (-0.92) to a postoperative score of 0.17 per sinus ($P < 0.001$). The hybrid patients' mean preoperative sinus CT score of 1.01 decreased (-0.68) to 0.33 per sinus ($P < 0.001$). This includes the standard endoscopic surgery-treated sinuses. All groups showed significant improvement.

One-year postoperative CT scans were obtained on 26 of 28 indeterminate sinuses, which showed that 13 of 26 were completely normal aerated sinuses. Three of the 13 normally aerated indeterminate sinuses were maxillary sinuses, five were frontal, and five were sphenoid sinuses (Table 5). Ten sinuses had partial opacity or mucous membrane thickening, and three were totally opacified; however, two of the opaque sinuses were in one patient who was acutely infected at the time of the CT scan.

Symptom Assessment

The 1-year follow-up SNOT-20 scores were significantly better than preoperative scores and showed additional improvement over the patients' 6-month scores (Table 6). All 70 patients who participated completed the SNOT-20 form. Only 65 of 70 are reported because three patients had their ballooned sinuses revised and two patients did not have complete datasets (ie, did not have all questionnaires completed at baseline, 24 weeks, and 1 year). The overall mean preoperative score for 65 patients was 2.14 compared with 1.01 at the 24-week follow-up and 0.91 at the 1-year follow-up. The 1-year decrease from baseline (-1.23) represents a clinically meaningful (>0.8) decrease⁷ and a statistically significant change ($P < 0.0001$). As can be seen, there is a

Table 3
L/M mean sinus CT scores

CT score	Balloon patient by sinus (n = 64)	Hybrid patients by sinus (n = 125)
Preoperative	1.09	1.01
Postoperative	0.17	0.33
Change	-0.92	-0.68
P value	<0.001	<0.001

Table 5
L/M CT scores for all indeterminate sinuses (N = 28)

Sinus	L/M 0	L/M 1	L/M 2	No scan
Frontal	5	3	1	0
Maxillary	3	2	2	2
Sphenoid	5	5	0	0
Totals	13	10	3 = 26	2 = 28

Table 6
Mean SNOT-20 scores by week (all evaluated patients, N = 65)

Week	All patients treated				Balloon dilation patients only				Hybrid patients only			
	N	Mean	Δ from Baseline	P value	N	Mean	Δ from baseline	P value	N	Mean	Δ from Baseline	P value
Preoperative baseline	65	2.14	—	—	31	2.01	—	—	34	2.26	—	—
Postoperative week 24	65	1.01	−1.13	.0001	31	0.97	−1.04	.0001	34	1.22	−1.04	.0001
Postoperative week 52	65	0.91	−1.23	.0001	31	0.95	−1.06	.0001	34	0.87	−1.39	.0001

continued downward trend in their symptom score from baseline to 24 weeks to 1 year.

Similar SNOT-20 results were obtained for the balloon dilatation–only subset of 31 patients. Their preoperative score was 2.01, the 24-week score was 0.97, and the 1-year score was 0.95, a clinically meaningful and statistically significant change from baseline to 1 year (-1.06 , $P < 0.0001$).

When specific symptom changes are examined for the 65 hybrid and balloon patients whose SNOT-20s were evaluated (Table 7), several even more dramatic changes are noted than is represented in the overall score (ie, postnasal drainage, facial pain/pressure, reduced productivity, lack of a good night's sleep, fatigue, and frustration). Each of these individual symptom decreases and the overall symptom score decrease are clinically meaningful and significant ($P < 0.0001$).⁸

Antibiotic and Debridement Data

Antibiotic and debridement data were obtained on 70 of 70 patients. Thirty-nine of seventy patients (56%) had no postoperative antibiotics. The other 31 patients received antibiotics as deemed appropriate by their treating physician, ranging from 5 days to 2 weeks. One investigator treated all of his patients with antibiotics (N = 28, 21 hybrid and 7

balloon only), another treated two of 11 patients (both balloon only) for specific infections, and the third treated one of one (hybrid, no infection). The other 4 investigators did not use any antibiotics in their 30 patients.

Thirty-five balloon-only patients had 15 debridements (0.43/patient), and the 35 hybrid patients had 63 debridements (1.8/patient). Three patients had only balloon frontal sinusotomy and one had endoscopic frontal sinusotomy only; none had postoperative debridement.

Revision Surgery

Revision treatment was required in a total of three of 342 (0.7%) sinuses in the first 24 weeks and one additional sinus in the second 6 months (1/203, 0.5%). If only the revised sinuses are added to the 202 available to evaluate at 1 year, the revision rate is four of 206 (2%) over the 1-year period. No adverse events were reported between 24 weeks and 1 year.

DISCUSSION

Chronic sinusitis is primarily a symptom-based disease. Its evaluation requires the combined use of clinical impression,

Table 7
Individual symptom scores (all evaluated patients N = 65)

Symptom	n	Preoperative mean	Postoperative mean	Change from baseline	P value
Postnasal drainage 5	64	3.03	1.66	−1.38	<0.0001
Thick nasal drainage 6	63	2.22	1.16	−1.06	<0.0001
Facial pain/pressure 10	65	3.02	1.26	−1.75	<0.0001
Cough 4	64	1.88	0.89	−0.98	<0.0001
Reduced productivity 16	64	2.41	0.88	−1.53	<0.0001
Lack of good night's sleep 13	65	2.43	0.94	−1.49	<0.0001
Fatigue 15	65	2.65	1.11	−1.54	<0.0001
Frustration 18	65	2.45	0.86	−1.58	<0.0001
Depression/sad 19	65	1.29	0.45	−0.85	<0.0001

symptom assessment, radiographic sinus evaluation, and nasal endoscopy with rigid diagnostic telescopes.

An important aspect of sinus surgery is the restoration of physiologic sinus function (ie, mucous clearance, which requires a patent, functioning sinus ostium). Therefore, ostial patency is an important criterion by which we judge the success of any sinus surgical method, technique, or instrument. Additional criteria by which we judge success are (1) the clarity of the sinus on CT scan (ie, is sinus aeration improved postoperatively) and (2) whether the patient's symptoms are relieved. Unfortunately, we know that symptoms do not correlate as well as we would like with objective evidence of sinus health, as noted by Senior et al,⁹ who found no correlation between symptoms and CT stage at either 1.5 years or 7.8 years after endoscopic sinus surgery. Interestingly, they report that long-term symptom improvement at an average 7.8 years is correlated to results at 18 months, indicating that intermediate-term results are durable over the long-term.

Balloon catheter sinusotomy affords increased tissue preservation over standard endoscopic techniques but presents a challenge in the postoperative endoscopic follow-up examination. Patency cannot always be determined by using current sinus endoscopes in an awake patient whose uncinate process, turbinates, and ethmoid bulla have been preserved because of the narrow confines of the preserved sinus structures. This, of course, is not a problem in properly performed FESS, in which these structures have been removed, thereby allowing more room for rigid endoscopy. Consequently, a new paradigm is needed to evaluate the postoperative outcome of these more minimally invasive procedures. Therefore, the posttreatment CT scan was used to gain insight into the health of sinuses that we could not visualize with endoscopy.

In this present study, ostial patency could not be determined by endoscopy in 28 sinuses. Ten of 28 indeterminate ostia were sphenoid sinus ostia, nine of 28 were maxillary sinus ostia where visibility was blocked by an intact uncinate process, and nine of 28 were frontal sinus ostia inaccessible because of intact uncinate processes and ethmoid bullae. We reasoned that a completely aerated sinus on a CT scan suggests a patent functional ostium. Therefore, "indeterminate" sinus ostia with an L/M score of 0 on a postoperative CT scan were considered to be patent because their sinuses were functioning. These sinuses are termed "functionally patent." A CT scan obtained on 26 of 28 indeterminate sinuses showed completely normal aeration in 13 of 26 sinuses (L/M score 0), inferring "functional" ostial patency. If the normal CT scan in these 13 sinuses is considered evidence of ostial patency, the overall patency rate from balloon dilatation 1 year after treatment can be calculated at 91.6 percent (172 endoscopically confirmed, 13 by CT analysis = 185/202) (Table 1).

In addition to the 13 indeterminate sinuses that were normal on a postoperative CT scan, 10 indeterminate balloon-treated sinuses had mucosal thickening or partial

opacification on CT scan (L/M score of 1). To provide a conservative analysis, we only considered a completely normal CT scan as evidence of ostial patency. Therefore, it is possible that more patients than we have indicated may have realized benefit after treatment with the balloon catheter devices. A 91.6 percent patency rate for all ballooned sinus ostia at the 1-year follow-up compares very well with the patency reported for endoscopic sinus surgery using standard tissue removing instruments at 18 months¹⁰ and at 12 months.¹¹ This suggests that balloon catheters now have a place in sinusitis management.

Seventy-four frontal sinuses evaluated at 1 year showed that 85.1 percent (63/74) were visually patent, two were nonpatent, and nine were indeterminate. Five of nine indeterminate frontal sinuses were aerated and had no mucous membrane thickening. If the five indeterminate L/M score 0 frontal sinuses (Table 1) are added to the 63 visually patent sinuses, endoscopic patency + functional patency is 91.9 percent (68/74) after one procedure (Table 1) and 92.1% (70/76) when the two revised frontal sinuses (2.6%) are included.

The patency rate of standard endoscopic frontal sinus surgery is reported as 82.3 percent in 107 of 130 frontal sinuses after one endoscopic procedure and 90 percent (117/130) after revising 10 (7.7%) of the frontal sinusotomies.¹⁰ The average follow-up was 8.3 months for successes and 10.7 months for failures.

Friedman et al¹¹ reported 90 percent patency in 298 frontal sinuses at an average 12.2 month follow-up. Interestingly, they report no difference in postoperative stenosis between 68 patients with polypoid disease (10.3%) and 132 without polypoid disease (10.6%). Another interesting finding was that 95 frontal sinuses without preoperative CT evidence of disease had a stenosis rate of 3.2 percent. Two hundred three sinuses with CT evidence of disease had a stenosis rate of 10.3 percent, and 14 percent of the 99 sides with previous ethmoidectomy developed frontal ostium stenosis.

This current study's comparable frontal sinus patency rate (92.1%) was accomplished with fewer revisions (2.6% vs 7.7%) and fewer postoperative antibiotics and debridements than reported by endoscopic sinus surgeons, who use an average of four to six weekly debridements per patient and 2 to 3 weeks of postoperative antibiotics per patient.¹⁰

Symptom Improvement

This analysis suggests that symptom improvement of balloon-treated patients compares very favorably with medical treatment-only patients. The 65 patients whose completed SNOT-20 questionnaires were evaluated had mean scores of 2.14 before surgery, 1.01 at the 24-week follow-up, and 0.91 1 year after surgery. The 1-year change from baseline (-1.23) is a clinically meaningful decrease (>-0.8) and a statistically significant change ($P < 0.0001$) (Table 6).

The balloon dilatation-only subset (31/65 patients) average preoperative SNOT-20 score was 2.01, the 24 week score was 0.97, and the 1-year score was 0.95. The change

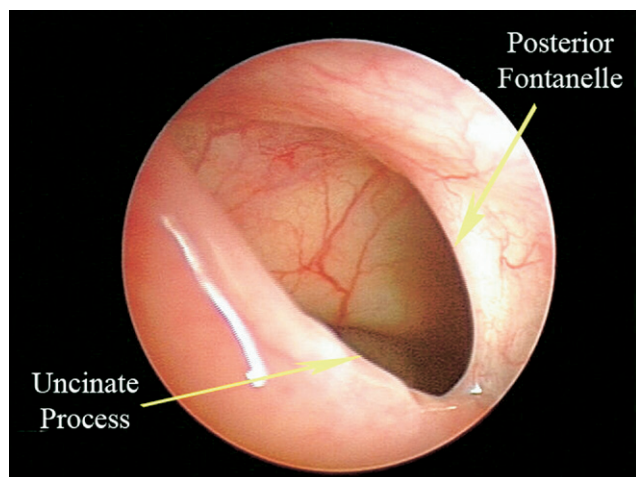


Figure 1 The right maxillary ostium 12 months postoperatively. Anterior to Posterior (AP) diameter >10 mm. Cutting instruments were not used to create this ostium. The 7-mm balloon used to dilate the ostium split the membranous posterior fontanel, resulting in an antrostomy larger than the balloon diameter.

from baseline (-1.06 , $P < 0.0001$) was also clinically meaningful and statistically significant (Table 6).

Hessler et al¹² reported on symptom improvement of 84 chronic rhinosinusitis patients treated with medical therapy, who all had at least two major chronic sinusitis criteria. The mean posttreatment SNOT-20+1 score decrease was -0.61 ($P < 0.0001$). They report that although the change was statistically significant, it was not clinically meaningful (ie, < -0.8). In other words, the medical treatment made no meaningful change in symptoms.

It is apparent that better symptom results were obtained with balloon catheter ostial dilatation than in Hessler et al's¹² medical treatment group (-1.23 and -1.06 vs -0.61). It should be noted that the comparison is not perfect because some of this series' patients received postoperative antibiotics. The groups had similar degrees of sinusitis on pretreatment CT scan. The pretreatment L/M CT scores were 5.96 for balloon-only patients, 8.3 for Hessler et al's patients, and 11.3 for the hybrid patients. It is difficult to make a direct comparison with Senior's study⁹ because different criteria were used to evaluate the symptom outcomes; however, their conclusion regarding the long-term durability of symptom improvement is encouraging.

In this current study, we found stable, slightly improved results comparing 6- to 12-month data. It is encouraging that Senior et al⁹ found that their results at 18 months were maintained at 7.8 years and concluded that initial symptom improvement can be maintained in the long-term.

Postoperative Antibiotics and Debridements

Postoperative antibiotic and debridement data were obtained in this study on 70 of 70 patients. Thirty-nine of 70 study patients had no postoperative antibiotics, and the other 31 had durations of treatment varying from 5 days to 2 weeks based on the surgeon's judgment. Because one

investigator used antibiotics on all of his patients and others used them only when patients became infected, one might conclude that antibiotic usage could be even less if the same approach were used by all.

Debridements (CPT code 31237-50) overall averaged 1.1 per patient, including 0.43 per patient in the balloon-only group and 1.8 per patient in the hybrid group. This is consistent with previously reported data of 1.2 debridements per patient (0.8 for balloon-only patients and 1.4 for hybrid patients) in a registry of 1,036 balloon sinusotomy patients.¹³ This represents a significant reduction relative to previously reported Functional Endoscopic Sinus Surgery (FESS) debridements; some report an average of two to three debridements per patient,^{14,15} whereas others recommend weekly debridement until the nasal cavity is healed, which may translate to six to eight debridements per patient.⁸ The cost savings in debridements when using the balloon as an instrument can be substantial. Further cost analyses, such as that provided by Friedman¹⁶ will help us understand the costs in more detail.

Applications

Patients in this study with moderate chronic frontal, maxillary, and sphenoid sinusitis including fungus ball responded well to balloon catheter management, as shown by this cohort's average single-ballooned sinus preoperative CT score of 1.02, which was reduced to 0.27 with a 1-year functional patency rate of 91.6 percent. This was accomplished with the removal of less tissue, fewer ethmoidectomies, fewer postoperative antibiotics, and fewer postoperative debridements. Observed frontal sinus endoscopic patency (85%) and functional patency (91.9%) of balloon-dilated frontal sinus drainage pathways compare well with reported frontal sinus patency after endoscopic surgery with ethmoidectomy (82.3%¹⁰ and 90%¹¹). The issue is not so

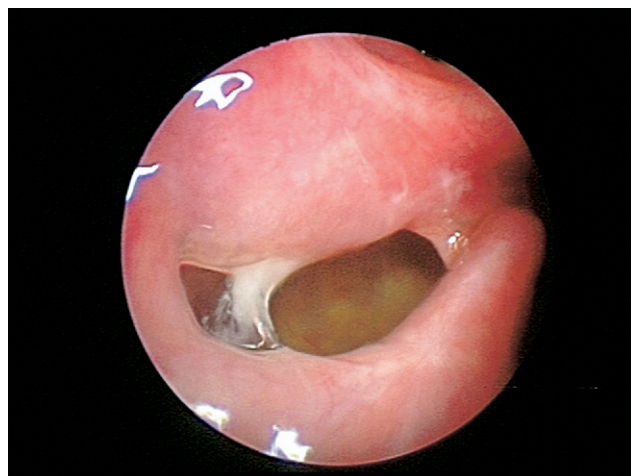


Figure 2 The right maxillary ostium, different patient, upper uncinate removed to facilitate ethmoidectomy. The maxillary ostium has been dilated with a balloon. The posterior fontanel is intact. The lower part of uncinate was left in place to protect the posterior infundibulum and drainage pathway for maxillary sinus.

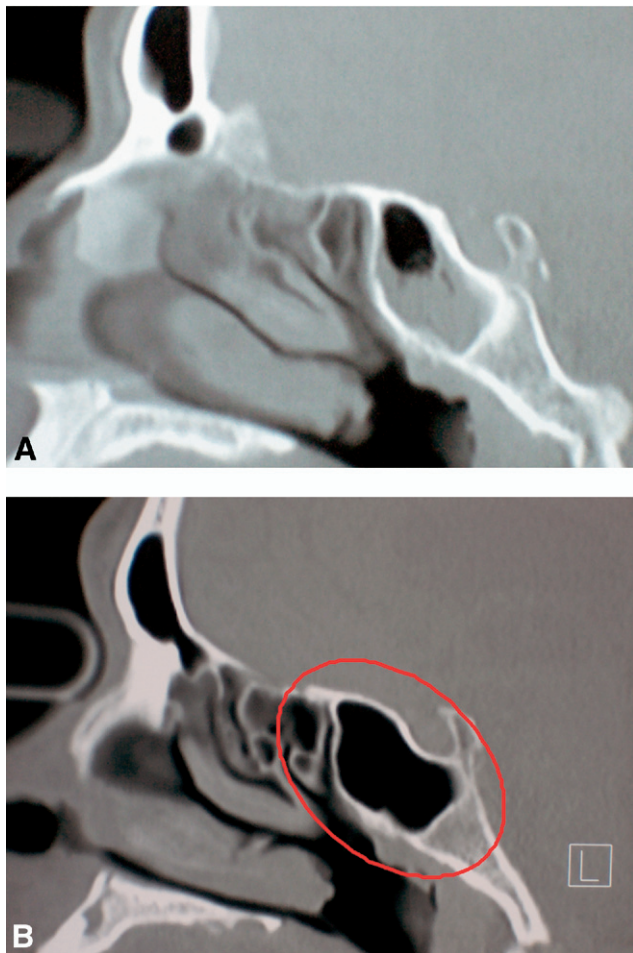


Figure 3 (A) The chronic right sphenoid sinusitis in an anticoagulated, symptomatic stroke patient. After prolonged medical treatment, the right sphenoid ostium was dilated and the sinus irrigated. The patient's coumadin was not discontinued, and the patient was discharged 3 hours after a 20-minute surgery. Pathology: fungal debris. (B) The right sphenoid sinus, the same patient as Fig 3A, at 1 year after balloon dilatation with sphenoid sinus irrigation. The sinus is clear, and the patient is asymptomatic.

much why balloon catheters are better than standard instrumentation rather what they can do that standard instruments cannot. Furthermore, what techniques and applications will they allow that standard instruments will not?

This minimally invasive technology affords techniques not previously possible, such as maxillary sinus surgery without uncinata process removal, sphenoid sinus surgery without ethmoidectomy or partial superior turbinate resection to gain access to the sphenoid ostium,¹⁷ and isolated frontal sinus surgery without ethmoidectomy and frontal recess dissection. The following are examples of these techniques.

Figure 1 is the 1-year follow-up photograph of a patient presented in the original 24-week Safety and Outcomes of Balloon Catheter Sinusotomy study, which shows the durability of the antrostomy. The patient had an isolated right maxillary sinusitis resistant to 6 weeks of culture-directed antibiotic therapy for *Staphylococcus aureus*. Contrary to skeptics of the original image, no cutting instruments were

used to create the antrostomy. A 7-mm balloon was used to perform a right maxillary sinusotomy without uncinata removal, which resulted in a >10-mm ostium that has remained patent at 1 year. The opening is larger than the balloon expansion because the membranous posterior fontanel split during the procedure as the balloon expanded further than the natural maxillary ostium diameter.

Figure 2 represents a patient (different from that in Figure 1) who has had a balloon dilatation of the right maxillary ostium but has had the upper uncinata process removed to facilitate an ethmoidectomy. The posterior fontanel is intact, unlike the example in Figure 1. The

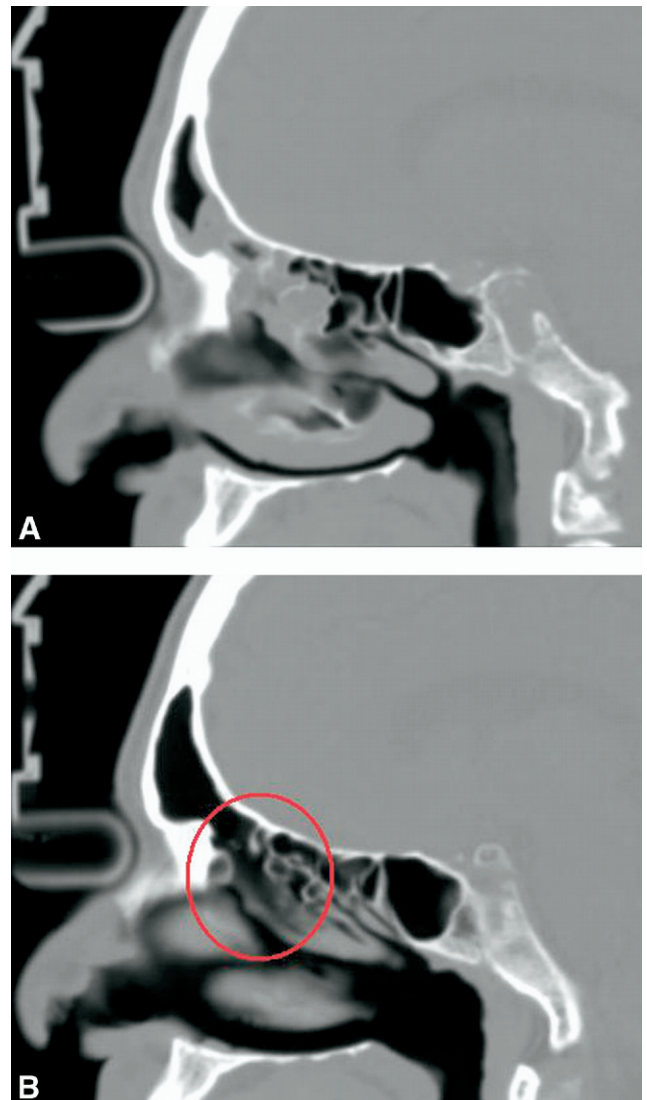


Figure 4 (A) Chronic right frontal and anterior ethmoid disease in a 74-year old treated with three courses of antibiotics. The patient's septum was deviated to the right, decreasing the airway to <4 mm width. The patient was treated with a right balloon frontal sinusotomy and irrigation; no septoplasty, ethmoidectomy, or maxillary antrostomy were performed; and no antibiotics were given. (B) One-year postoperative CT sagittal reconstruction of the patient in 4A. Right frontal sinus is clear. Right ethmoid sinus has cleared with no other treatment.

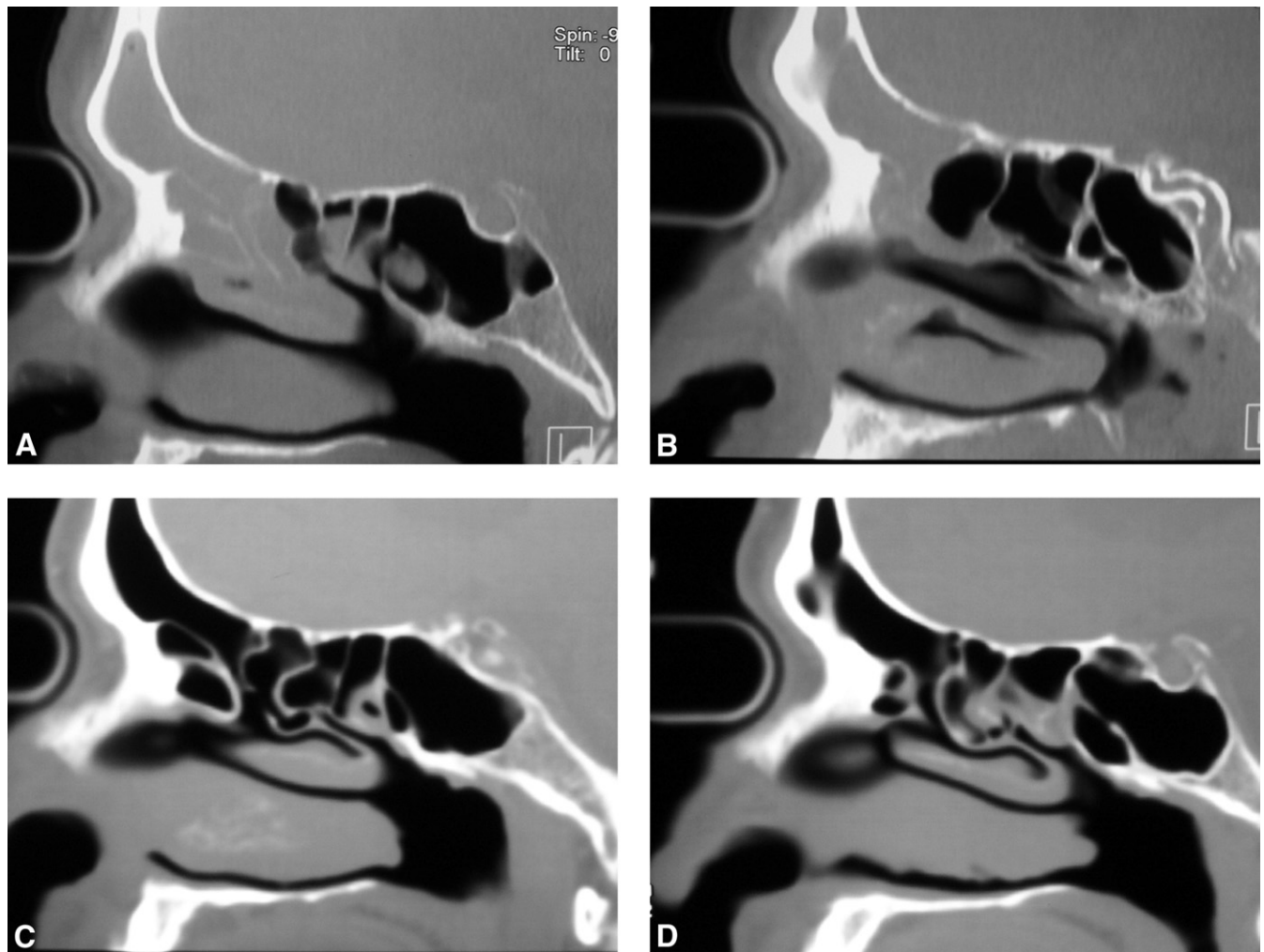


Figure 5 (A) Preoperative sagittal CT reconstruction, right side. (B) Preoperative sagittal CT reconstruction, left side. (C) Postoperative 1-year sagittal CT reconstruction, right side, comparable to 5A. (D) Postoperative 1-year sagittal CT reconstruction, left side comparable to 5B.

lower uncinate remnant has not been removed in order to keep the posterior infundibulum intact, which facilitates early postoperative maxillary sinus mucous clearance. This is another alternative method of maxillary sinus surgical management to restore physiologic function.

The patient in [Figure 3A and B](#) is a hemiplegic anticoagulated stroke patient who developed a partially opaque, symptomatic right sphenoid sinus. He was very agitated over constant coughing and throat clearing, possibly related to the visible drainage from his sphenoid sinus. He was medically treated for 12 weeks but did not clear. His right sphenoid sinus ostium was dilated and the sinus contents irrigated out, without stopping his anticoagulation. The procedure required 20 minutes, there was no bleeding, and he was discharged 2 hours after surgery. Fungus was found on pathology.

The patient in [Figure 4](#) had been treated for acute sinusitis on three occasions with 10- to 14-day courses of antibiotics. The CT scan obtained on referral showed an opaque right frontal sinus and anterior ethmoid sinus disease as well as a severely deviated nasal septum to the right. It was

elected to treat him with balloon frontal sinusotomy rather than a septoplasty and right-sided endoscopic ethmoidectomy, maxillary antrostomy, and frontal sinusotomy. His frontal sinus was treated with a 5-mm balloon and frontal sinus irrigation, which yielded 5.5 mL of thick white mucous. The 1-year postoperative sagittal reconstruction reveals the clear frontal sinus, the tract out of it, and the clear ethmoid sinuses. The ethmoid sinus, the maxillary sinus, and the extreme right nasal septum deviation were not operated, and he was not treated with antibiotics. The remarkable thing about this patient is that his ethmoid sinus cleared without any treatment other than resolving the frontal sinusitis.

The patient in [Figure 5](#) presented with a history of three episodes of acute frontal pain treated with antibiotics over a 4-month period. A CT scan performed at consultation revealed bilateral chronic/subacute frontal sinusitis. It was decided to enroll him in the original CLEAR study, and both frontal sinuses were treated with balloon catheter dilation and irrigation. He was not treated with postoperative anti-

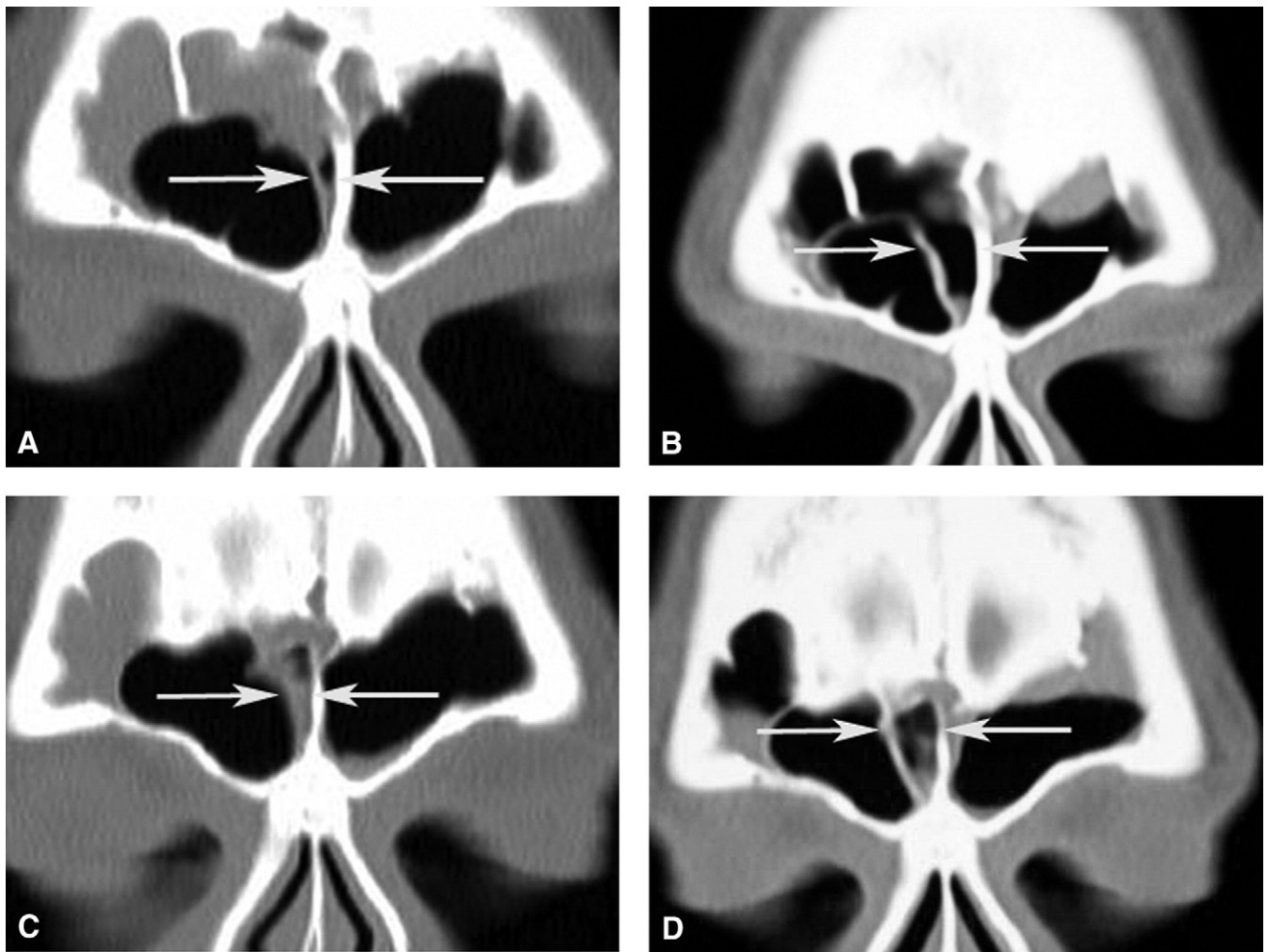


Figure 6 (A) The right frontal sinus with massive type IV frontal cell obstructing frontal sinus; see arrows (preoperative CT). (B) Six-month postoperative CT scan comparable to 5A. The type IV frontal cell medial wall has been moved laterally away from the interfrontal sinus septum. (C) Right frontal sinus drainage pathway; see arrows (preoperative CT scan). (D) Six-month postoperative CT scan comparable to 5C. Images B and D, 2.5 mm apart, show that the medial frontal cell wall has been moved laterally over several millimeters (anterior to posterior), which has opened the frontal sinus drainage pathway.

biotics. He required no debridements. His 1-year postoperative CT scan revealed that both anterior ethmoid sinuses as well as his frontals had cleared.

Given the previously described two patients, one must begin to question why the anterior ethmoid sinuses cleared without standard treatment. What is it about the inflammatory disease process that we do not understand that has allowed the ethmoid sinuses to clear without performing an ethmoidectomy?

The patient in Figure 6 in whom a hybrid procedure was performed had the right frontal sinus outflow tract obstructed by a very large-type IV frontal cell. The medial wall of this cell can be seen lying against the interfrontal sinus septum in preoperative Figures 6A and C, which are separated by 2.5 mm. The matched postoperative Figures 6B and D show how the medial-type IV frontal cell wall has been moved and remodeled by the balloon into a more lateral position away from the interfrontal sinus septum. As a result, the frontal drainage pathway has been opened.

The patient in Figure 7 has had a hybrid procedure. The images show that although the appearance of the frontal ostium at surgery is not maintained at 3 weeks, frontal sinus patency is maintained and agger nasi cell patency is restored. The agger nasi cell was actually crushed closed at surgery and now has reestablished itself at 3 weeks but does not compromise frontal sinus patency as was found at surgery. The last figure confirms the durability of both frontal sinus and agger nasi cell patency as well as the stability of the remodeled medial agger nasi cell wall 9 months after surgery.

In addition to the preceding examples, the balloon catheter is very useful in the morbidly ill intensive care patient who has acute sinusitis as a complication or cause of their primary problem. These patients need minimally invasive surgery with quick resolution of their sinus disease. This is exemplified by a moribund intensive care unit patient who was found to have bilateral acute sphenoid sinusitis as the etiology of meningitis. The patient's sphenoid sinuses were dilated with a balloon catheter and

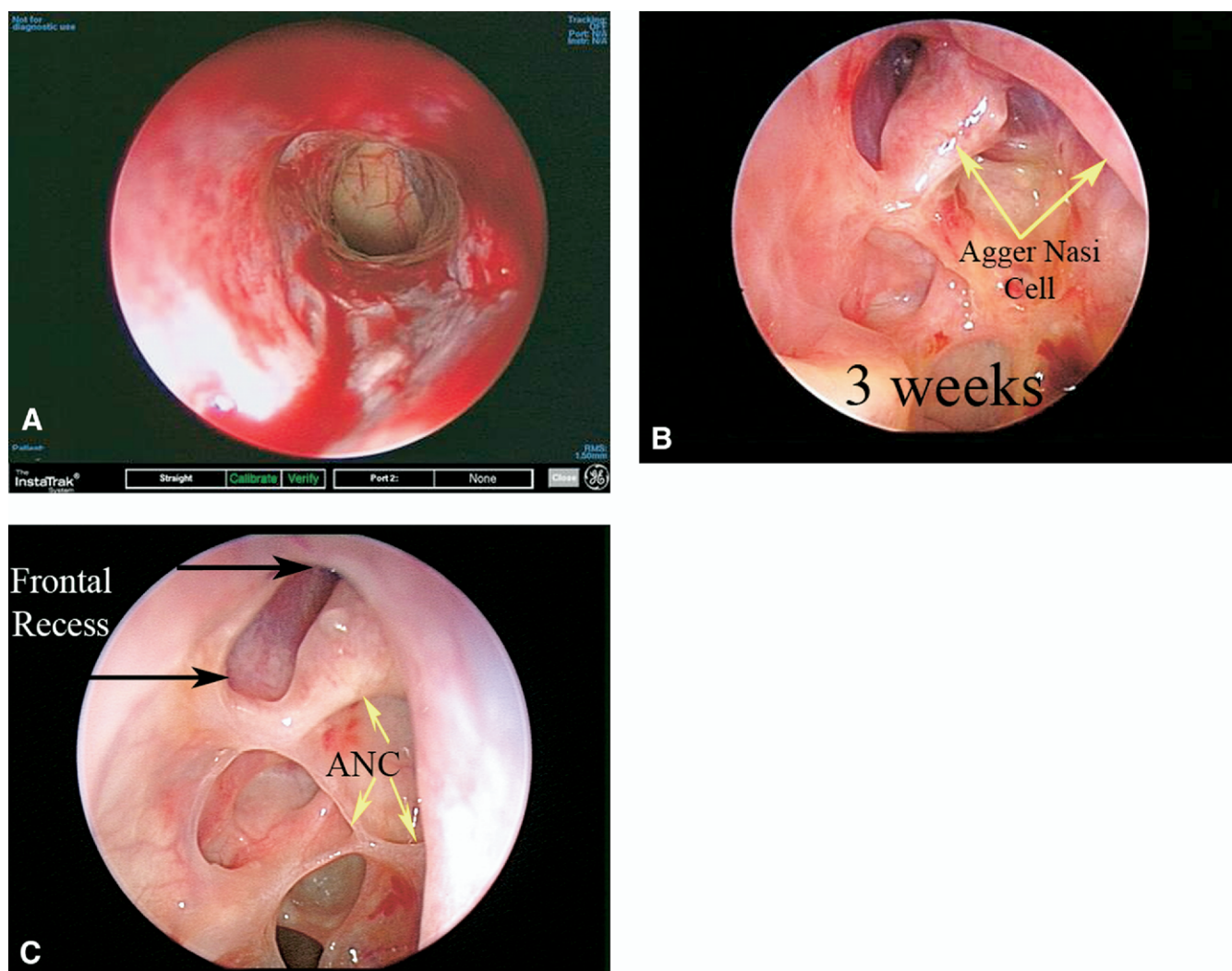


Figure 7 (A) The left frontal ostium opened by a 7-mm balloon (70° telescope). The medial agger nasi cell wall, which had been lying on the middle turbinate was pushed laterally against medial orbital wall. The frontal sinus roof is visible through the ostium. (B) Left frontal ostium (30° view) 3 weeks after surgery. The medial agger nasi cell wall has moved to a neutral, more medial position, leaving both the frontal drainage pathway and the agger nasi cell open. (C) Left frontal recess (30° view), 9 months after surgery, showing stability of the remodeled medial agger nasi cell wall and durability of the frontal sinus drainage pathway. The frontal ostium, medial to the agger nasi cell, is open and functional. Extensive frontal recess dissection with its attendant risk of mucosal damage and stenosis was avoided.

irrigated under general anesthesia in a 25-minute procedure. She was conscious in 48 hours and discharged in 1 week.

CONCLUSION

This study shows that sinus ostial patency and symptom improvement 1 year after balloon catheter sinusotomy are durable. Therefore, the 1-year 91.6% overall sinus ostial patency, the 92.1% frontal ostium patency, and the clinical and statistically significant symptom improvement for balloon catheter sinusotomy compare favorably with standard endoscopic sinus surgical results¹¹ for the management of moderate chronic sinusitis. This indicates that balloon catheters now have a place in sinusitis management.

ACKNOWLEDGEMENTS

The authors would like to acknowledge William E. Bolger, MD, Christopher T. Melroy, MD, and Yvonne Chan, MD for their help in reviewing the manuscript and offering editorial suggestions. We would also like to acknowledge the office staff of the study sites for their patience and help in collecting the data.

AUTHOR INFORMATION

From the Georgia Nasal and Sinus Institute, Savannah, GA (Dr Kuhn); Loma Linda University, Loma Linda, CA (Dr Church); University of California-San Francisco, San Francisco, CA (Dr Goldberg); Cleveland Nasal, Sinus and Sleep Center, Cleveland, OH (Dr Levine); Alabama Nasal and Sinus Center, Birmingham, AL (Dr Sillers); California Sinus Institute, Palo Alto, CA (Dr Vaughan); and Sinus Center of the South, Biloxi, MS (Dr Weiss).

Corresponding author: Frederick A. Kuhn, MD, Georgia Nasal and Sinus Institute, 4750 Waters Avenue, Suite 112, Savannah, GA 31404.

E-mail address: docsinus@aol.com.

AUTHOR CONTRIBUTIONS

Frederick A. Kuhn, investigator, author; **Christopher A. Church**, investigator; **Andrew N. Goldberg**, investigator; **Howard L. Levine**, investigator; **Michael J. Sillers**, investigator; **Winston C. Vaughan**, investigator; **Raymond L. Weiss**, investigator.

FINANCIAL DISCLOSURES

Frederick A. Kuhn, GE & Acclarent: scientific advisor, stock ownership; Gyrus & Karl Storz; **Christopher A. Church**, royalties; **Howard L. Levine**, Acclarent: scientific advisor, consultant, stock holder; Medtronic Xomed: consultant; **Michael J. Sillers**, GE Navigation, Gyrus, Naryx: Consultant; Acclarent: consultant, scientific advisor; **Winston C. Vaughan**, former Acclarent scientific advisor; Allux, Naryx, GE Medical Inc: Scientific Advisory Board; Bayer, MedPointe, Pricara: Speaker's Bureau; **Raymond L. Weiss**, Acclarent scientific advisor.

REFERENCES

1. Naumann H. Pathologische anatomie der chronischen rhinitis und sinusitis. (Pathologic anatomy of chronic rhinitis and sinusitis) In: Proceedings VIII International Congress of Oto-rhino-laryngology. Amsterdam: Excerpta Medica; 1965:79–87.
2. Messerklinger W. Endoscopy of the Nose. Baltimore, MD: Urban & Schwarzenberg; 1978.
3. Stammberger H. Endoscopic endonasal surgery—concepts in treatment of recurring rhinosinusitis. Part I. Anatomic and pathophysiologic considerations. *Otolaryngol Head Neck Surg* 1986;94:143–7.
4. Kennedy DW, Zinreich SJ, Rosenbaum AE, et al. Functional endoscopic sinus surgery. Theory and diagnostic evaluation. *Arch Otolaryngol* 1985;111:576–82.
5. Brown C, Bolger WE. Safety and feasibility of balloon catheter dilation of paranasal sinus ostia: a preliminary investigation. *Ann Otol Rhinol Laryngol* 2006;115:293–9.
6. Bolger WE, Brown CL, Church CA, et al. Safety and outcomes of balloon catheter sinusotomy: a multicenter 24-week analysis in 115 patients. *Otolaryngol Head Neck Surg* 2007;137:10–20.
7. Lund VJ, Mackay IS. Staging in rhinosinusitis. *Rhinology* 1993;31:183–4.
8. Piccirillo JF, Merritt MG, Michele RI. Psychometrics and clinimetric validity of the 20-item sino-nasal outcome test (SNOT-20). *Otolaryngol Head Neck Surg* 2002;126:41–7.
9. Senior BA, Kennedy DW, Tanabodee J, et al. Long-term results of functional endoscopic sinus surgery. *Laryngoscope* 1998;108:151–7.
10. Chandra RK, Palmer JN, Tansujarittham T, et al. Factors associated with failure of frontal sinusotomy in the early follow-up period. *Otolaryngol Head Neck Surg* 2004;131:514–8.
11. Friedman M, Landsberg R, Schults RA, et al. Frontal sinus surgery: endoscopic technique and preliminary results. *Am J Rhinol* 2000;14:393–403.
12. Hessler JL, Piccirillo JF, Fang D, et al. Clinical outcomes of chronic rhinosinusitis in response to medical therapy: results of a prospective study. *Am J Rhinol* 2007;21:10–8.
13. Levine HL, Sertich AP, Hoisington D, et al. Multicenter registry of balloon catheter sinusotomy outcomes for 1,036 patients. *Ann Otol Rhinol Laryngol* 2008;117(4):263–70.
14. Thaler ER. Postoperative care after endoscopic sinus surgery. *Arch Otolaryngol Head Neck Surg* 2002;128:1204–6.
15. Stankiewicz JA. Comments about postoperative care after endoscopic sinus surgery. *Arch Otolaryngol Head Neck Surg* 2002;128:1207–8.
16. Friedman M, Schalch P, Lin H, et al. Functional endoscopic dilatation of the sinuses: patient satisfaction, postoperative pain, and cost. *Am J Rhinol* 2008;22:204–9.
17. Orlandi RR, Lanza DC, Bolger WE. The forgotten turbinate: the role of the superior turbinate in endoscopic sinus surgery. *Am J Rhinol* 1999;13:251–9.