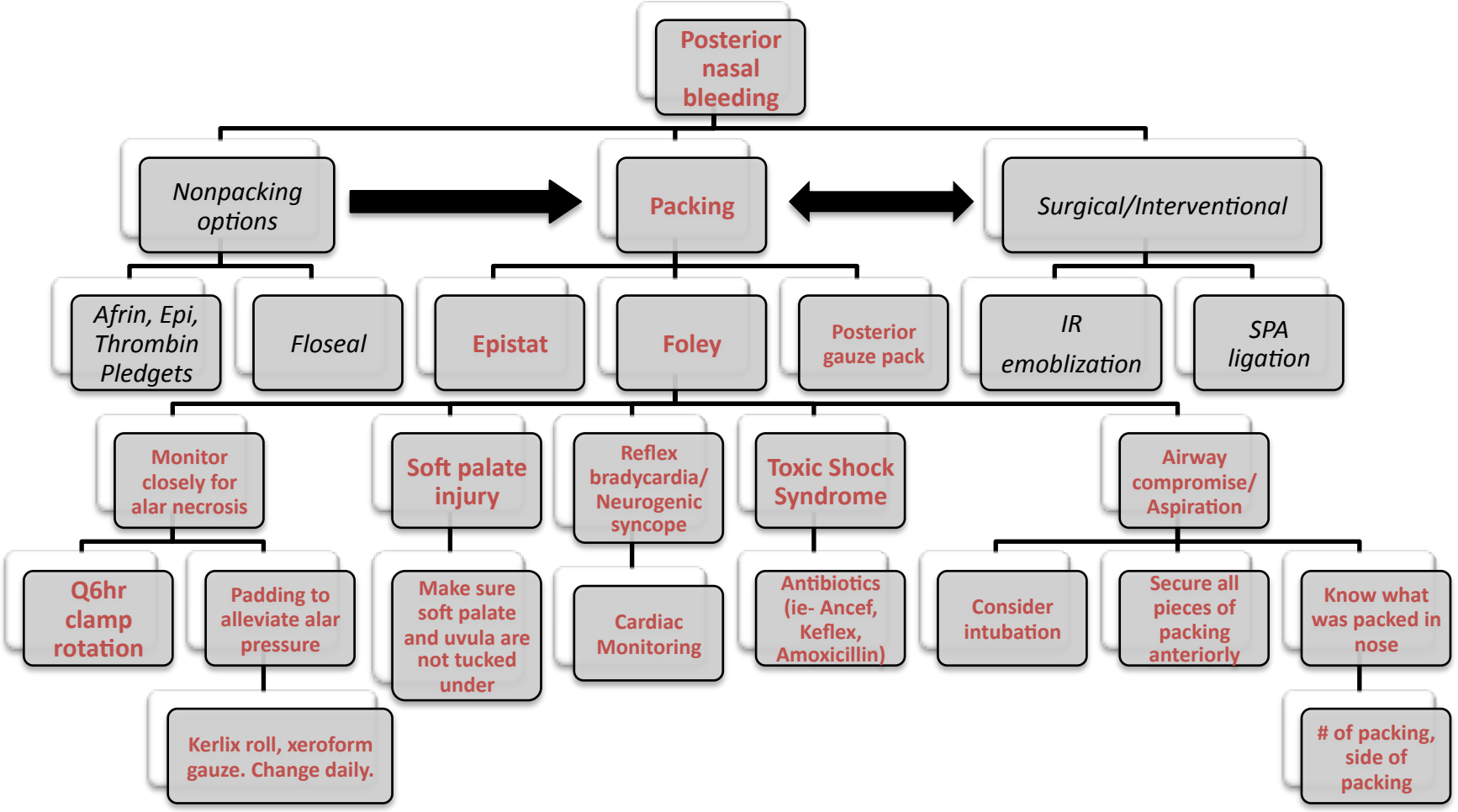Approach to posterior epistaxis