

CLINICAL PRACTICE

Epistaxis

Rodney J. Schlosser, M.D.

This Journal feature begins with a case vignette highlighting a common clinical problem. Evidence supporting various strategies is then presented, followed by a review of formal guidelines, when they exist. The article ends with the author's clinical recommendations.

A 61-year-old man presents to the emergency room with left-sided epistaxis that has continued for 1 hour. He estimates having lost approximately 1/2 cup of blood and reports no history of nasal obstruction, epistaxis, trauma, bleeding diathesis, or easy bruising. He has a history of hypertension. Medications include atenolol and baby aspirin. How should this patient be evaluated and treated?

THE CLINICAL PROBLEM

From the Department of Otolaryngology—
Head and Neck Surgery, Medical University
of South Carolina, Charleston.

N Engl J Med 2009;360:784-9.

Copyright © 2009 Massachusetts Medical Society.

Epistaxis is estimated to occur in 60% of persons worldwide during their lifetime, and approximately 6% of those with nosebleeds seek medical treatment.¹ The prevalence is increased for children less than 10 years of age and then rises again after the age of 35 years.²

ANATOMICAL FEATURES

More than 90% of episodes of epistaxis occur along the anterior nasal septum^{1,3} at a site called Kiesselbach's area. Its vascular supply moves from the external carotid artery through the superior labial branch of the facial artery and the terminal branches of the sphenopalatine artery and from the internal carotid artery through the anterior and posterior ethmoidal arteries. Approximately 10% of nosebleeds occur posteriorly, along the nasal septum or lateral nasal wall. Blood is supplied to this area from the external carotid artery through the sphenopalatine branch of the internal maxillary artery (Fig. 1).⁴ Posterior nosebleeds are more common in older patients; in one retrospective report, the mean age of patients with posterior nosebleeds was 64 years.⁵

CAUSES AND ASSOCIATED CONDITIONS

Both local and systemic conditions contribute to epistaxis. Self-induced digital trauma (nose picking) is common, particularly among children. Mucosal trauma from topical nasal drugs, such as corticosteroids or antihistamines, may result in minor epistaxis in 17 to 23% of patients using these products.⁵ The incidence of epistaxis appears to be lower if patients direct the spray laterally to minimize the effect of these medications on the septum. Illicit nasal drug use may also cause epistaxis. Profound epistaxis may result from trauma to the nasal bones or septum. Dehumidification of the nasal mucosa probably underlies the increased incidence of nosebleeds noted during the winter months.² Other factors associated with epistaxis include septal perforations, which often lead to dry mucosa, viral or bacterial rhinosinusitis, and neoplasms.

Systemic conditions associated with coagulopathies should also be considered in patients presenting with epistaxis. In one retrospective study,⁶ 45% of patients hospitalized for epistaxis had systemic disorders with the potential to contribute to nosebleeds, including genetic disorders such as hemophilia and acquired coagulopathies



An audio version
of this article
is available at
NEJM.org

due to liver or renal disease, use of anticoagulant medication, or hematologic cancers. Low-dose aspirin appears to increase the risk of epistaxis slightly; in a randomized trial of low-dose aspirin administered for cardiovascular prophylaxis in women, reported rates of epistaxis in the aspirin and placebo groups were 19.1% and 16.7%, respectively, over a 10-year period.⁷ Alternative therapies, such as ingestion of garlic, ginkgo, or ginseng, may also contribute to mild systemic coagulopathies that result in epistaxis.⁸

Hypertension may contribute to epistaxis, but this theory is controversial. A cross-sectional, population-based study showed no association between hypertension and epistaxis.⁹ In a prospective study of patients with hypertension who had epistaxis, the incidence of epistaxis was not related to the severity of hypertension. In this population, blood pressure measured at the time of epistaxis was similar to routinely measured blood pressure.¹⁰ In contrast, other studies have reported elevated blood pressure in patients with epistaxis.¹¹⁻¹³ When the onset of epistaxis is abrupt, it is difficult to determine whether hypertension is the cause, since many patients with active bleeding have anxiety that leads to elevated blood pressure. Hereditary hemorrhagic telangiectasia is another genetic disorder that often results in nosebleeds. The clinical appearance shown in Figure 2 is characteristic.

STRATEGIES AND EVIDENCE

The evaluation of any patient with epistaxis must begin by ensuring a secure airway and hemodynamic stability. In spite of the frightening appearance, most nosebleeds are not life-threatening. A thorough history should be taken, with attention to laterality, duration, frequency, and severity of epistaxis; to any contributing or inciting factors, as outlined above; and to a family history of bleeding disorders.

Physical examination should focus on localizing the source of bleeding to the anterior or posterior nasal cavity. Topical sprays of anesthetics and vasoconstrictors, such as combinations of lidocaine or ponticaine with phenylephrine or oxymetazoline, may be needed to control the bleeding enough to allow adequate physical examination. These sprays can be applied separately or mixed and administered simultaneously. In addition to topical sprays, careful, atraumatic, topical application of anesthetics and vasoconstrictors on cotton pledgets can be useful. Clinical experience indicates that this approach often slows or stops the bleeding and can be used to gently remove any clot, making the patient more com-

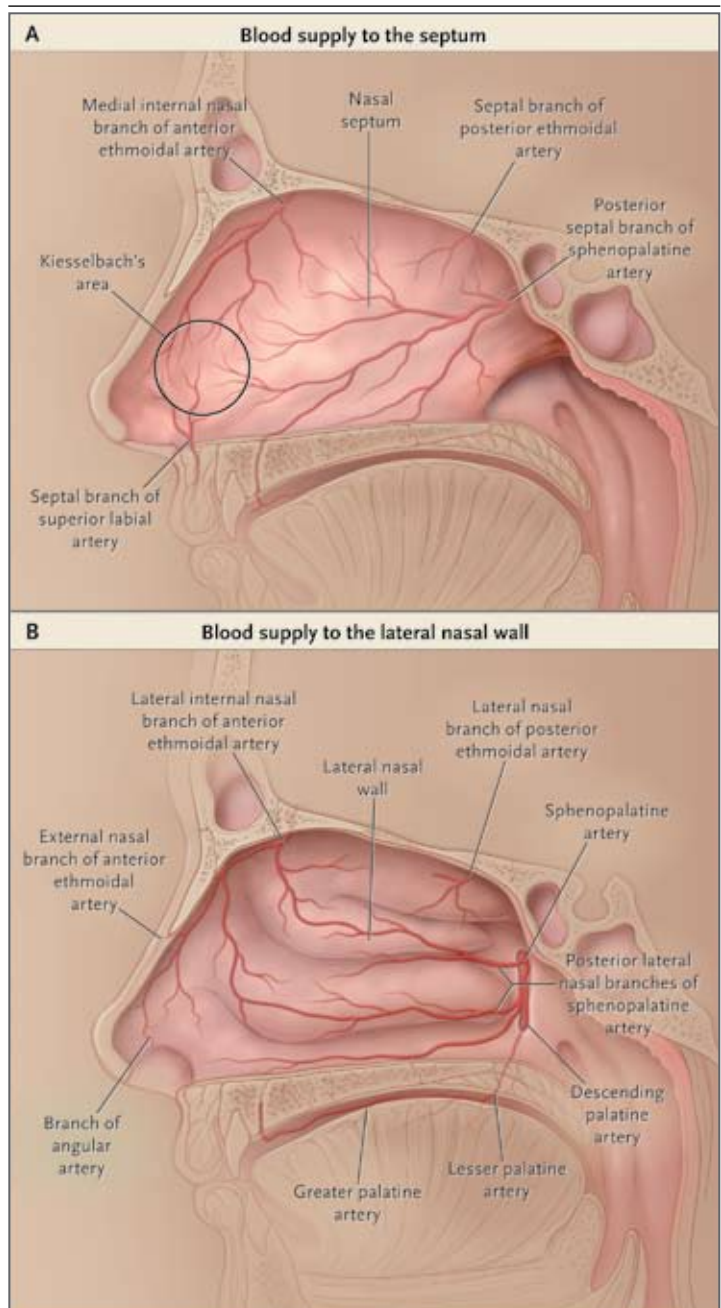


Figure 1. Blood Supply to the Nasal Septum and Lateral Nasal Wall.

Most nosebleeds occur along the anterior nasal septum at a site called Kiesselbach's area, which receives blood from the terminal branches of the sphenopalatine, ethmoidal, and superior labial arteries (Panel A). Posterior nosebleeds occur along the nasal septum or lateral nasal wall (Panel B) and are supplied by the sphenopalatine artery, which enters the nasal cavity through the lateral nasal wall.

tors on cotton pledgets can be useful. Clinical experience indicates that this approach often slows or stops the bleeding and can be used to gently remove any clot, making the patient more com-

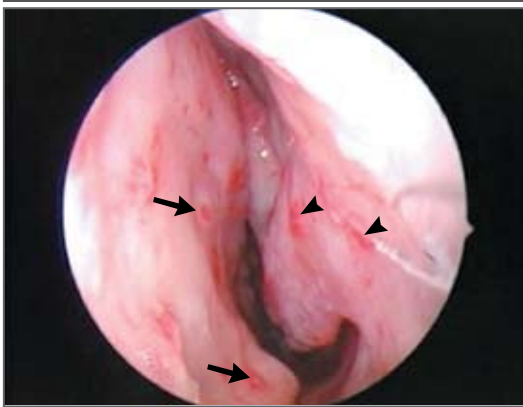

Figure 2. Endoscopic Image Showing Nasal Telangiectasias.

The classic features of hereditary hemorrhagic telangiectasias can be seen along the left anterior septum (arrows) and the left inferior turbinate (arrowheads).

fortable for the duration of a thorough examination. In patients with clinically significant posterior bleeding, a transpalatal injection of the sphenopalatine artery can be useful. It is most easily performed by bending a 25-gauge needle at 2.5 cm and inserting the needle through the descending palatine foramen just medial to the upper second molar. After aspiration to ensure that the needle tip has not entered a vessel, 1.5 to 2.0 ml of 1% lidocaine with epinephrine at a 1:100,000 dilution should be injected slowly. Once the bleeding has slowed, the clot in the nasal cavity will need to be suctioned free so that the origin of the bleeding can be evaluated.

For patients with severe hemorrhage, a complete blood count should be performed, as well as blood typing and screening for possible transfusion. Most patients present with mild-to-moderate epistaxis that does not require transfusion, and coagulation studies are generally not required. Laboratory studies may be warranted in selected patients — for example, in patients taking warfarin, tests may be required to determine whether anticoagulation levels are supratherapeutic, and in patients with systemic conditions that could lead to coagulopathy, testing for hepatic or renal dysfunction may be required. Even when testing is performed selectively, the results are normal in nearly 80% of patients.⁶

Recurrent unilateral epistaxis that does not respond to the simple conservative measures outlined directly below should raise suspicion for

neoplasm. Nearly all patients with benign or malignant sinonasal neoplasms present with unilateral (or at least asymmetric) symptoms, which may include nasal obstruction, rhinorrhea, facial pain, or evidence of cranial neuropathies, such as facial numbness or double vision. Any recurrent unilateral epistaxis warrants consideration of radiographic studies, such as computed tomography or magnetic resonance imaging, and endoscopic evaluation to rule out a serious condition.

TREATMENT OPTIONS

Most anterior nosebleeds are self-limited and do not require medical treatment. They can be controlled by pinching the anterior aspect of the nose for 15 minutes, which provides tamponade for the anterior septal vessels. The patient should relax, if possible. The head position can be either forward or backward, whichever is more comfortable, but it is important for the patient to avoid swallowing or aspirating any blood that may be draining posteriorly into the pharynx. A common mistake is for the patient to attempt to compress the area along the nasal bones. Pressure should be applied more distally by compressing the nasal ala against the septum. In addition to pressure, topical oxymetazoline spray may be useful. In one study, oxymetazoline spray stopped the bleeding in 65% of consecutive patients with epistaxis who were being seen in an emergency room.¹⁴

Epistaxis that is refractory to pressure and topical vasoconstrictors may require cautery. After preparing the nose with anesthetics and decongestants, as described above, chemical cautery with silver nitrate can be performed. It has an acceptable safety profile, and in a case series, this approach controlled epistaxis in just over half of patients whose bleeding did not respond to topical vasoconstrictors and pressure.¹⁴ Only one side of the septum is cauterized at a time to reduce the risk of iatrogenic septal perforation, although the exact incidence of this complication is not known. Chemical cautery can be used for mild active bleeding or after active bleeding has been stopped and prominent vessels have been identified. When bilateral septal cautery is warranted, the treatments should be separated by 4 to 6 weeks to provide time for mucosal healing. Severe nosebleeds that are unresponsive to chemical cautery may require electric cautery, although this requires specialized equipment.

Anterior nasal packing is used for epistaxis that originates in Kiesselbach's area and is refractory to the above treatments. Traditional packing products consist of nondegradable materials, such as gauze coated with petroleum jelly, a sponge composed of hydroxylated polyvinyl acetate that expands when wet (Merocel, Medtronic), and an inflatable pack with hydrocolloid coating that remains in contact with mucosa after the center of the pack has been deflated and removed (Rapid Rhino, ArthroCare). These packs are left in place for 1 to 3 days before removal. In randomized, controlled trials, their use stopped bleeding in approximately 60 to 80% of cases refractory to vasoconstrictors and pressure.^{15,16} Insertion and removal of these packs can result in mucosal trauma, which may lead to recurrent bleeding or pain. In a randomized trial comparing Merocel and Rapid Rhino, there was no significant difference in the rates at which epistaxis was controlled, but both patients and physicians found Rapid Rhino easier to insert and remove.¹⁵

A variety of absorbable or degradable materials that do not require formal removal are useful for patients with or without coagulopathies. Oxidized cellulose (Surgicel, Johnson & Johnson) and purified bovine collagen foam or paste (Gelfoam, Pfizer) increase clot formation and provide some degree of tamponade. Other absorbable products include microfibrillar collagen (Avitene, Davol), porcine gelatin (Surgiflo, Johnson & Johnson), and bovine gelatin-human thrombin (FloSeal, Baxter). These products are generally available as powders that are mixed with liquid to create a slurry that is similar in consistency to cooked oatmeal or grits and that can then be applied topically with a syringe. The advantage of these products is that they conform to the three-dimensional structure of the nasal cavity and are easy to use. The decision concerning which product to use is based on availability, cost, and the physician's preference. In a randomized, unblinded trial (supported in part by Baxter Biosurgery) comparing FloSeal with nasal packing (with the use of Merocel, petroleum jelly-coated gauze, or Rapid Rhino), FloSeal was found to be significantly more effective at stopping nosebleeds (rebleeding rate at 1 week, 14%, vs. 40% for the other therapies overall).¹⁶ Patients also reported greater satisfaction and less discomfort with FloSeal than with the other forms of packing. The costs are generally higher for FloSeal, but they may be offset by the

cost of the follow-up visit required for removal of packing. Regardless of which absorbable material is used, most physicians recommend a moisturizing saline spray once the bleeding has stopped for 24 to 48 hours, which may facilitate both mucosal healing and degradation of the packing material.

Posterior nasal packing may be required for bleeding attributable to the sphenopalatine artery. Inflatable balloons, such as the Epistat (Medtronic) and the Foley catheter, are widely used for posterior packing. Traditional posterior packs with cotton gauze introduced through the mouth and then retracted up into the nasopharynx can also be used, but they are more difficult to place. To be effective, posterior packing must be retracted anteriorly and must provide tamponade in the area of the choanae and sphenopalatine foramen. Tamponade is typically accomplished by securing the anterior end of the balloon pack or the suture attached to a traditional posterior pack in the vicinity of the nasal ala. This arrangement provides countertraction that keeps the posterior pack in the choanae, but care must be taken to avoid trauma to the ala, which can result in pressure necrosis. In one case series, posterior packs stopped epistaxis in approximately 70% of patients with posterior bleeding.¹⁷

When nasal packs are in place, topical antibiotic ointments that coat the nasal packing or oral antibiotics are often used because of concern about the toxic shock syndrome. The incidence of this syndrome after placement of packing for epistaxis is unknown. A rate of 16.5 cases per 100,000 has been reported among patients undergoing nasal surgery who had nasal packs,¹⁸ but it is unclear whether these cases were due to the packing or to surgery, since the toxic shock syndrome has also been reported after sinonasal surgery without the use of nasal packing.¹⁹ Because the syndrome is rare, there are no data showing that the risk is reduced with the use of antibiotic therapy. Patients with bilateral anterior or posterior nasal packs are typically admitted to the hospital for monitoring of oxygen saturation because of the potential for apneic spells.

When conservative measures fail to stop the bleeding, embolization or surgical ligation of the offending vessels is needed. Interventional radiologists can embolize the distal branches of the internal maxillary artery and sphenopalatine artery for posterior nosebleeds. The risk of a major complication, such as stroke, facial paralysis,

blindness, or nephropathy associated with the administration of contrast material, is approximately 4%. Minor complications, such as hematoma, occur in approximately 10% of cases.²⁰ Success rates in most case series are 80 to 90%.^{20,21}

According to several case-series reports and literature reviews,^{20,21} success rates for surgical ligation of the sphenopalatine artery are equivalent to or better than success rates for embolization. Ligation can be performed in 30 to 60 minutes with the use of modern endoscopic techniques. Endoscopic ligation of the sphenopalatine artery avoids the risks associated with angiography but requires general anesthesia. Overall health care costs are decreased by more than 50% when posterior nosebleeds are treated with posterior packs for immediate control, followed by endoscopic ligation of the sphenopalatine artery. The use of endoscopic ligation, as compared with the use of traditional posterior nasal packing, allowed for earlier discharge from the hospital in one prospective study.²²

Anterior epistaxis that fails to respond to cauterization and packing is rare, but surgical intervention is sometimes necessary. Embolization of the anterior and posterior ethmoid arteries is rarely performed because there is a risk of cannulating the internal carotid artery, which increases the risk of stroke, or the ophthalmic artery, which increases the risk of blindness. Most otorhinolaryngologists perform external ligation of the anterior and posterior ethmoidal arteries through a small incision near the medial eyebrow and perform bipolar cauterization or clipping of the vessels within the orbit just before exiting through the anterior and posterior ethmoidal foramina. The risks of stroke and blindness are greatly reduced when this surgical approach is used.²³

Once epistaxis has been controlled, routine care of the nasal mucosa is generally recommended to prevent recurrence. Topical gels, lotions, and ointments are available to moisturize the mucosa and promote healing of otherwise friable mucosa and superficial vessels. In a single-blind, randomized trial involving children with recurrent epistaxis, use of antiseptic cream reduced recurrence rates, as compared with no treatment.²⁴ However, a Cochrane review of three trials (two randomized) of the management of recurrent epistaxis in children, was inconclusive,

with no definitive differences in outcomes observed for three different strategies: topical antiseptic cream, silver nitrate cauterization, and no treatment.²⁵

AREAS OF UNCERTAINTY

Many aspects of the management of epistaxis have not been evaluated in randomized trials, including the efficacy of self-applied tamponade, vasoconstrictors, and other topical therapies; the optimal type of nasal packing and duration of use; the role of antibiotics in association with nasal packing; and the usefulness of various surgical and embolization techniques.

GUIDELINES

There are no formal professional guidelines concerning epistaxis. However, recommendations for management provided by the American Academy of Otolaryngology — Head and Neck Surgery (www.entnet.org/HealthInformation/Nosebleeds.cfm) are generally consistent with those presented here.

CONCLUSIONS AND RECOMMENDATIONS

For most patients presenting with epistaxis, such as the patient in the vignette, there is a response to conservative treatment consisting of patient-applied pressure to the anterior septum for 15 minutes, topical vasoconstrictors, and topical ointments for moisturizing. Although few randomized trials have been conducted to evaluate and compare various treatment strategies, cases that do not respond to conservative approaches usually do respond to cauterization or packing with a variety of absorbable hemostatic materials. Severe cases may require posterior packing, surgical intervention, or embolization. If epistaxis recurs in the case described, discontinuation of aspirin should be considered. Repeated episodes, particularly if they were unilateral or accompanied by other nasal symptoms, would warrant radiographic and endoscopic evaluation to rule out neoplastic processes.

Dr. Schlosser reports receiving consulting fees and research support from Medtronic. No other potential conflict of interest relevant to this article was reported.

REFERENCES

1. Viehweg TL, Roberson JB, Hudson JW. Epistaxis: diagnosis and treatment. *J Oral Maxillofac Surg* 2006;64:511-8.
2. Walker TWM, Macfarlane TV, McGarry GW. The epidemiology and chronobiology of epistaxis: an investigation of Scottish hospital admissions 1995-2004. *Clin Otolaryngol* 2007;32:361-5.
3. Douglas R, Wormald PJ. Update on epistaxis. *Curr Opin Otolaryngol Head Neck Surg* 2007;15:180-3.
4. Oneal RM, Beil RJ Jr, Schlesinger J. Surgical anatomy of the nose. *Otolaryngol Clin North Am* 1999;32:145-81.
5. Waddell AN, Patel SK, Toma AG, et al. Intranasal steroid sprays in the treatment of rhinitis: is one better than another? *J Laryngol Otol* 2003;117:843-5.
6. Awan MS, Iqbal M, Imam SZ. Epistaxis: when are coagulation studies justified? *Emerg Med J* 2008;25:156-7.
7. Ridker PM, Cook NR, Lee IM, et al. A randomized trial of low-dose aspirin in the primary prevention of cardiovascular disease in women. *N Engl J Med* 2005;352:1293-304.
8. Gifford TO, Orlandi RR. Epistaxis. *Otolaryngol Clin North Am* 2008;41:525-36.
9. Fuchs FD, Moreira LB, Pires CP, et al. Absence of association between hypertension and epistaxis: a population-based study. *Blood Press* 2003;12:145-8.
10. Knopffholz J, Lima-Junior E, Précama-Neto D, Faria-Neto JR. Association between epistaxis and hypertension: a one year follow-up after an index episode of nose bleeding in hypertensive patients. *Int J Cardiol* 2008 May 20 (Epub ahead of print).
11. Herkner H, Laggner AN, Müllner M, et al. Hypertension in patients presenting with epistaxis. *Ann Emerg Med* 2000;35:126-30.
12. Thong JF, Lo S, Houghton R, Moore-Gillon V. A prospective comparative study to examine the effects of oral diazepam on blood pressure and anxiety levels in patients with acute epistaxis. *J Laryngol Otol* 2007;121:124-9.
13. Herkner H, Havel C, Müllner M, et al. Active epistaxis at ED presentation is associated with arterial hypertension. *Am J Emerg Med* 2002;20:92-5.
14. Krempf GA, Noorily AD. Use of oxymetazoline in the management of epistaxis. *Ann Otol Rhinol Laryngol* 1995;104:704-6.
15. Badran K, Malik TH, Belloso A, Timms MS. Randomized controlled trial comparing Merocel and RapidRhino packing in the management of anterior epistaxis. *Clin Otolaryngol* 2005;30:333-7.
16. Mathiasen RA, Cruz RM. Prospective, randomized, controlled clinical trial of a novel matrix hemostatic sealant in patients with acute anterior epistaxis. *Laryngoscope* 2005;115:899-902.
17. Vidulich RA, Blanda MP, Gerson LW. Posterior epistaxis: clinical features and acute complications. *Ann Emerg Med* 1995;25:592-6.
18. Jacobson JA, Kasworm EM. Toxic shock syndrome after nasal surgery: case reports and analysis of risk factors. *Arch Otolaryngol Head Neck Surg* 1986;112:329-32.
19. Younis RT, Lazar RH. Delayed toxic shock syndrome after functional endonasal sinus surgery. *Arch Otolaryngol Head Neck Surg* 1996;122:83-5.
20. Cullen MM, Tami TA. Comparison of internal maxillary artery ligation versus embolization for refractory posterior epistaxis. *Otolaryngol Head Neck Surg* 1998;118:636-42.
21. Kumar S, Shetty A, Rockey J, Nilssen E. Contemporary surgical treatment of epistaxis: what is the evidence for sphenopalatine artery ligation? *Clin Otolaryngol* 2003;28:360-3.
22. Moshaver A, Harris JR, Liu R, Diamond C, Seikaly H. Early operative intervention versus conventional treatment in epistaxis: randomized prospective trial. *J Otolaryngol* 2004;33:185-8.
23. Srinivasan V, Sherman IW, O'Sullivan G. Surgical management of intractable epistaxis: audit of results. *J Laryngol Otol* 2000;114:697-700.
24. Kubba H, MacAndie C, Botma M, et al. A prospective, single-blind, randomized controlled trial of antiseptic cream for recurrent epistaxis in childhood. *Clin Otolaryngol Allied Sci* 2001;26:465-8.
25. Burton MJ, Dorée CJ. Interventions for recurrent idiopathic epistaxis (nosebleeds) in children. *Cochrane Database Syst Rev* 2004;1:CD004461.

Copyright © 2009 Massachusetts Medical Society.

COLLECTIONS OF ARTICLES ON THE JOURNAL'S WEB SITE

The *Journal's* Web site (NEJM.org) sorts published articles into more than 50 distinct clinical collections, which can be used as convenient entry points to clinical content. In each collection, articles are cited in reverse chronologic order, with the most recent first.