

UCLA Breast Frozen Section Guidelines (March 2019)

Thomas J. Lawton, MD

GENERAL GUIDELINE: Frozen sections on breast specimens, including sentinel lymph nodes, is generally not a good idea and should be reserved for special instances.

Sentinel Lymph node FS:

Breast surgeons may ask for FS on sentinel lymph node(s). Many believe that there should be only one sentinel lymph node (the first lymph node to drain from the breast tumor) but this is not the case. There may be one or more SLNs guided by both blue dye and radioactive colloid. If any one of multiple SLN shows metastatic carcinoma, you can stop additional SLN FS. Surgeons are essentially looking for macrometastasis so that they can perform a complete axillary LN dissection at the same OR setting.

Types of breast cancer LN metastases:

Isolated tumor cells: focus ≤ 0.2 mm or fewer than 200 cells are considered NO(i+)

Micrometastases: focus >0.2 mm - 2 mm are N1mi

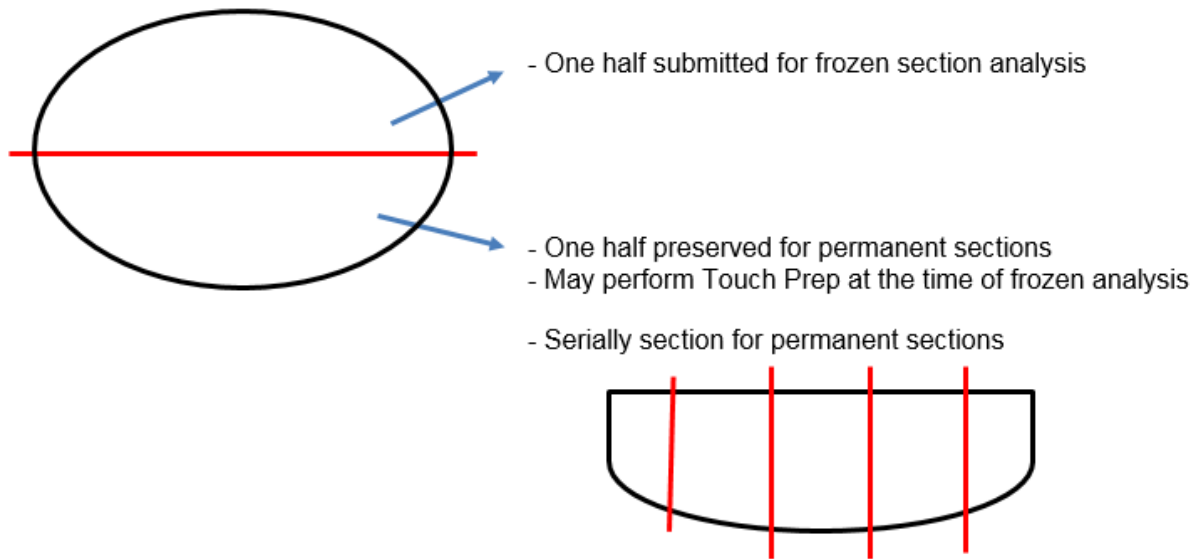
Macrometastases: focus > 2 mm are N1

Procedure:

1. Measure the lymph node in three dimensions.
2. Bisect the lymph node parallel to the long axis.
3. Submit one HALF of the lymph node for frozen section analysis.
 - a. You may do a touch prep on the other half of the LN, which will not be submitted for frozen section. Invasive lobular carcinoma metastatic to SLN is much more difficult than invasive ductal carcinoma. Make sure you do touch prep/smear along with FS.
- If the lymph node is NEGATIVE on frozen section, DO NOT freeze the other half of the lymph node. Some tissue must be preserved for IHC.
4. Serially section the remaining half of the lymph node, which was not submitted for frozen section.
5. If you are not sure, either for micromets or isolated tumor cells, report the uncertainty (surgeons would rather have false negative than false positive result; they can always go back to perform a full axillary LN dissection later). When in doubt, report:
 - No macrometastasis on one representative section; defer to permanent sections and IHC stains OR
 - Atypical cells present but no definite macrometastasis; defer to permanent and IHC stains

UCLA Breast Frozen Section Guidelines (March 2019)

Thomas J. Lawton, MD



Breast Mass and Margin Gross FS:

Don't do it! A FS on a lumpectomy margin is not recommended due to high fat composition leading to technical difficulty particularly with invasive lobular carcinoma. One surgeon in particular wants intra-op "ink and gross." Luckily, these happen infrequently.

Procedure:

1. Ink breast tissue with 6 colors (UCLA standard protocol).
2. Bread-loaf into 3-5 mm intervals.
3. Assess tumor to surgical margin grossly.
4. Report Gross assessment (No FS done).
5. The Attending on the Breast Service is available for consultation.