

Gynecologic Pathology Grossing Guidelines

Specimen Type: FETUS

Note: Please keep in mind that women and families who have a second trimester loss very often read our reports. It is important to use sensitive, respectful, and considerate wording in the report.

- It is appropriate to use “Fetus” rather than “Products of Conception” as the heading for these specimens, even when the fetus may be fragmented.
- For microscopic diagnoses, when applicable, “Fetal tissues” is preferred to “Fetal parts”.
- Unlike medical devices where our gross diagnoses routinely read “As per gross description”, it is appropriate to actually make a gross diagnosis. Please use the **SmartPhrase .JGFETUSDX**. If the fetus is dysmorphic, your diagnosis should read: “Immature dysmorphic fetus with (list the external abnormalities)”.

With regard to gender – after 11 or 12 weeks gestation, it is almost never acceptable to describe an intact fetus as of “indeterminate” gender, or not mention gender at all. You may need to make the extra effort to use a hand lens or dissecting microscope to examine the external genitalia to determine whether there is a fused scrotum or a vulva with an introitus. You cannot rely on the appearance of the penis/clitoris at this gestational age. If you have difficulty determining gender, please consult an attending pathologist (*refer to Appendix 2*).

Procedure:

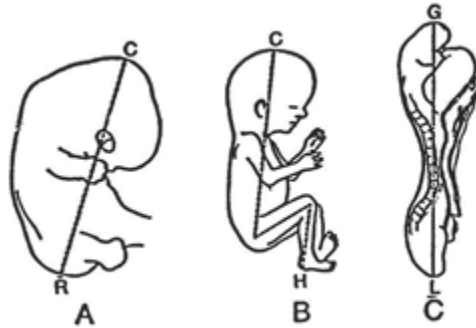
1. Weigh and determine phenotypic gender
 - a. **If fetus weighs more than 500 grams or is older than 20 weeks gestational age or 22 last menstrual weeks’ gestation- case should be processed as fetopsy and needs to be sent to autopsy. Do NOT accession as surgical case.**
2. **If en caul delivery** (fetus attached to placenta in amniotic sac)- photograph intact specimen then rupture the membranes and detach fetus (leaving only a short umbilical stump with the fetus). Weigh the fetus and determine if this a is fetopsy or surgical specimen.
3. Photograph if there are any obvious abnormalities present or if fetal demise was unexpected.
 - (a) If fetus is fragmented and admixed with placental fragments, separate fetal from placental tissues and weight each portion separately. If terminated for anomalies, try to identify tissues suspected of being abnormal to weigh (and possibly photograph)

Gynecologic Pathology Grossing Guidelines

separately. Radiograph skeletal fragments in cases of suspected skeletal dysplasias.

(b) Weigh (with cord and membranes removed) and gross placenta as described in placenta gross examination.

4. **For a pregnancy termination or fetal demise less than 19 6/7 weeks:**
 - A. In all cases, a gross examination should be performed. Photograph and radiograph fetus if received intact. Determine phenotypic gender (ask for assistance if needed).
 - B. If fetus received intact and there is no clinical suspicion of fetal abnormality, and if the gross exam is normal an external examination only will be performed.
 - C. If fetus is received intact and there is clinical suspicion of fetal abnormality, regardless if the patient has signed paperwork asking for fetal remains to be sent to a funeral home for burial, contact Dr. Goldstein and/or the attending on service to see if an internal examination should be performed in addition to a routine external examination.
5. Although not legally required, preferably, an autopsy consent should be obtained for any internal dissection and microscopic examination of an intact fetus less than 20 weeks gestational age. In these instances, the fetus should be accessioned as an autopsy and a complete fetopsy performed. Measure crown-rump, crown-heel length, and estimate fetal age accordingly. Also measure foot length, biparietal diameter, chest circumference, abdominal circumference. If measurements cannot be taken due to fragmented nature of specimen, report this.



Measurements of embryos: A. crown-rump length; B. crown-heel length; C. greatest length.

Gynecologic Pathology Grossing Guidelines

RELATIONS OF AGE, SIZE AND WEIGHT IN THE HUMAN EMBRYO

AGE OF EMBRYO	CROWN-RUMP LENGTH (MM.)	CROWN-HEEL LENGTH (MM.) †	EXTERNAL DIAMETER OF CHORIONIC SAC (MM.)	WEIGHT IN GRAMS	AMOUNT OF INCREASE EACH MONTH WHEN VALUE AT START OF MONTH EQUALS UNITY	
					CR LENGTH	WEIGHT
One week.....	0.1*	0.2			
Two weeks.....	0.2*	3			
Three weeks.....	2.0	10			
Four weeks.....	5.0	20	.02	49.0	40000.00
Five weeks.....	8.0	25			
Six weeks.....	12.0	30			
Seven weeks.....	17.0	19.0	40			
Two lunar months..	25.0	30.0	50	1	3.6	49.00
Three lunar months..	56.0	73.0	14	1.4	13.00
Four lunar months..	112.0	157.0	105	1.0	6.50
Five lunar months..	160.0	239.0	310	0.43	1.95
Six lunar months....	203.0	296.0	640	0.26	1.07
Seven lunar months..	242.0	355.0	1080	0.14	0.69
Eight lunar months..	277.0	409.0	1670	0.14	0.55
Nine lunar months..	313.0	458.0	2400	0.13	0.43
Full term (38 weeks).	350.0	500.0	3300	0.12	0.38

* Total length of embryonic disc. † Recent study: 7 wk. = 23 mm.; 8 wk. = 52 mm.

Gross Template:

Fragmented fetus with placental tissue

MMODAL COMMAND: "INSERT FETAL TISSUE"

It consists of a [weight***] gram, [measure in three dimensions***] cm aggregate of pink-red tissue fragments. Additionally received within the specimen container is a [weight***] gram, [measure in three dimensions***] cm aggregate of fetal tissue. Identifiable fetal tissues include [lung, heart, upper and lower appendages]. The intact foot length measures [***] cm. Representative sections are submitted.

CASSETTE SUMMARY:

[***]1 Representative fetal tissue, placental tissue [umbilical cord if present***]

Intact fetus <19 6/7 gestational age

MMODAL COMMAND: "INSERT INTACT FETUS"

It consists of a [***] gram, intact [male/female, consult attending if not 100% sure on gender***] fetus. The skin appears [color, skin sloughing present/absent***]. The eyelids [are/are not***] fused. The ears [are/are not, see diagram in manual***] low set or abnormally rotated. The philtrum measures [***] cm; the lip and palate are without clefts. There is a [***] cm segment of umbilical cord present which has [***] vessels. There is no omphalocele or abdominal wall defects. The back is free of neural tube defects. The anus is perforate. The extremities are normal without deformity or contractures. Five digits are present on each hand and foot without syndactyly.

Gynecologic Pathology Grossing Guidelines

Crown-rump length: [**] cm

Crown heel length: [**] cm

Foot length: [**] cm

Head circumference: [**] cm

Chest circumference: [**] cm

Abdominal circumference: [**] cm

Nipple to nipple measurement: [**] cm

Inner canthal distance: [**] cm

Outer canthal distance: [**] cm

No gross anomalies are identified. External photographs are obtained. As no request and authorization for internal examination is received, no internal examination is performed and no sections are taken.

Cassette Submission: 1 cassette

- Small embryos - one half or entire embryo or depending on its/their size.
- Fragmented fetuses - representative sections, including lung, kidney, liver, and gonads (if identified)(sections of any abnormalities), placental tissue and cord cross section(s)
- Intact fetuses- gross examination only if < 19 6/7 weeks gestational age
-if there is an umbilical cord (even if attached to the fetus), take a cross section of the cord away from the fetus. Do not disrupt the fetus in doing so.

Gynecologic Pathology Grossing Guidelines

Appendix 2: Development of External Genitalia

