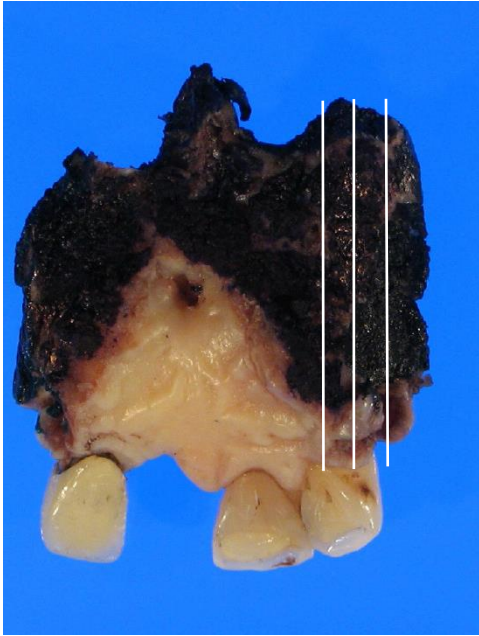


## Head and Neck Pathology Grossing Guidelines

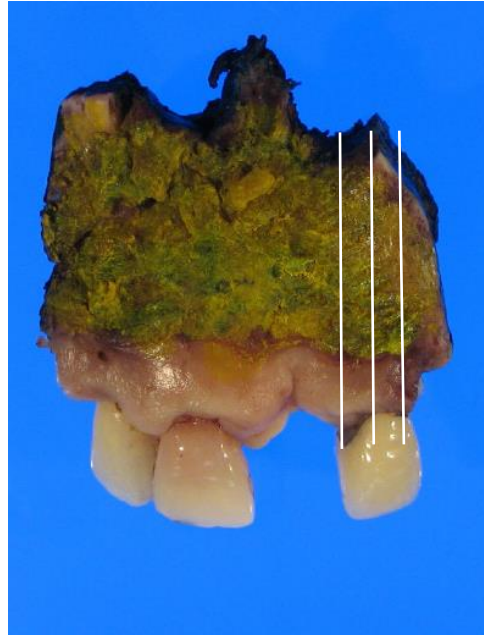
### Do not cut any HN specimens unless you are fully oriented anatomically

- Orient by anatomic structures and attached soft tissue, if any.
- Assess grossing needs on a case by case basis as these specimens vary greatly
- Refer to the OP note to aid in your orientation.
- Always ask for help if unsure of how to proceed.
- Take photographs from multiple angles (medial/lateral, anterior/posterior, superior/inferior).
- Remove any attached teeth (may be easier on fresh vs. fixed tissue).
- Ink soft tissue resection margins.
- Document overall measurements and measurements for other obvious attached tissue (*i.e. paranasal sinuses, periorbital soft tissue, skin, etc.*).
- **For optimal sections which often include bone and soft tissue, you must freeze the specimen in liquid nitrogen** (obtained from TPCL) in order to cut in composite sections. This aids in soft tissue preservation when using the saw (Specimen can be fixed or fresh before placing in liquid nitrogen).
- Describe all abnormalities: size (*staging cutoffs: 2 cm, 4 cm*), location, extent of involvement with attached structures/bone.
- Sample all margins (if grossly close, e.g. 1 cm, submit perpendicular section; otherwise submit a shave of the margins).
- Generally, section perpendicular to the long axis of the specimen, but before you decide the plane of sectioning:
  - Think about why you are sectioning a specimen in a certain manner and consider staging elements. For complex specimens determine origin of tumor and what structures the tumor is extending into /invading, (*i.e. a paranasal sinus SCC lesion may show invasion into the soft tissue surrounding and/or including the eye. Careful assessment to margins is critical at the time of gross exam!*)
- Sections of tumor:
  - Show relationship to all inked margins (usually anterior, posterior, medial, lateral, superior, inferior).
  - Show involvement with bone/attached structures.
- **Always submit sections of mass that have not be decalcified (no bone in a few sections) as decalcifying agents interfere with IHC stains.**
- Diagrams and gross photos are appreciated.

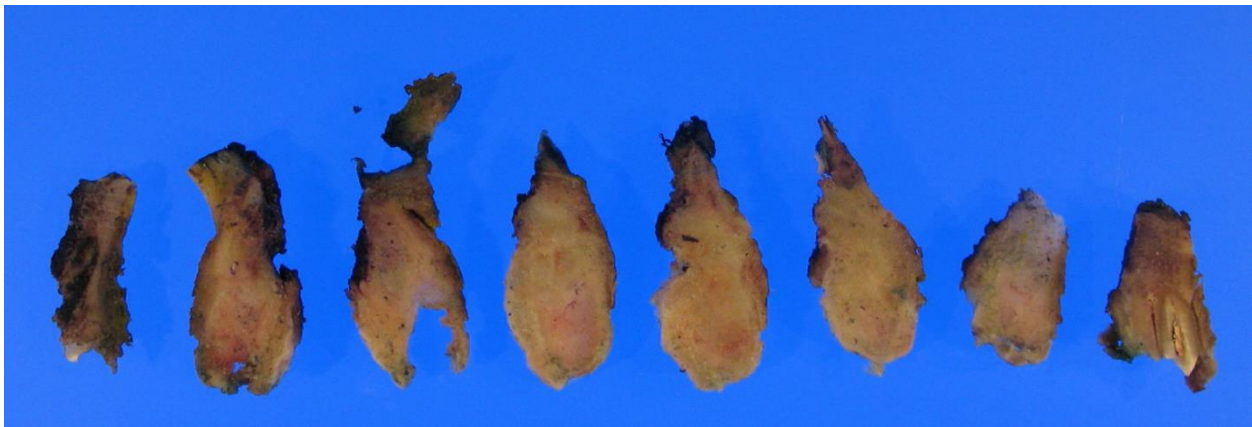
## Head and Neck Pathology Grossing Guidelines



Medial soft tissue margin inked black



Lateral soft tissue margin inked yellow



Specimen is serially sectioned from anterior/midline to posterior (perpendicular to long axis) to show relationship to both inked surfaces.

**Specimen Type:** Maxilla

**Gross Template:**

**MModal Command:** "INSERT MAXILLA"

It consists of a [right/left, total/partial\*\*\*] maxilla [with attached soft tissue\*\*\*] measuring [\*\*\*] cm (anterior-posterior) x [\*\*\*] cm (medial-lateral) x [\*\*\*] cm (superior-inferior). [Describe orientation provided, if any\*\*\*] [Describe number of teeth, absent teeth, and if fillings or other grossly evident dental work is present\*\*\*]

The [mucosa, soft tissue, bone\*\*\*] is remarkable for [describe lesion/ area of ulceration/ area of fibrosis – location, size in two dimensions\*\*\*]. Sectioning reveals a [describe cut surface- soft, calcified, necrotic,

## **Head and Neck Pathology Grossing Guidelines**

*hemorrhagic, mucinous*\*\*\*] cut surface. The lesion [*describe extension into attached structures and if there is bone involvement*\*\*\*] and has a [\*\*\*] cm depth of invasion. The lesion measures [*list measurement to each bone and soft tissue margin present on specimen*\*\*\*] .

The remaining cut surface is [*smooth, pink, unremarkable*\*\*\*]. The uninvolved bone is [*tan-yellow, firm, soft*\*\*\*]. [*Representative sections are submitted/The specimen is entirely submitted*\*\*\*]. Gross photographs are taken.

### **[INK KEY:**

Orange	Anterior
Black	Posterior
Blue	Superior
Green	Inferior
Purple	Medial
Yellow	Lateral-sample/adjust as needed for margins on specimen***]

[*insert cassette summary*\*\*\*]

### **Cassette Submission:**

- Shave of all bone margins
- Soft tissue and mucosal margins/inked surfaces
  - o Perpendicular sections of tumor at closest approach to these margins
- One cassette of mass/soft tissue only for stains per 1 cm of lesion
  - o Include bone involvement or adjacent structures
  - o 1-2 cassettes which do not require decalcification