


Ferumoxytol Contrast Excels in MR Imaging of Congenital Heart Disease

J. Paul Finn, MD
Professor of Radiology
Vice Chair of Innovative Technology
Chief of Diagnostic Cardiovascular Imaging
Department of Radiological Sciences
David Geffen School of Medicine at UCLA



Ferumoxytol is proving to be advantageous as a contrast agent in imaging studies of pediatric and adult congenital heart disease patients. Marketed as Feraheme® to treat anemia in adults with chronic kidney disease, ferumoxytol is used by UCLA radiologists as a contrast agent for a variety of applications, including 4D MUSIC (Multiphase Steady State Imaging with Contrast) imaging in pediatric congenital heart disease patients and for 3D angiography in adult congenital heart disease patients.

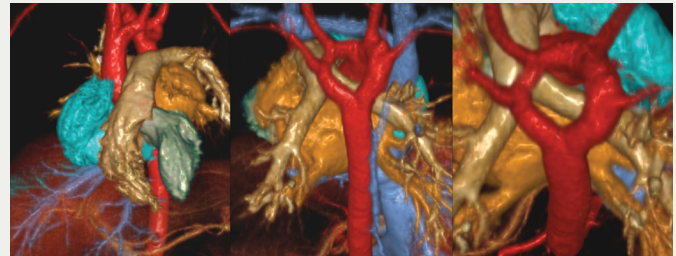
Unlike nearly all gadolinium contrast agents, which leak quickly from blood vessels into the interstitial fluid space, ferumoxytol — a relatively large iron-based molecule — stays in the blood plasma for hours. This eliminates the timing constraints of gadolinium studies, which must be done after the contrast has circulated to the structures being imaged but before too much leaks into the surrounding tissue. It also produces better images — gadolinium images of blood vessels grow less distinct as the contrast leaks from blood vessels and heart structures into adjacent tissue.

“Ferumoxytol is a good choice for imaging any patients with congenital heart disease in whom we want to enhance the blood vessels and the cardiac chambers,” states J. Paul Finn, MD, professor of radiology and chief of Diagnostic Cardiothoracic Imaging at UCLA. UCLA has significant experience using ferumoxytol across a spectrum of patients, having performed approximately 600 cases “with tremendous results,” according to Dr. Finn.

For newborns with congenital heart disease, UCLA has been using ferumoxytol in 4D MUSIC MRI for about five years under the IND (Investigational New Drug) program and an NIH (National Institutes of Health) grant in a collaboration among UCLA radiologists (including physicist Pen Hu, PhD), cardiologists and cardiac surgeons. The combination of ferumoxytol and MUSIC produces, “very detailed 4D images of the heart and blood vessels, even in tiny babies,” says Dr. Finn.

Developed by investigators at UCLA, MUSIC captures a four-dimensional representation of the beating heart, which can be processed after imaging to yield any desired image slices and planes. The entire volume can be captured in about 15 minutes and includes all phases of the heart’s contraction. This is in contrast to conventional MRI, which captures single slices in pre-determined image planes and typically requires 1-1/2 hours for an imaging session. Acquiring conventional MRI images of newborn hearts with congenital defects also requires the constant oversight of a skilled technologist and physician.

The MUSIC images are acquired during uninterrupted ventilation, with no need for the anesthesiologist to suspend ventilation for each imaging pass as with conventional MRI. The high-resolution MUSIC data are supplemented with lower-resolution blood flow information acquired using a related 4D technique.



Color rendered views from a 4D MUSIC MRI study in a baby show a double aortic arch forming a complete vascular ring (red) that caused difficulty swallowing. The patient went on to have successful corrective surgery.

The combination provides a very comprehensive evaluation of heart anatomy and function. “With MUSIC, almost independently of the underlying anatomy — and no matter how complex the abnormality — our technique is the same,” states Dr. Finn.

For adult congenital heart disease patients, ferumoxytol is being used at UCLA to acquire 3D angiographic images throughout the thorax along with detailed functional imaging and blood flow analysis. “Many adult congenital heart disease patients have Fontan shunts, and these can become thrombosed or narrowed,” explains Dr. Finn. “It is very important to evaluate them with imaging.” Ferumoxytol’s resistance to leaking out of the blood vessels eliminates the need for careful timing in imaging studies and produces images whose clarity is undiluted by the leakage of contrast agent into adjacent tissue.

Ferumoxytol is the logical choice for imaging studies in patients with renal impairment, where physicians are seeking to avoid the use of iodinated contrast agents with CT and gadolinium contrast agents with MRI. Ferumoxytol holds enormous promise as an imaging agent due to the unique advantages it can offer.

UCLA has active IRBs for several projects that explore other imaging uses of ferumoxytol. These include combining MRI with non-contrast CT imaging to produce information-rich hybrid images of calcification; bony structures or intravascular wires, catheters or devices. Ferumoxytol is also being explored in imaging renal and liver masses and as a stress agent in cardiac stress testing. “Ferumoxytol holds promise to open up new vistas in the kinds of tests we offer,” states Dr. Finn, “and in the ease and speed with which we can do them. For now, we still regard it as a special test that needs to be done with close patient monitoring, in compliance with FDA guidelines.” 